

PATIENT

Daisy Logan

SPECIES

Canine

BREED

English Bulldog

SEX

FS

AGE

11 years

WEIGHT

52 lbs

INTERPRETED BY

R. McKenzie Daniel,
DVM, DABVP
(Canine and Feline)

IMAGING PERFORMED BY

Sarah Hansen

HOSPITAL NAME

Q Street AH

REFERRING VET

Dr. Bretschneider

INVOICE

13184

DATE

1/26/22

PRESENTING CLINICAL SIGNS

inappropriate urination for last 6 months.

Abnormal PE/Chem/CBC/UA Results: Urinalysis has shown White Blood Cells without any bacteria. Radiographs did not reveal any bladder stones.

ULTRASONOGRAPHIC EXAMINATION OF THE ABDOMEN

Urinary System

The urinary bladder, trigone, cystourethral junction, and visible proximal urethra to a depth of 3.0 cm exhibited normal structure and tone. No evidence of proximal urethral urine retention was present. Anechoic urine was present in the lumen with no uroliths or sediment. The ureteral papillae were normal. The ureters were not visible which is normal. No evidence of inflammatory or neoplastic changes was noted.

The area of the aortic trifurcation was free of pathology.

Normal size and margination were present in the kidneys. A normal 1:3 cortex / medulla ratio and normal corticomedullary definition were maintained. The echogenicity of the cortex was similar to or slightly less than normal liver parenchyma while the medulla echogenicity was hypoechoic to the cortex with no evidence of pyelectasia or signs of pyelonephritis. The left kidney measured 6.0 cm in length. The right kidney measured 5.9 cm in length.

Adrenal Glands

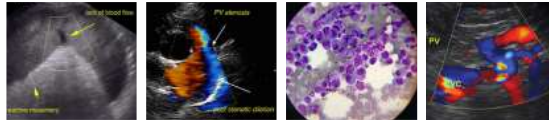
The left adrenal gland was uniform in size and contour with a uniformly hypoechoic parenchyma. The left adrenal gland measured 0.66 cm width at the caudal pole and 0.56 cm width at the cranial pole. The right adrenal gland was uniform in size and contour with a uniformly hypoechoic parenchyma. The right adrenal gland measured 0.46 cm width at the caudal pole.

Spleen

The spleen exhibited a finely textured and homogenous parenchyma which was hyperechoic to the liver and renal cortical parenchyma. The capsule was smooth and regular without apparent expansion. The splenic vasculature at the hilus was normal in volume with no evidence of congestion or thrombosis. Acute to chronic inflammatory, neoplastic, or benign parenchyma changes were not noted.

Liver/ Gallbladder

The liver was subjectively normal in size, structure, and contour. The liver parenchyma was uniform and hypoechoic to the spleen with a mild coarse echotexture. The hepatic and portal vasculature were normal in appearance without signs of congestion. The gallbladder was non-distended in size with thin walls and primarily anechoic luminal content. The cystic and common bile ducts were normal.



PATIENT

Gastrointestinal

Daisy Logan

The stomach presented intact wall layering with a normal wall layer ratio. The lumen of the stomach was empty with no signs of ileus, obstruction, or foreign material.

SPECIES

Canine

The small intestine presented intact wall layering with 1:3 muscularis/mucosa ratio. The lumen of the small intestine was empty with no signs of ileus, obstruction, or foreign material.

BREED

English Bulldog

Normal visible colon wall layers were present with apparent formed feces in lumen.

SEX

FS

Pancreas

The parenchyma of the left limb, body, and right limb of the pancreas presented isoechoic to the adjacent omental fat. A normal curvilinear capsule contour of the pancreas was present. The visible pancreatic duct was normal. No signs of active inflammation or neoplastic disease were evident.

AGE

11 years

Free Abdomen

No overt lymphadenopathy or peritoneal effusion was present.

WEIGHT

52 lbs

ULTRASONOGRAPHIC FINDINGS

Primary Findings

- Sonographically unremarkable abdomen - no evidence of upper or lower urinary tract pathology

INTERPRETED BY

R. McKenzie Daniel,
DVM, DABVP
(Canine and Feline)

INTERPRETATION OF THE FINDINGS & FURTHER RECOMMENDATIONS

An obvious cause of the inappropriate urination was not definitively evident in this study. No evidence of upper or lower urinary tract pathology including no evidence of neoplastic disease, cystitis, calculi, or urethral pathology. Urine C/S on a sterile urine sample is suggested to rule out underlying infection, even without evidence of bacteriuria.

IMAGING PERFORMED BY

Sarah Hansen

HOSPITAL NAME

Q Street AH

REFERRING VET

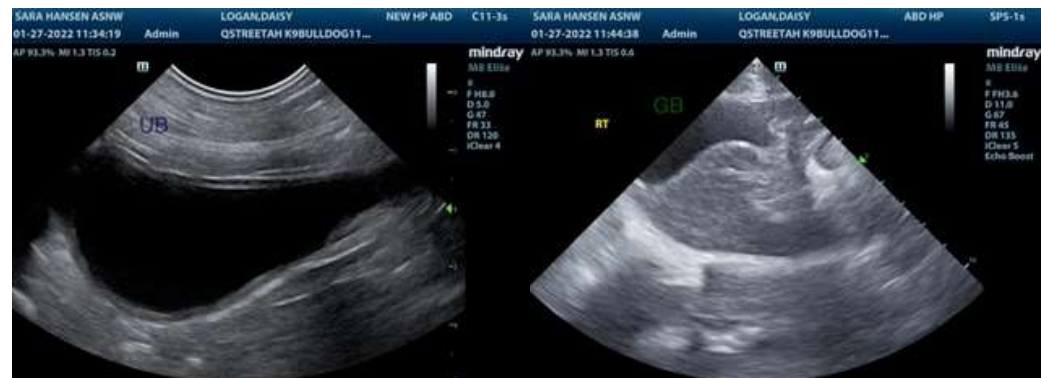Dr. Bretschneider

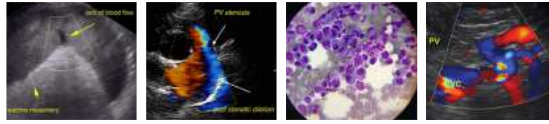
INVOICE

13184

DATE

1/26/22





PATIENT

Daisy Logan

SPECIES

Canine

BREED

English Bulldog

SEX

FS

AGE

11 years

WEIGHT

52 lbs

INTERPRETED BY

R. McKenzie Daniel,
DVM, DABVP
(Canine and Feline)

IMAGING PERFORMED BY

Sarah Hansen

HOSPITAL NAME

Q Street AH

REFERRING VET

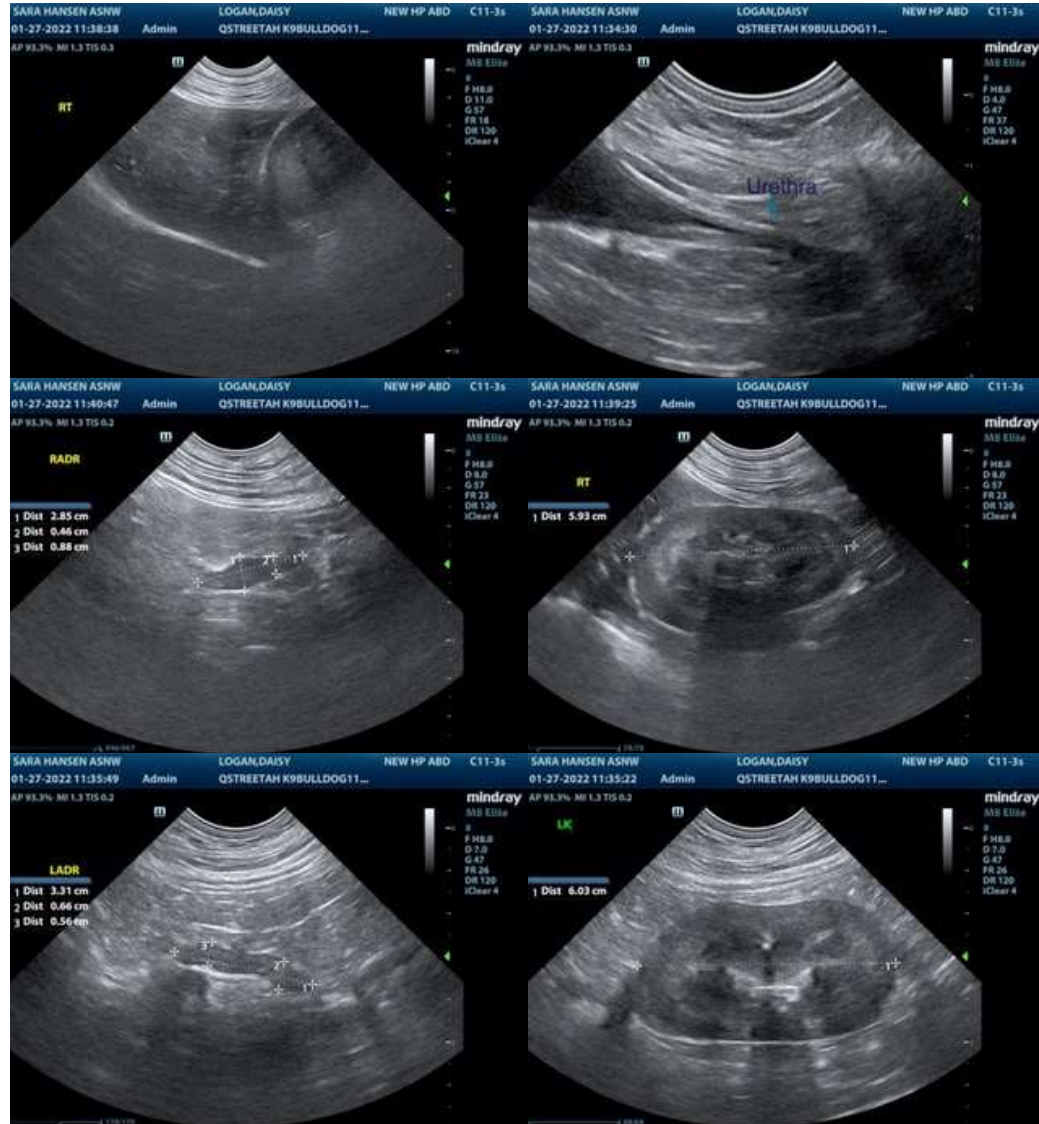
Dr. Bretschneider

INVOICE

13184

DATE

1/26/22



The information and recommendations provided are based on the images presented by the referring veterinarian/sonographer. No evaluation can be communicated regarding pathology that was not visible in the image/video clips provided.

Thank you for this referral. If the clinical or image interpretation does not parallel your findings or if I can be of any further assistance please contact me.

R. McKenzie Daniel, DVM, DABVP (Canine / Feline Practice)
info@SonoPath.com