Pennsylvania Mobile
VETERINARY ULTRASOUND SERVICES

IMAGING PERFORMED BY
PAMobileVet.com 443-794-4700

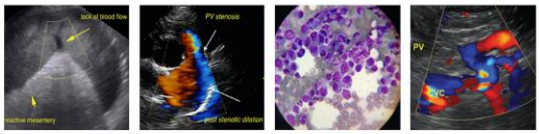

SonoPath
Clinical Sonography & Telecytology
EDUCATIONAL TELECONSULTATION SERVICES™
1-800-838-4268 info@sonopath.com SonoPath.com

PATIENT
Luna Campbell

SPECIES
Canine

BREED
French Bulldog

SEX
FS

AGE
2021

WEIGHT
26.8

INTERPRETED BY
R. McKenzie Daniel, DVM, DABVP (Canine and Feline)

IMAGING PERFORMED BY
Rebekah Jakum, CVT ARDMS/RVT

HOSPITAL NAME
Pocono Peak VC

REFERRING VET
Dr. Coyle

INVOICE
15943

DATE
1/25/23

PRESENTING CLINICAL SIGNS

Mucousy, bloody stool

Medication: Cerenia, Metronidazole, Carafate, Pepcid, i/d

Unremarkable CBC/Chemistry panel, Na/K ratio 41

ULTRASONOGRAPHIC EXAMINATION OF THE ABDOMEN

Urinary System

The urinary bladder, trigone, cystourethral junction, and visible pelvic urethra to a depth of 2.0 cm exhibited normal thickness and tone. Anechoic urine was present in the lumen with no uroliths or sediment. The ureteral papillae were normal. The ureters were not visible which is normal. No evidence of inflammatory or neoplastic changes was noted.

The area of the aortic trifurcation was free of pathology.

Normal size and margination were present in the kidneys. A normal 1:3 cortex / medulla ratio and normal corticomedullary definition were maintained. The echogenicity of the cortex was similar to or slightly less than normal liver parenchyma while the medulla echogenicity was hypoechoic to the cortex with no evidence of pelvic dilation. The left kidney measured 4.6 cm in length. The right kidney measured 5.0 cm in length.

Adrenal Glands

The left adrenal gland was uniform in size and contour with a uniformly hypoechoic parenchyma. The left adrenal gland measured 0.42 cm width at the caudal pole and 0.39 cm width at the cranial pole. The right adrenal gland was uniform in size and contour with a uniformly hypoechoic parenchyma. The right adrenal gland measured 0.57 cm width at the caudal pole and 0.43 cm width at the cranial pole.

Spleen

The spleen exhibited a finely textured and homogenous parenchyma which was hyperechoic to the liver and renal cortical parenchyma. The capsule was smooth and regular without apparent expansion. The splenic vasculature at the hilus was normal in volume with no evidence of congestion or thrombosis. Acute to chronic inflammatory, neoplastic, or benign parenchyma changes were not noted.

Liver/ Gallbladder

The liver was subjectively normal in size, structure, and contour. The liver parenchyma was uniform and hypoechoic to the spleen with a mild coarse echotexture. The hepatic and portal vasculature were normal in appearance without signs of congestion. The gallbladder was non-distended in size with thin walls and primarily anechoic luminal content. The cystic and common bile ducts were normal.

Pennsylvania Mobile
VETERINARY ULTRASOUND SERVICES
IMAGING PERFORMED BY
PAMobileVet.com 443-794-4700

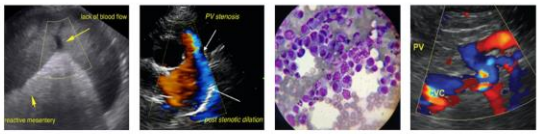

SonoPath
Clinical Sonography & Telecytology
EDUCATIONAL TELECONSULTATION SERVICES™
1-800-838-4268 info@sonopath.com SonoPath.com

PATIENT

Luna Campbell

SPECIES

Canine

BREED

French Bulldog

SEX

FS

AGE

2021

WEIGHT

26.8

INTERPRETED BY

R. McKenzie Daniel, DVM, DABVP (Canine and Feline)

IMAGING PERFORMED BY

Rebekah Jakum, CVT ARDMS/RVT

HOSPITAL NAME

Pocono Peak VC

REFERRING VET

Dr. Coyle

INVOICE

15943

DATE

1/25/23

Gastrointestinal

The stomach presented intact mildly prominent wall layering. The stomach was primarily empty with mild luminal gas. No evidence of retained gastric ingesta, fluid, or evidence of gastric foreign material. The ventral gastric body wall width measured 0.51 cm. The ventral pylorus wall width measured 0.53 cm.

The small intestine presented intact wall layering with 1:3 muscularis/mucosa ratio. The lumen of the small intestine was empty with no signs of mechanical / metabolic ileus, obstruction, or foreign material. The duodenum wall measured 0.37 cm width. The jejunum wall measured 0.37 cm width.

The descending colon exhibited intact mildly prominent wall layering. The descending colon was primarily empty with mild non-formed fecal matter (consistent with patient history).

Pancreas

The parenchyma of the left limb, body, and right limb of the pancreas presented isoechoic to the adjacent omental fat. A normal curvilinear capsule contour of the pancreas was present. The visible pancreatic duct was normal. No signs of active inflammation or neoplastic disease were evident.

Free Abdomen

No omental masses, lymphadenopathy, or evidence of peritoneal effusion were noted.

ULTRASONOGRAPHIC FINDINGS

- Gastroenterocolitis pattern

INTERPRETATION OF THE FINDINGS & FURTHER RECOMMENDATIONS

The mucousy / bloody stool suggests large bowel diarrhea, although potential more generalized inflammatory gastroenterocolonopathy, given recent decreased appetite, is possible. A GI panel to include PLI/TLI/Cobalamin/Folate could be considered to assess for occult intestinal disease or pancreatic inflammation as a contributing factor. Dietary intolerance / food hypersensitivity, emerging Inflammatory bowel disease, low-grade to chronic pancreatitis, occult parasitism, and less likely occult Addison's Disease, are all potentials without evidence of gastroenterocolic foreign body or obstructive pattern.

In addition to current therapy, a hydrolyzed diet trial with potential long term dietary therapy, empirical deworming (i.e., Panacur 50 mg/kg SID x 5 consecutive days with repeat protocol in 3 weeks even if fecal testing is negative), high colony count probiotic +/- empirical cobalamin supplementation and as-needed gastroprotectants with an assessment of clinical response may be considered.

Pennsylvania Mobile
VETERINARY ULTRASOUND SERVICES

IMAGING PERFORMED BY
PAMobileVet.com 443-794-4700

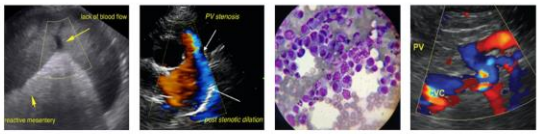

SonoPath
Clinical Sonography & Telecytology
EDUCATIONAL TELECONSULTATION SERVICES™
1-800-838-4268 info@sonopath.com SonoPath.com

PATIENT

Luna Campbell

SPECIES

Canine

BREED

French Bulldog

SEX

FS

AGE

2021

WEIGHT

26.8

INTERPRETED BY

R. McKenzie Daniel, DVM, DABVP (Canine and Feline)

IMAGING PERFORMED BY

Rebekah Jakum, CVT ARDMS/RVT

HOSPITAL NAME

Pocono Peak VC

REFERRING VET

Dr. Coyle

INVOICE

15943

DATE

1/25/23

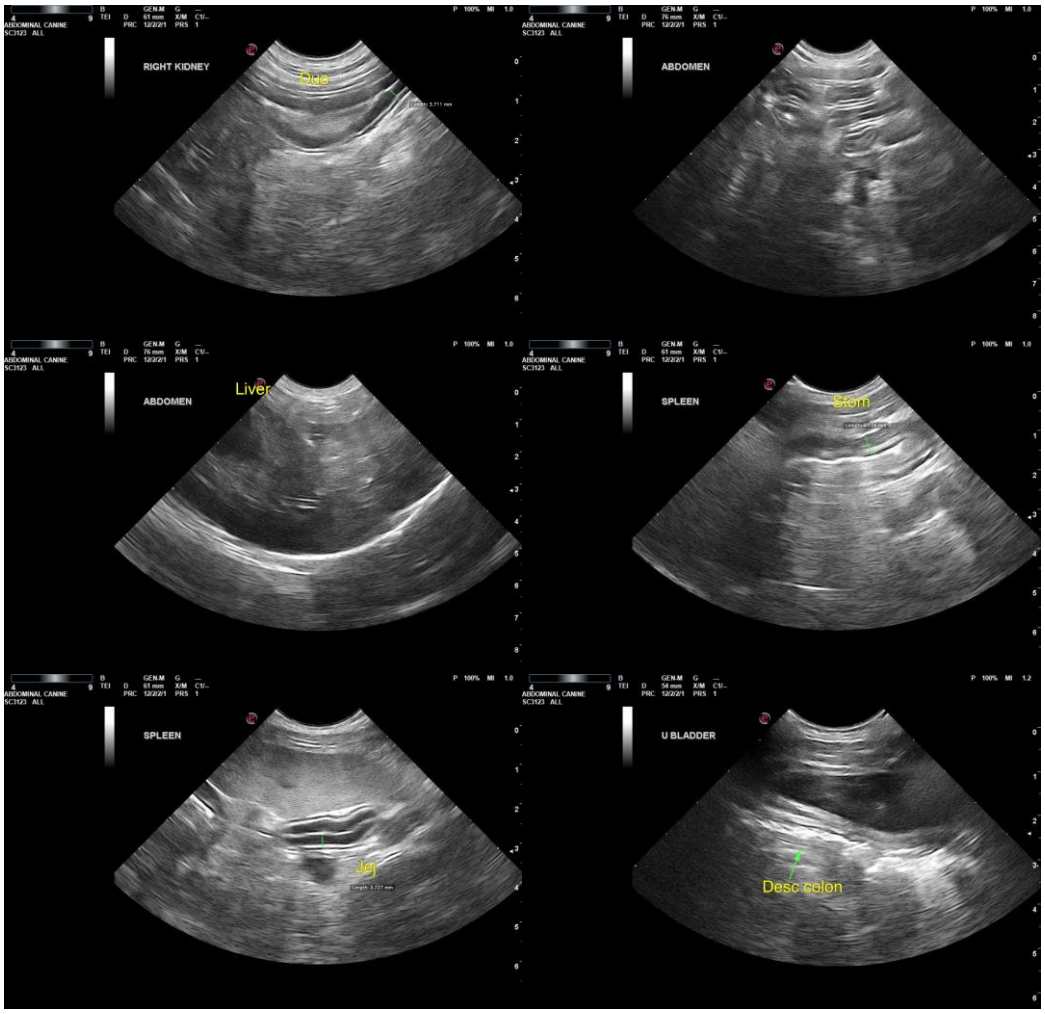

Pennsylvania Mobile
VETERINARY ULTRASOUND SERVICES

IMAGING PERFORMED BY
PAMobileVet.com 443-794-4700

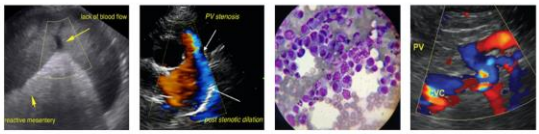

SonoPath
Clinical Sonography & Telecytology
EDUCATIONAL TELECONSULTATION SERVICES™
1-800-838-4268 info@sonopath.com SonoPath.com

PATIENT

Luna Campbell

SPECIES

Canine

BREED

French Bulldog

SEX

FS

AGE

2021

WEIGHT

26.8

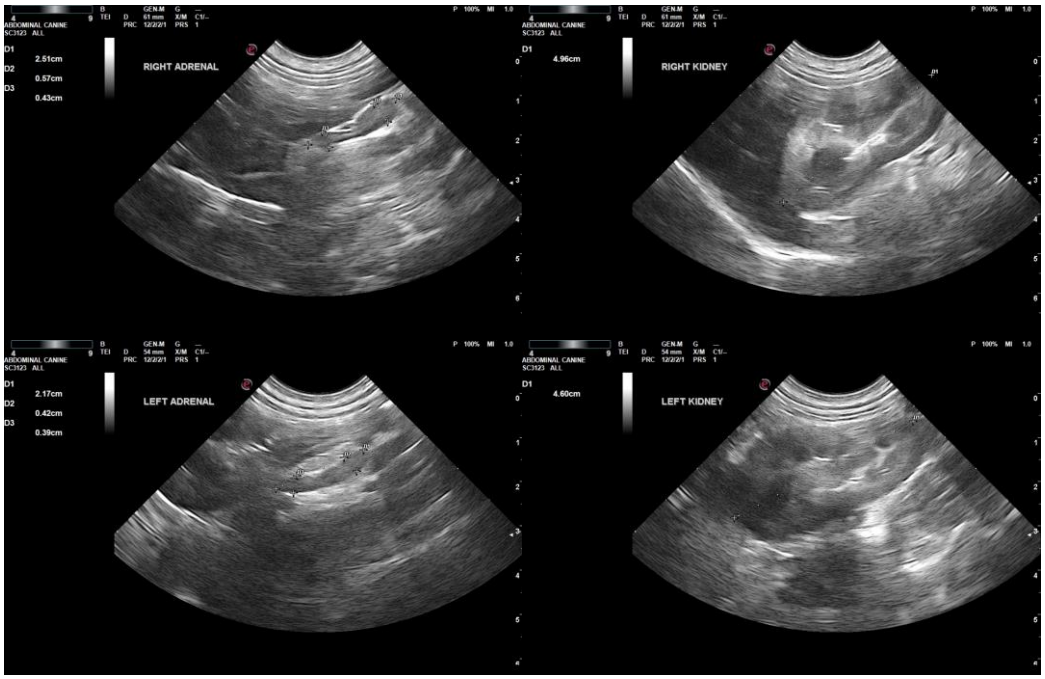

INTERPRETED BY

R. McKenzie Daniel, DVM, DABVP (Canine and Feline)

IMAGING PERFORMED BY

Rebekah Jakum, CVT ARDMS/RVT

HOSPITAL NAME

Pocono Peak VC

REFERRING VET

Dr. Coyle

INVOICE

15943

DATE

1/25/23

The information and recommendations provided are based on the images presented by the referring veterinarian/sonographer. No evaluation can be communicated regarding pathology that was not visible in the image/video clips provided.

Thank you for this referral. If the clinical or image interpretation does not parallel your findings or if I can be of any further assistance, please contact me.

R. McKenzie Daniel, DVM, DABVP (Canine/Feline Practice)
mac.daniel@sonopath.com