



## PATIENT

Sadie Kramer

## SPECIES

Canine

## BREED

Black Mouth Cur

## SEX

Female Spayed

## AGE

8

## WEIGHT

74 lbs

## INTERPRETED BY

R. McKenzie Daniel,  
DVM, DABVP  
(Canine and Feline)

## IMAGING PERFORMED BY

Dr. Michael  
Wassermann

## HOSPITAL NAME

Highlands AH

## REFERRING VET

Dr. Frankenberger

## INVOICE

13122

## DATE

1/24/26

## PRESENTING CLINICAL SIGNS

History:

- Pre-op labs 117. Elevated ALP, ALT, and GGT, Polydipsia for the last few months. Concerned for primary liver disease, infection, cholecystitis, or other GB disease, Scheduled dental on 1/30/26. Was going to be started in clindamycin before dental. Sedated with 4ug/kg Dexdomitor IV and 0.1mg/kg Butorphanol IV. Adequate sedation achieved
- No current medications.

Abnormal PE/Chem/CBC/UA Results: Jan 17, 2026, ALP 1717 U/L, ALT 233 U/L, ALB 4.2, HCT 38.6% calculated, WBC 9k. In house Lepto snap test negative UA via cystocentesis 1/24/26 Protein 500mg/dL, Ph 6.5, URSG 1.010

## ULTRASONOGRAPHIC EXAMINATION OF THE ABDOMEN

### Urinary System

The urinary bladder, trigone, cystourethral junction, and visible pelvic urethra to a depth of 3.0 cm exhibited normal thickness and tone. Anechoic urine was present in the lumen with no uroliths or sediment, mineral or calculi. The ureteral papillae were normal. The ureters were not visible which is normal. No evidence of inflammatory or neoplastic changes were noted.

The area of the aortic trifurcation was free of pathology.

Normal size and margination was present in the kidneys. A normal 1:3 cortex / medulla ratio and normal corticomedullary definition were maintained. The echogenicity of the cortex was similar to or slightly less than normal liver parenchyma while the medulla echogenicity was hypoechoic to the cortex with no evidence of pelvic dilation. The left kidney measured 6.9 cm in length. The right kidney measured 8.1 cm in length.

### Adrenal Glands

The left adrenal gland was uniform in size and contour with a uniformly hypoechoic parenchyma. The left adrenal gland measured 0.60 cm width at the caudal pole. The right adrenal gland was uniform in size and contour with a uniformly hypoechoic parenchyma. The right adrenal gland measured 0.57 cm width at the caudal pole.

### Spleen

The spleen exhibited a finely textured and homogenous parenchyma which was hyperechoic to the liver and renal cortical parenchyma. The capsule was smooth and regular without apparent expansion. The splenic vasculature at the hilus was normal in volume with no evidence of congestion or thrombosis. Acute to chronic inflammatory, neoplastic, or benign parenchyma changes were not noted.

### Liver

The liver was subjectively normal in size, structure, and contour. The liver parenchyma was mildly nonuniform and hypoechoic to the spleen with a moderate coarse echotexture and subjective mild parenchymal remodeling. The hepatic and portal vasculature were normal in appearance without signs of congestion. Ventrocaudal expanding non-homogeneous liver mass with associated asymmetrical



## PATIENT

Sadie Kramer

## SPECIES

Canine

## BREED

Black Mouth Cur

## SEX

Female Spayed

## AGE

8

## WEIGHT

74 lbs

## INTERPRETED BY

R. McKenzie Daniel,  
DVM, DABVP  
(Canine and Feline)

## IMAGING PERFORMED BY

Dr. Michael Wassermann

## HOSPITAL NAME

Highlands AH

## REFERRING VET

Dr. Frankenberger

## INVOICE

13122

## DATE

1/24/26

hepatic capsule distortion was present measuring at least 12.0 cm in diameter, possibly mildly larger. The mass appeared to extend to the approximate level of the gastric axis. The gallbladder was non distended in size with mild, non-organized, echogenic, nonmineralized biliary sludge. The common bbile duct was not visualized.

### ***Gastrointestinal***

The stomach presented intact wall layering with a normal wall layer ratio. The lumen of the stomach was empty with no signs of ileus, obstruction or foreign material.

The small intestine presented intact wall layering with 1:3 muscularis/mucosa ratio. The lumen of the small intestine was empty with no signs of ileus, obstruction or foreign material.

Normal visible colon wall layers were present with apparent formed feces in lumen.

### ***Pancreas***

The parenchyma of the left limb, body and right limb of the pancreas presented isoechoic to the adjacent omental fat. A normal curvilinear capsule contour of the pancreas was present. The visible pancreatic duct was normal. No signs of active inflammation or neoplastic disease was evident.

### ***Free Abdomen***

No overt lymphadenopathy or peritoneal effusion was present.

## **ULTRASONOGRAPHIC FINDINGS**

- Hepatomegaly with liver mass
- Non-organized gallbladder debris
- Normal bilateral adrenal glands

## **INTERPRETATION OF THE FINDINGS & FURTHER RECOMMENDATIONS**

Although sampling is required for further clarification, the liver mass is most consistent with neoplastic criteria, i.e. carcinoma with significant hyperplasia, hepatoma like mass, granulomas, etc. thought less likely. Initial assessment with hepatic mass FNA cytology could be considered assuming normal clotting status. Definitive diagnosis would require biopsy for histopathology. Complete surgical resectability of the mass is considered questionable given the likely involvement of more than one liver lobe. Hepato-supportive medications may prove beneficial.



**PATIENT**

Sadie Kramer

**SPECIES**

Canine

**BREED**

Black Mouth Cur

**SEX**

Female Spayed

**AGE**

8

**WEIGHT**

74 lbs

**INTERPRETED BY**

R. McKenzie Daniel,  
DVM, DABVP  
(Canine and Feline)

**IMAGING PERFORMED BY**

Dr. Michael  
Wassermann

**HOSPITAL NAME**

Highlands AH

**REFERRING VET**

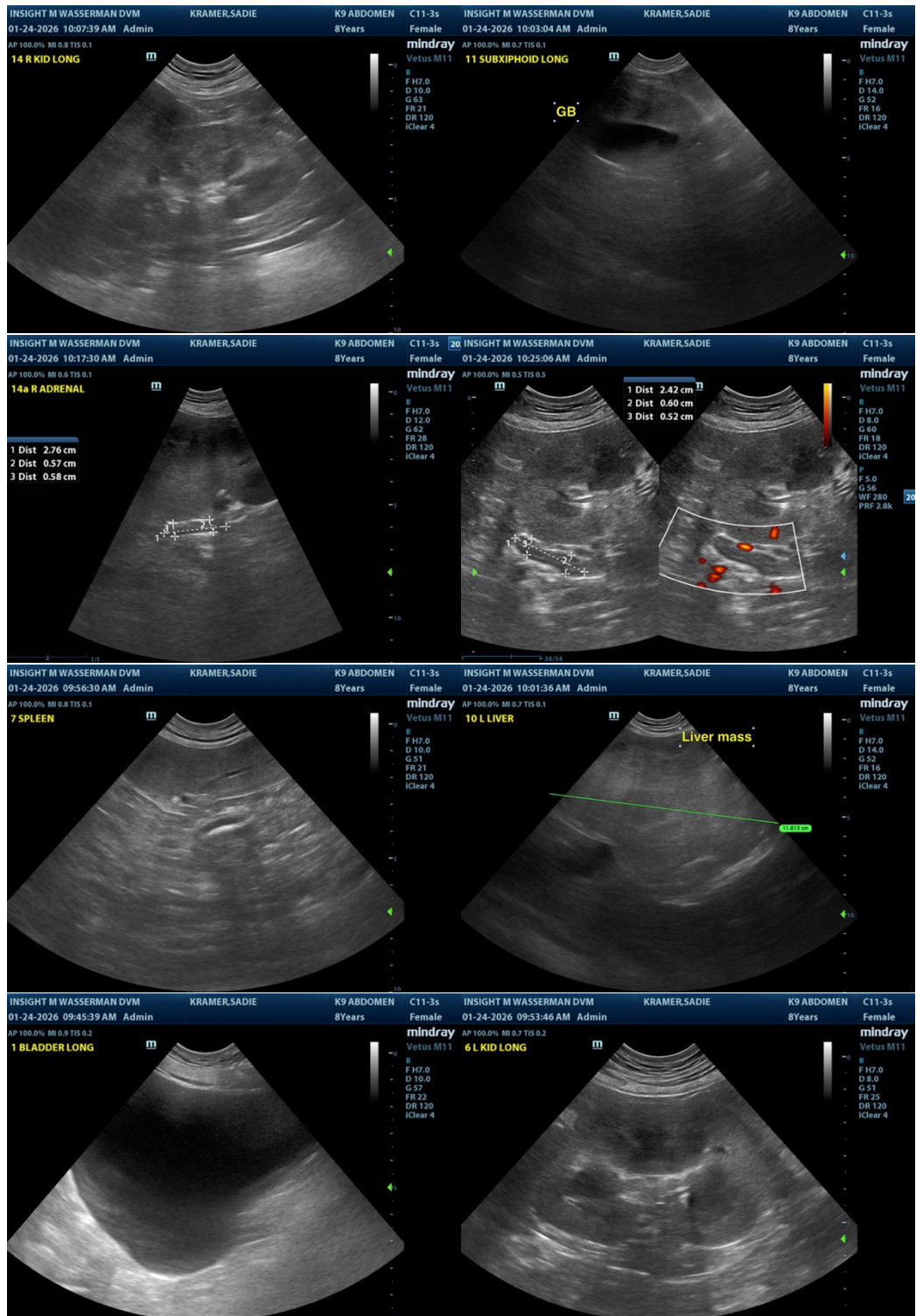
Dr. Frankenberger

**INVOICE**

13122

**DATE**

1/24/26





## PATIENT

Sadie Kramer

## SPECIES

Canine

## BREED

Black Mouth Cur

## SEX

Female Spayed

## AGE

8

## WEIGHT

74 lbs

## INTERPRETED BY

R. McKenzie Daniel,  
DVM, DABVP  
(Canine and Feline)

## IMAGING PERFORMED BY

Dr. Michael  
Wassermann

## HOSPITAL NAME

Highlands AH

## REFERRING VET

Dr. Frankenberger

## INVOICE

13122

## DATE

1/24/26

The information and recommendations provided are based on the images presented by the referring veterinarian/sonographer. No evaluation can be communicated regarding pathology that was not visible in the image/video clips provided.

Thank you for this referral. If the clinical or image interpretation does not parallel your findings or if I can be of any further assistance, please contact me.

R. McKenzie Daniel, DVM, DABVP (Canine / Feline Practice)

[info@sonopath.com](mailto:info@sonopath.com)