



PATIENT

Snickers Haueisen

SPECIES

Feline

BREED

DSH

SEX

Spayed Female

AGE

20 Years

WEIGHT

7.89 kg

INTERPRETED BY

R. McKenzie Daniel,
DVM, DABVP (Canine
/ Feline Practice)

IMAGING PERFORMED BY

Melissa Randolph

HOSPITAL NAME

Shores Veterinary
Emergency Center

REFERRING VET

Dr. Lauren Kiebler

INVOICE

13362

DATE

01/23/26

PRESENTING CLINICAL SIGNS

- Pet was seen at Rossmoyne ER on 1/22 for weight loss and anorexia. (Full BW and rads were done at Rossmoyne). Pet was diagnosed with a renal infection/pyelonephritis. Rossmoyne ER rx medications marboquin SID, and mirtazapine SID. Owner's interested in having cat admitted for IV fluids and hospitalization. Owner worried about dehydration and feels that IV antibiotics would be beneficial.
- concern for nephroliths, urinary tract infection, pyelonephritis, neoplasia, other

Abnormal PE/Chem/CBC/UA Results: PE: mild pain; BCS 8/9 1/22 Rossmoyne ER: CBC- nsf Chem - Glucose 207 H, otherwise nsf T4 - 1.72 Normal EPOC - Glucose 194 H u/a: 1.018 USG, pH 5 L, WBC >50 per hpf, negative glucose rads: Renal calculus present. No obstructive patterns present. 1/23 Shores epoc: BUN 12 L, glucose 211 H

ULTRASONOGRAPHIC EXAMINATION OF THE ABDOMEN

Urinary System

The urinary bladder, trigone, cystourethral junction, and visible pelvic urethra to a depth of 2.0 cm exhibited normal thickness and tone. Anechoic urine was present in the lumen with mild nondependent particulate urine sediment. The ureteral papillae were normal. The ureters were not visible which is normal. No evidence of inflammatory or neoplastic change were noted.

The area of the aortic trifurcation was free of pathology.

Normal size and margination was present in the kidneys. A normal 1:3 cortex / medulla ratio was maintained. The medulla and cortices were uniform in texture with some increased echogenicity and mild to moderate indistinct corticomedullary border demarcation expected for the age of the patient with maintained renal architecture. Focal areas of medullary mineral with no evidence of pyelectasia or left/right retroperitoneal inflammation. The left kidney measured 4.2 cm in length. The right kidney measured 4.0 cm in length.

Adrenal Glands

The left and right adrenal glands were not definitively visualized.

Spleen

The spleen exhibited a finely textured and homogenous parenchyma which was hyperechoic to the liver and renal cortical parenchyma. The capsule was smooth and regular without apparent expansion. The splenic vasculature at the hilus was normal in volume with no evidence of congestion or thrombosis. Acute to chronic inflammatory, neoplastic, or benign parenchyma changes were not noted. The spleen measured 0.80 cm width level of the mid spleen.

Liver & Gallbladder

The liver was subjectively normal in size, structure, and contour. The liver parenchyma was uniform and hypoechoic to the spleen with a mild coarse echotexture. The hepatic and portal vasculature were normal in appearance without signs of congestion.

The gallbladder was non-distended in size with thin walls and primarily anechoic luminal content. The cystic and common bile ducts were normal.



PATIENT

Snickers Haueisen

SPECIES

Feline

BREED

DSH

SEX

Spayed Female

AGE

20 Years

WEIGHT

7.89 kg

INTERPRETED BY

R. McKenzie Daniel,
DVM, DABVP (Canine
/ Feline Practice)

IMAGING PERFORMED BY

Melissa Randolph

HOSPITAL NAME

Shores Veterinary
Emergency Center

REFERRING VET

Dr. Lauren Kiebler

INVOICE

13362

DATE

01/23/26

Gastrointestinal

The stomach presented intact wall layering with a normal wall layer ratio. The lumen of the stomach was empty with no signs of ileus, obstruction or foreign material.

The visualized segments of small intestine exhibited overall intact wall layering and maintained wall layer ratio and nonthickened wall. The jejunum wall measured 0.25 cm width. No evidence of mural pathology at the level of the ileocolic junction measuring 0.38 cm distal ileum wall.

Normal visible colon wall layers were present with apparent formed feces in lumen.

Pancreas

The area of the pancreas was sonographically normal.

Free Abdomen

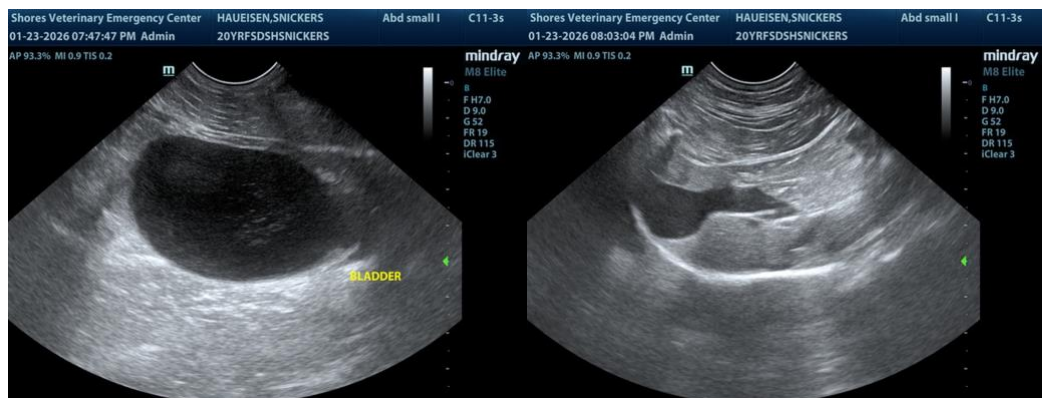
Hypochoic nonhomogenous to irregular enlarged colic lymphadenopathy adjacent to the ileocolic junction with potential for emerging unspecified mass was present measuring approximately 4.0 cm x 3.0 cm with surrounding hyperechoic omentum. No evidence of peritoneal effusion.

ULTRASONOGRAPHIC FINDINGS

- normal urinary bladder with mild urine sediment.
- Bilateral chronic renal changes with mild medullary mineral.
- Overall, structurally normal gastrointestinal tract.
- Moderate to asymmetrically enlarged nonhomogenous hypochoic colic lymphadenopathy versus unspecified mass, surrounding hyperechoic omentum.

INTERPRETATION OF THE FINDINGS & FURTHER RECOMMENDATIONS

No overt evidence of pyelonephritis or urinary tract neoplastic criteria. Correlation with urine culture and sensitivity on sterile urine sample is recommended. FNA cytology of the colic lymphadenopathy versus unspecified mass (assuming normal status and using 25-gauge needle) is warranted for further clarification. No evidence of gastrointestinal obstructive pattern. A GI panel to include PLI, TLI, cobalamin and folate, and if not done, three view chest radiographs to assess for non-obvious or occult disease as a contributing factor.





PATIENT

Snickers Hauelsen

SPECIES

Feline

BREED

DSH

SEX

Spayed Female

AGE

20 Years

WEIGHT

7.89 kg

INTERPRETED BY

R. McKenzie Daniel,
DVM, DABVP (Canine
/ Feline Practice)

**IMAGING
PERFORMED BY**

Melissa Randolph

HOSPITAL NAME

Shores Veterinary
Emergency Center

REFERRING VET

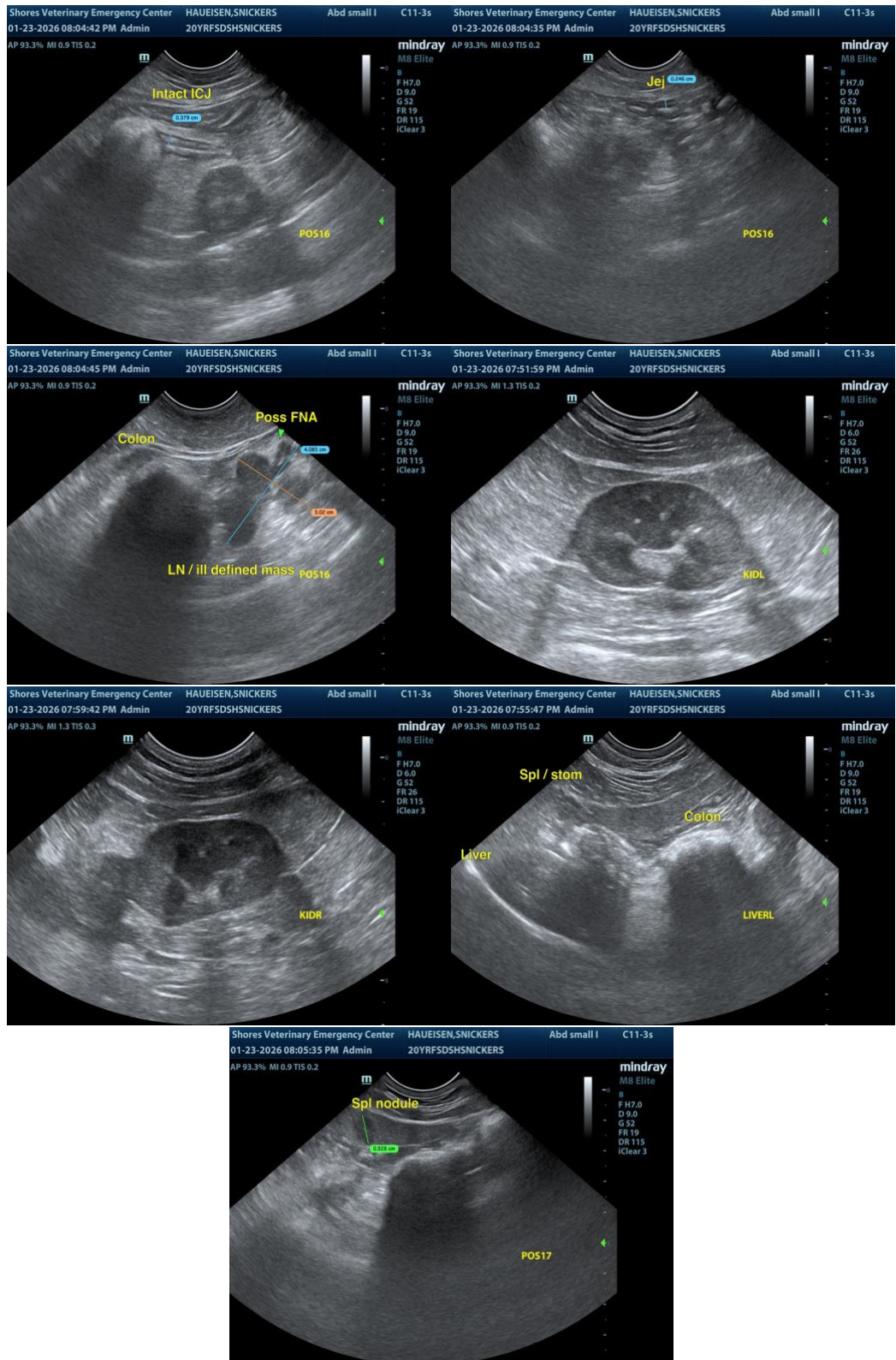
Dr. Lauren Kiebler

INVOICE

13362

DATE

01/23/26





PATIENT

Snickers Haueisen

SPECIES

Feline

BREED

DSH

SEX

Spayed Female

AGE

20 Years

WEIGHT

7.89 kg

INTERPRETED BY

R. McKenzie Daniel,
DVM, DABVP (Canine
/ Feline Practice)

IMAGING PERFORMED BY

Melissa Randolph

HOSPITAL NAME

Shores Veterinary
Emergency Center

REFERRING VET

Dr. Lauren Kiebler

INVOICE

13362

DATE

01/23/26

The information and recommendations provided are based on the images presented by the referring veterinarian/sonographer. No evaluation can be communicated regarding pathology that was not visible in the image/video clips provided.

Thank you for this referral. If the clinical or image interpretation does not parallel your findings or if I can be of any further assistance, please contact me.

R. McKenzie Daniel, DVM, DABVP (Canine / Feline Practice)

info@SonoPath.com