



PATIENT

Carly McCarty

SPECIES

Canine

BREED

Mix

SEX

Spayed Female

AGE

16

WEIGHT

20

INTERPRETED BY

R. McKenzie Daniel,
DVM, DABVP

PRESENTING CLINICAL SIGNS

- Had 2 syncope events Prev bi cav 10/27/25 Current meds Enalapril 2.5mg 1 BID Amlodipine 2.5mg 1 BID

ULTRASONOGRAPHIC EXAMINATION OF THE HEART & ABDOMEN

CANINE CARDIAC PARAMETERS	MR VMAX (m/s)	TR VMAX (m/s)	LA/AO (M-Mode)	LA/AO (Heart Base; Swe)	FS (%)	EF (%)	EPSS (cm)
NORMAL PARAMETER	4.5-5.5	<2.7	1.3	Up to 1.6	28-40	40-100	<0.6
PATIENT	--	2.5	NM	1.8	36	68	0.2
CANINE CARDIAC PARAMETERS	HR (BPM)	AV VMAX (m/s)	PV MAX (m/s)	BODY WEIGHT	LAD LA MAX 4 Chamber	LVIDd Avg; 2D and m-mode short axis (cm)	LVIDs Avg; 2D and m-mode short axis (cm)
NORMAL PARAMETER	50-100	0.7-1.7	0.7-1.6				
PATIENT	NM	1.4	1.9	20	2.6	2.6	--

Cardiac Presentation

The echocardiogram in this patient demonstrated mild increased **left atrial** dimension based on 2 different LA measurement methods. The cranial and caudal **mitral** valve leaflets presented thickening consistent with endocardiosis. Doppler indicated mild to moderate eccentric insufficiency. The **left ventricle** presented increased thicknesses with maintained linear contour and was not dilated nor restricted. The **myocardium** presented normal echogenicity without subjective evidence of significant fibrotic or ischemic disease. **Contractility** of the ventricular walls was adequate and in normal range for this patient evidenced by the fractional shortening measurement and subjective evaluation of the different regions of the myocardium. The **left ventricular outflow** tract demonstrated normal laminar flow and subjective structural integrity. The **right atrium** and auricle revealed normal size, structure and content. No evidence of masses was noted or chamber overload. **Tricuspid** valvular assessment demonstrated mild thickening with mild TR on doppler. The **right ventricle** was of normal size (1/3 diameter of LV), chordae structure, myocardial echogenicity and thickness. **Pulmonic** tract assessment revealed normal valve structure, laminar flow, and diameter (approx.1:1 pa/ao ratio). Normal measured RVOT velocity. Pericardial effusion without overt concurrent pleural effusion was present. An indistinctly visualized yet subjective nonhomogenous mass lesion in the area of the heart base or right atrium was present measuring approximately 3.0 cm in diameter.

Urinary System

The urinary bladder, trigone, cystourethral junction, and visible pelvic urethra to a depth of 3.0 cm exhibited normal thickness and tone. Anechoic urine was present in the lumen with no uroliths or

IMAGING PERFORMED BY

Jenn

HOSPITAL NAME

Rockaway Animal Hospital

REFERRING VET

Dr. Maniar

INVOICE

13326

DATE

01/23/26



PATIENT

Carly McCarty

SPECIES

Canine

BREED

Mix

SEX

Spayed Female

AGE

16

WEIGHT

20

INTERPRETED BY

R. McKenzie Daniel,
DVM, DABVP

IMAGING PERFORMED BY

Jenn

HOSPITAL NAME

Rockaway Animal
Hospital

REFERRING VET

Dr. Maniar

INVOICE

13326

DATE

01/23/26

sediment. The ureteral papillae were normal. The ureters were not visible which is normal. No evidence of inflammatory or neoplastic change were noted.

Normal size and margination was present in the kidneys. A normal 1:3 cortex / medulla ratio was maintained. The medulla and cortices were uniform in texture with some increased echogenicity and moderate loss of corticomedullary symmetry and definition expected for the age of the patient. Mild pyelectasia and mild medullary mineral was visualized bilaterally. The left kidney measured 5.0 cm in length. The right kidney measured 5.5 cm in length.

Adrenal Glands

The bilateral adrenal glands were enlarged in size. Mild parenchyma heterogeneity and mild capsule asymmetry was present without suspicion for overt neoplasia. The left adrenal gland measured 0.94 cm width in the caudal pole. The right adrenal gland measured 1.0 cm width width in the caudal pole.

Spleen

The spleen exhibited primarily finely textured parenchyma which was hyperechoic to the liver and renal cortical parenchyma. Mild generalized parenchyma heterogeneity was present without evidence of nodular changes. The capsule was smooth and regular without apparent expansion. The splenic vasculature at the hilus was normal in volume with no evidence of congestion or thrombosis. The parenchymal heterogeneity is likely consistent with benign changes such as extramedullary hematopoiesis or age-related remodeling with minor potential for inflammatory or neoplastic disease.

Liver & Gallbladder

The liver presented enlarged in size with symmetrical yet swollen contour. The parenchyma exhibited conserved uniform parenchyma with normal echogenicity isoechoic to the spleen and falciform fat. The hepatic vasculature was dilated in appearance, most notable at the level of the hepatic vein / caudal vena cava junction, without evidence of thrombosis.

Transdiaphragmatic view revealed comet tail lung pattern, which is echogenic sound wave interface with microconsolidations within the caudal lung field. The lung field should not be visualized by sonogram unless pathology is present. Chest radiographs are recommended to rule out alveolar/lung disease such as neoplasia, thromboembolic disease, chronic inflammatory disease with microconsolidation.

The gallbladder was non distended in size with mild nonorganized biliary sludge. The cystic duct and common bile ducts were normal without evidence of dilation. No evidence of wall edema.

Gastrointestinal

The stomach presented intact wall layering with a normal wall layer ratio. The lumen of the stomach was empty with no signs of ileus, obstruction or foreign material.

The small intestine presented intact wall layering with 1:3 muscularis/mucosa ratio. The lumen of the small intestine was empty with no signs of ileus, obstruction or foreign material.

Normal visible colon wall layers were present with apparent formed feces in lumen.

Pancreas



PATIENT

Carly McCarty

The parenchyma of the left limb, body and right limb of the pancreas presented isoechoic to the adjacent omental fat. A normal curvilinear capsule contour of the pancreas was present. The visible pancreatic duct was normal. No signs of active inflammation or neoplastic disease was evident.

SPECIES

Canine

Free Abdomen

No visualized significant omental lymphadenopathy was present. Pockets of scant peritoneal effusion were present.

BREED

Mix

ULTRASONOGRAPHIC FINDINGS

SEX

Spayed Female

- Chronic mitral valve disease (mild B2).
- Thickened LV- suggestive of volume contraction/pseudohypertrophy.
- Pericardial effusion with indistinct mass lesion in the area of the heart base/right atrium.
- Mild TV insufficiency- no obvious significant or clinical pulmonary hypertension.
- Congested liver.
- Mild nonorganized gallbladder debris (non-mucocele).
- Normal age-related spleen.
- Chronic renal changes exhibiting pyelectasia.
- Scant peritoneal effusion.

AGE

16

WEIGHT

20

INTERPRETATION OF THE FINDINGS & FURTHER RECOMMENDATIONS

The indistinct heart base to right atrial mass is consistent with neoplastic criteria i.e. favored sarcoma given location with secondary pericardial effusion, cardiac tamponade, and hepatic congestion probable. Inflammatory, infectious, or idiopathic causes of pericardial effusion is thought less likely. No obvious evidence of primary intra-abdominal neoplasia. Ideally, pericardiocentesis with effusion analysis and cytology for further clarification is recommended, however, an unfavorable prognosis is indicated.

INTERPRETED BY

R. McKenzie Daniel, DVM, DABVP

IMAGING PERFORMED BY

Jenn

HOSPITAL NAME

Rockaway Animal Hospital

REFERRING VET

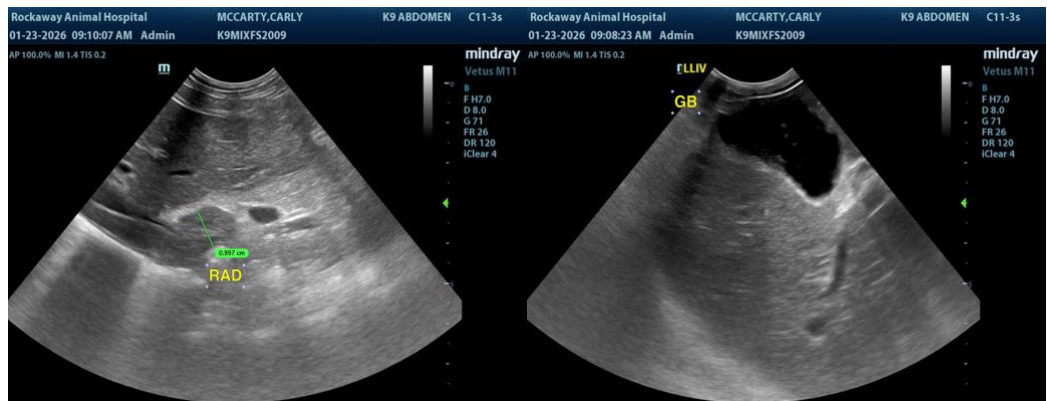Dr. Maniar

INVOICE

13326

DATE

01/23/26





PATIENT

Carly McCarty

SPECIES

Canine

BREED

Mix

SEX

Spayed Female

AGE

16

WEIGHT

20

INTERPRETED BY

R. McKenzie Daniel,
DVM, DABVP

IMAGING PERFORMED BY

Jenn

HOSPITAL NAME

Rockaway Animal
Hospital

REFERRING VET

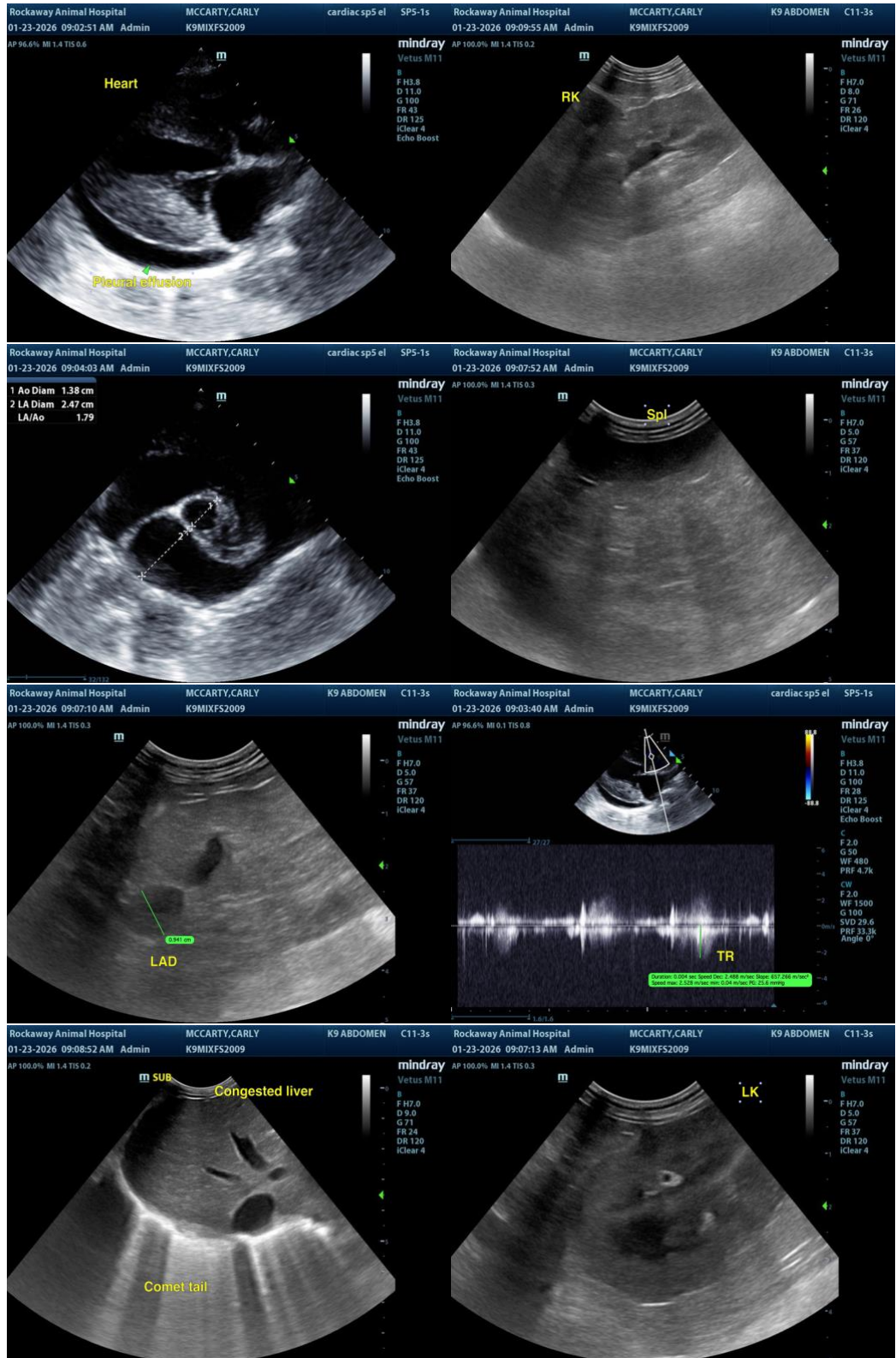
Dr. Maniar

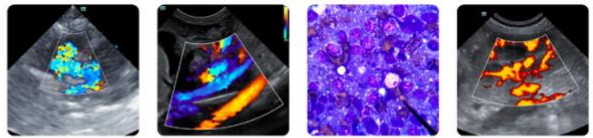
INVOICE

13326

DATE

01/23/26





PATIENT

Carly McCarty

SPECIES

Canine

BREED

Mix

SEX

Spayed Female

AGE

16

WEIGHT

20

INTERPRETED BY

R. McKenzie Daniel,
DVM, DABVP

IMAGING PERFORMED BY

Jenn

HOSPITAL NAME

Rockaway Animal
Hospital

REFERRING VET

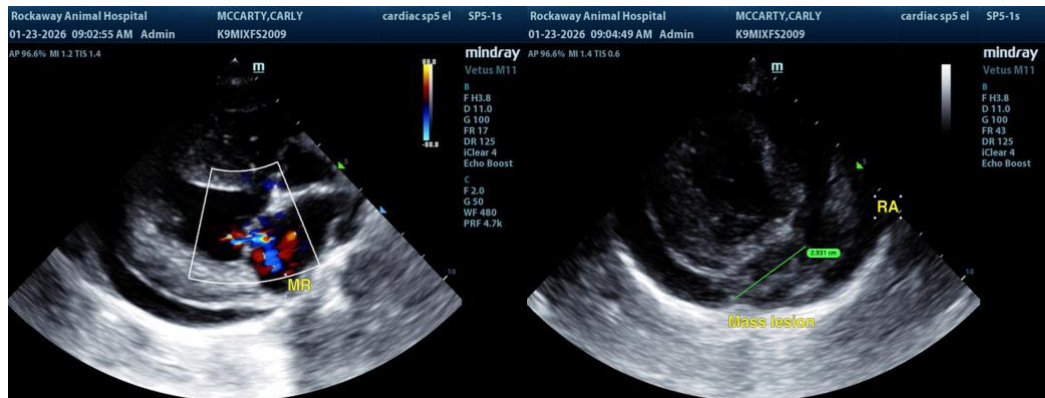
Dr. Maniar

INVOICE

13326

DATE

01/23/26



The information and recommendations provided are based on the images presented by the referring veterinarian/sonographer. No evaluation can be communicated regarding pathology that was not visible in the image/video clips provided.

Thank you for this referral. If the clinical or image interpretation does not parallel your findings or if I can be of any further assistance, please contact me.

R. McKenzie Daniel, DVM, DABVP (Canine / Feline Practice)

info@SonoPath.com