



PATIENT

Ghost Ryan

SPECIES

Canine

BREED

Bichon Frise

SEX

MN

AGE

2yr

WEIGHT

17.7

INTERPRETED BY

R. McKenzie Daniel,
DVM, DABVP
(Canine and Feline)

IMAGING PERFORMED BY

Michelle Mack DVM

HOSPITAL NAME

Northside Veterinary
Clinic

REFERRING VET

Mack E

INVOICE

12742ag

DATE

01/23/2023

PRESENTING CLINICAL SIGNS

Patient got out during the extreme cold weather just before Christmas and gone for 12hours . Patient went to ER clinic and ALT was unable to read and temp was 96.0 at admittance All values are now WNL

Abnormal PE/Chem/CBC/UA Results: ALT was 1800 on 12/29 Today all values WNL

ULTRASONOGRAPHIC EXAMINATION OF THE ABDOMEN

Urinary System

The urinary bladder, trigone, cystourethral junction, and visible pelvic urethra exhibited normal thickness and tone. Anechoic urine was present in the lumen with no uroliths or sediment. The ureteral papillae were normal. The ureters were not visible which is normal. No evidence of inflammatory or neoplastic changes were noted.

Normal size and margination were present in the kidneys. A normal 1:3 cortex / medulla ratio and normal corticomedullary definition were maintained. The echogenicity of the cortex was similar to or slightly less than normal liver parenchyma while the medulla echogenicity was hypoechoic to the cortex with no evidence of pelvic dilation. The left kidney measured 4.3 cm in length. The right kidney measured 4.2 cm in length.

The area of the aortic trifurcation was free of pathology.

Adrenal Glands

The left adrenal gland was uniform in size and contour with a uniformly hypoechoic parenchyma. The left adrenal gland measured 0.45 cm width at the caudal pole. The right adrenal gland was uniform in size and contour with a uniformly hypoechoic parenchyma. The right adrenal gland measured 0.40 cm width at the caudal pole.

Spleen

The spleen exhibited a finely textured and homogenous parenchyma which was hyperechoic to the liver and renal cortical parenchyma. The capsule was smooth and regular without apparent expansion. The splenic vasculature at the hilus was normal in volume with no evidence of congestion or thrombosis. Acute to chronic inflammatory, neoplastic, or benign parenchyma changes were not noted.

Liver/Gallbladder

The liver was subjectively normal in size, structure, and contour. The liver parenchyma was uniform and hypoechoic to the spleen with a mild coarse echotexture. The hepatic and portal vasculature were normal in appearance without signs of congestion. Normal vascular volume. The gallbladder was non-distended in size with thin walls and primarily anechoic luminal content. The cystic and common bile ducts were normal.

Gastrointestinal

The stomach presented intact wall layering with a normal wall layer ratio. The lumen of the stomach was empty with no signs of ileus, obstruction or foreign material.

The small intestine presented intact wall layering with 1:3 muscularis/mucosa ratio. The lumen of the small intestine was empty with no signs of ileus, obstruction or foreign material.

Normal visible colon wall layers were present with apparent formed feces in lumen.



PATIENT

Pancreas

Ghost Ryan

The parenchyma of the left limb, body and right limb of the pancreas presented isoechoic to the adjacent omental fat. A normal curvilinear capsule contour of the pancreas was present. The visible pancreatic duct was normal. No signs of active inflammation or neoplastic disease was evident.

SPECIES

Canine

Free Abdomen

No omental masses, overt lymphadenopathy or peritoneal effusion was present.

BREED

Bichon Frise

ULTRASONOGRAPHIC FINDINGS

- Sonographically normal abdomen

SEX

MN

INTERPRETATION OF THE FINDINGS & FURTHER RECOMMENDATIONS

Overall, no overt evidence of significant abdominal visceral pathology including no evidence of structural hepatic pathology or vascular abnormalities. Resolved acute hepatopathy is likely. Normal hepatic volume and functionality given normal reported ALB, GLU, BUN and CHOL.

AGE

2yr

WEIGHT

17.7

INTERPRETED BY

R. McKenzie Daniel,
DVM, DABVP
(Canine and Feline)

IMAGING PERFORMED BY

Michelle Mack DVM

HOSPITAL NAME

Northside Veterinary
Clinic

REFERRING VET

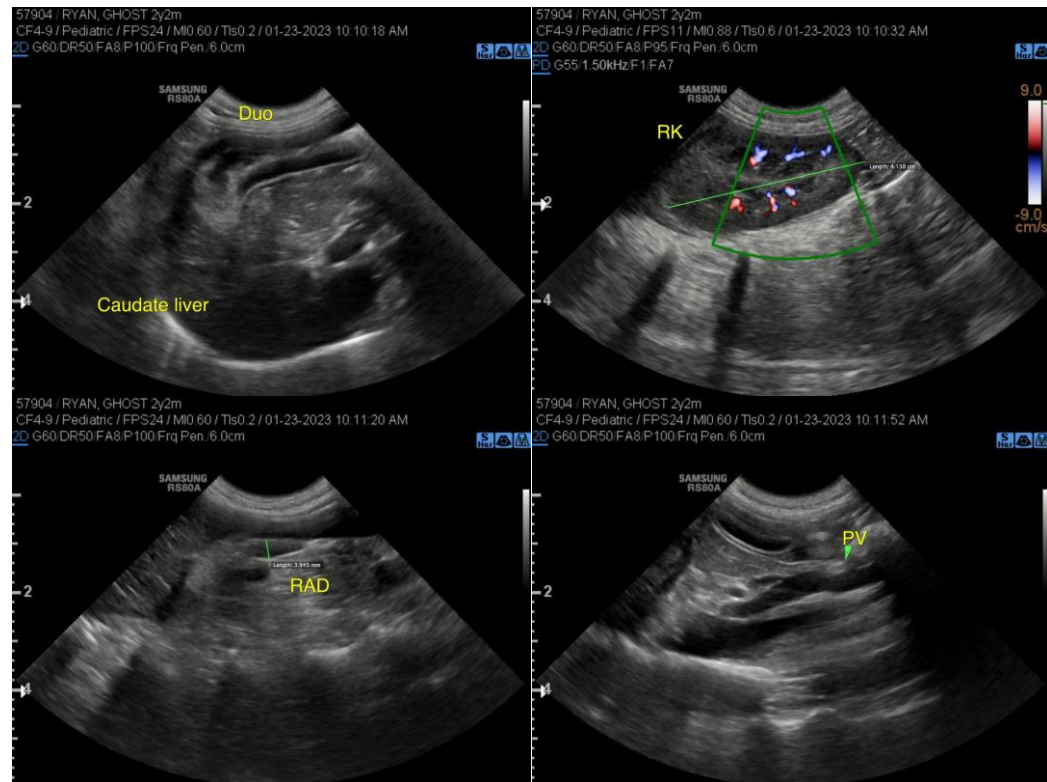
Mack E

INVOICE

12742ag

DATE

01/23/2023





PATIENT

Ghost Ryan

SPECIES

Canine

BREED

Bichon Frise

SEX

MN

AGE

2yr

WEIGHT

17.7

INTERPRETED BY

R. McKenzie Daniel,
DVM, DABVP
(Canine and Feline)

IMAGING PERFORMED BY

Michelle Mack DVM

HOSPITAL NAME

Northside Veterinary
Clinic

REFERRING VET

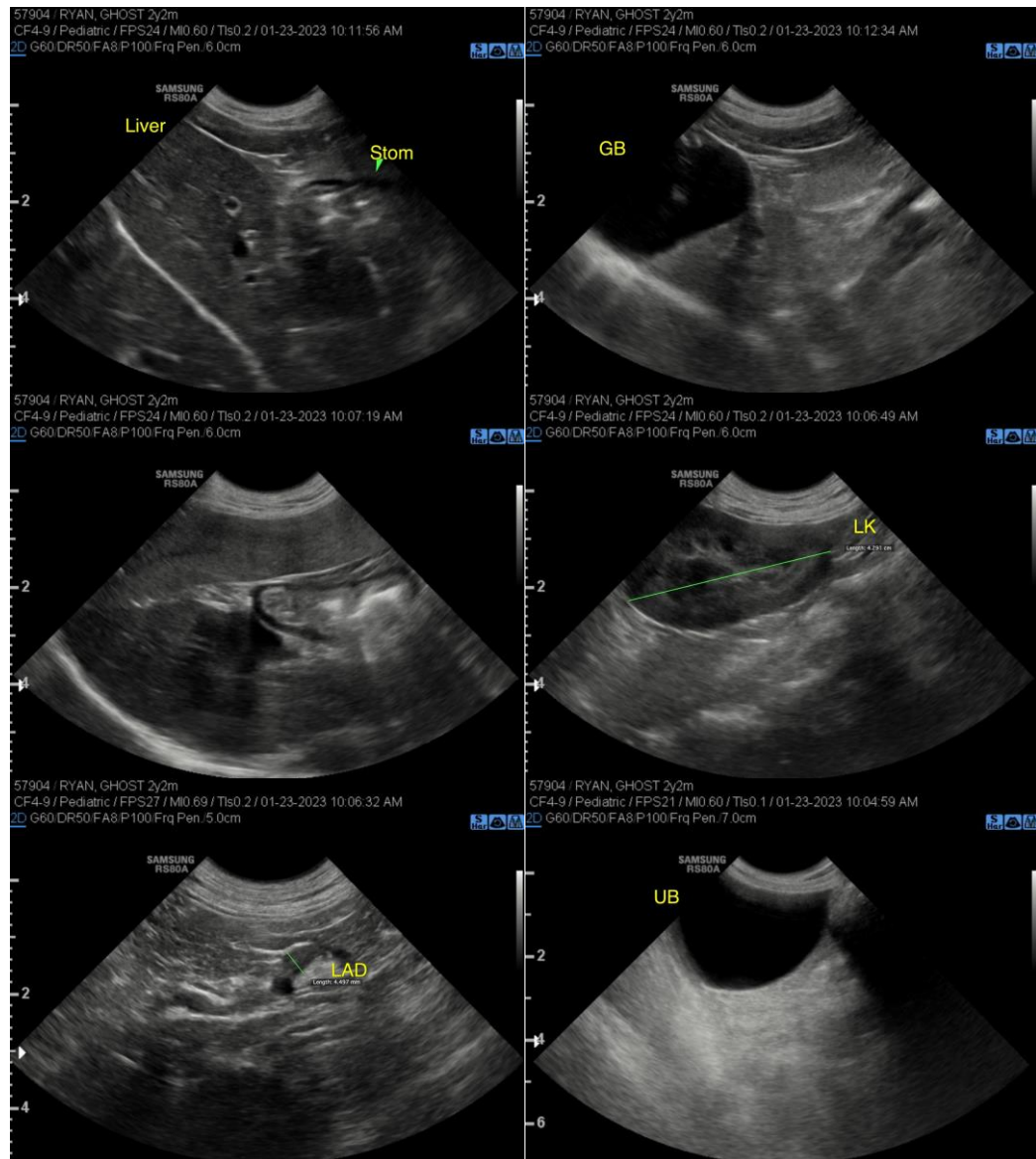
Mack E

INVOICE

12742ag

DATE

01/23/2023



The information and recommendations provided are based on the images presented by the referring veterinarian/sonographer. No evaluation can be communicated regarding pathology that was not visible in the image/video clips provided.

Thank you for this referral. If the clinical or image interpretation does not parallel your findings or if I can be of any further assistance, please contact me.

R. McKenzie Daniel, DVM, DABVP (Canine/Feline Practice)
mac.daniel@sonopath.com