



**PATIENT**

Freddy Voightman

**SPECIES**

Canine

**BREED**

Mix

**SEX**

Neutered Male

**AGE**

11

**WEIGHT**

20

**INTERPRETED BY**

R. McKenzie Daniel,  
DVM, DABVP

**PRESENTING CLINICAL SIGNS**

- Foul odor coming from mouth, swelling on neck

Abnormal PE/Chem/CBC/UA Results: WNL

**ULTRASONOGRAPHIC EXAMINATION OF THE HEART**

CANINE CARDIAC PARAMETERS	MR VMAX (m/s)	TR VMAX (m/s)	LA/AO (M-Mode)	LA/AO (Heart Base; Swe)	FS (%)	EF (%)	EPSS (cm)
NORMAL PARAMETER	4.5-5.5	<2.7	1.3	Up to 1.6	28-40	40-100	<0.6
PATIENT	--	--	NM	1.1	48	82	0.1
CANINE CARDIAC PARAMETERS	HR (BPM)	AV VMAX (m/s)	PV MAX (m/s)	BODY WEIGHT	LAD LA MAX 4 Chamber	LVIDd Avg; 2D and m-mode short axis (cm)	LVIDs Avg; 2D and m-mode short axis (cm)
NORMAL PARAMETER	50-100	0.7-1.7	0.7-1.6				
PATIENT	NM	1.0	0.9	20.0	2.6	2.5	--

**Cardiac Presentation**

The echocardiogram in this patient demonstrated normal **left atrial** size dimension on 2 different LA measurement methods. Chamber volumes and echogenicity were normal. The cranial and caudal **mitral** valve leaflets presented mild thickening consistent with mild endocardiosis. No evidence of valvular prolapse. Doppler revealed minor eccentric insufficiency. The **left ventricle** presented thicknesses with linear contour and was not dilated nor restricted. The **myocardium** presented normal echogenicity without subjective evidence of significant fibrotic or ischemic disease. **Contractility** of the ventricular walls was adequate and in normal range for this patient evidenced by the fractional shortening measurement and subjective evaluation of the different regions of the myocardium. The **left ventricular outflow** tract demonstrated normal laminar flow and subjective structural integrity. The **right atrium** and auricle revealed normal size, structure and content. No evidence of masses was noted or chamber overload. **Tricuspid** valvular assessment demonstrated adequate linear morphology. The **right ventricle** was of normal size (1/3 diameter of LV), chordae structure, myocardial echogenicity and thickness. **Pulmonic** tract assessment revealed normal valve structure, laminar flow, and diameter (approx.1:1 pa/ao ratio). No visible **pericardial** or free pleura fluid was noted. No echographically detectable evidence of cardiac / pericardial tumors was visible.

**ULTRASONOGRAPHIC FINDINGS**

- Normal cardiac structure/function with minor mitral valve insufficiency (B1).

01/22/26

**INVOICE**

13299

**DATE**

**IMAGING PERFORMED BY**

Jenn

**HOSPITAL NAME**

Rockaway Animal Hospital

**REFERRING VET**

Dr. Maniar



**PATIENT**

Freddy Voightman

**SPECIES**

Canine

**BREED**

Mix

**SEX**

Neutered Male

**AGE**

11

**WEIGHT**

20

**INTERPRETED BY**

R. McKenzie Daniel,  
DVM, DABVP

**IMAGING PERFORMED BY**

Jenn

**HOSPITAL NAME**

Rockaway Animal  
Hospital

**REFERRING VET**

Dr. Maniar

**INVOICE**

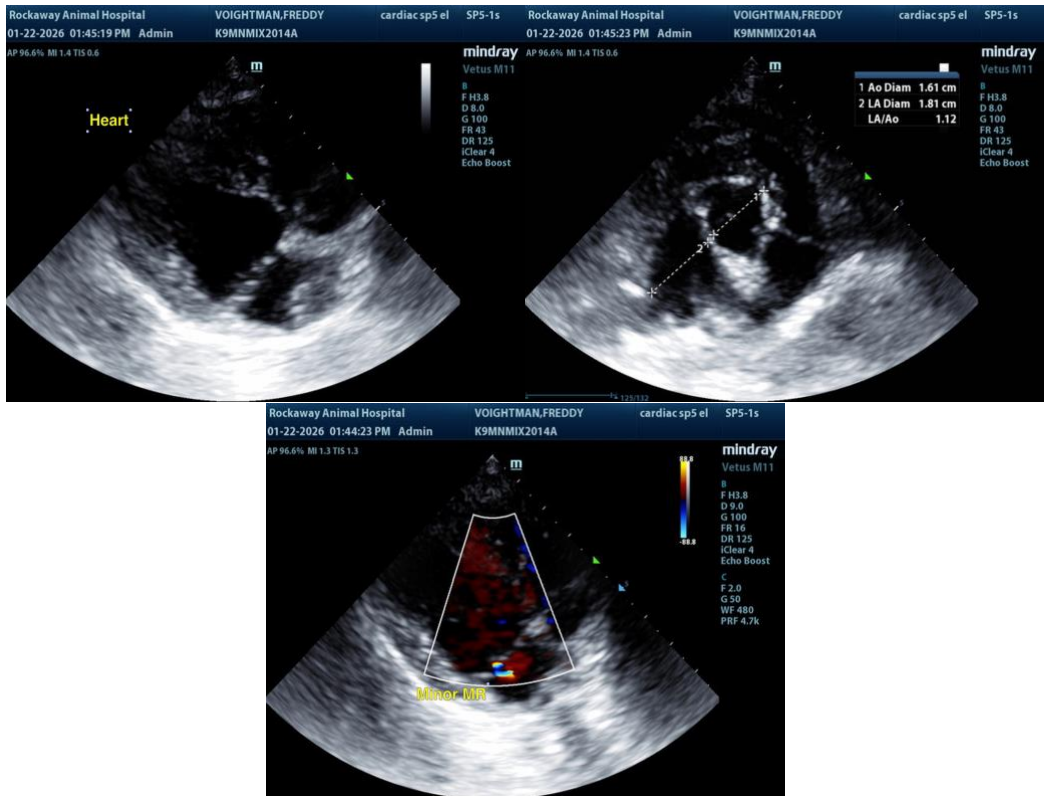
13299

**DATE**

01/22/26

**INTERPRETATION OF THE FINDINGS & FURTHER RECOMMENDATIONS**

The overall normal cardiac structure/function and lack of LA enlargement indicate the current and future risk of complication is low. No indication for cardiac medications. No anesthetic contraindications. Recheck echo is suggested in 8 to 12 months or sooner if clinically indicated. Suggested anesthetic protocol may include opioid or Benzodiazepine pre-med, induction with Propofol or Alfaxalone, and appropriate gas anesthesia with avoidance of alpha 2 agonists.



The information and recommendations provided are based on the images presented by the referring veterinarian/sonographer. No evaluation can be communicated regarding pathology that was not visible in the image/video clips provided.

Thank you for this referral. If the clinical or image interpretation does not parallel your findings or if I can be of any further assistance, please contact me.

R. McKenzie Daniel, DVM, DABVP (Canine / Feline Practice)

[info@SonoPath.com](mailto:info@SonoPath.com)