

PATIENT

Nuttah Tontcheva

SPECIES

Canine

BREED

Terrier X

SEX

FS

AGE

8 years

WEIGHT

11.3 kg

INTERPRETED BY

R. McKenzie Daniel,
DVM, DABVP
(Canine and Feline)

IMAGING PERFORMED BY

Dr. Sarah
Barthelemy

HOSPITAL NAME

Southwood
Veterinary Hospital

REFERRING VET

Dr. Harris

INVOICE

10570

DATE

1/21/26

PRESENTING CLINICAL SIGNS

History:

- Pollakiuria and hematuria
- Nasal and maxillary cancer - palliative

Abnormal PE/Chem/CBC/UA Results: Hematuria

ULTRASONOGRAPHIC EXAMINATION OF THE ABDOMEN

Urinary System

The urinary bladder, trigone, cystourethral junction, and visible pelvic urethra to a depth of 3.0 cm exhibited normal thickness and tone. Anechoic urine was present in the lumen with no evidence of urine or lumen sediment, mineral, or calculi. The ureteral papillae were normal. The ureters were not visible which is normal. No evidence of inflammatory or neoplastic changes was noted.

No evidence of pathology was noted in the area of the uterine remnant.

No evidence of pathology in the area of the aortic trifurcation.

Normal size and margination were present in the kidneys. A normal 1:3 cortex / medulla ratio and normal corticomedullary definition were maintained. The echogenicity of the cortex was similar to or slightly less than normal liver parenchyma while the medulla echogenicity was hypoechoic to the cortex with no evidence of pelvic dilation. The left kidney measured 5.0 cm in length. The right kidney measured 5.2 cm in length. No evidence of pyelectasia was noted in either kidney.

Adrenal Glands

The left adrenal gland was uniform in size and contour with a uniformly hypoechoic parenchyma. The left adrenal gland measured 0.53 cm width at the caudal pole. The right adrenal gland was uniform in size and contour with a uniformly hypoechoic parenchyma. The right adrenal gland measured 0.54 cm width at the caudal pole.

Spleen

The spleen exhibited a finely textured and homogenous parenchyma which was hyperechoic to the liver and renal cortical parenchyma. The capsule was smooth and regular without apparent expansion. The splenic vasculature at the hilus was normal in volume with no evidence of congestion or thrombosis. Acute to chronic inflammatory, neoplastic, or benign parenchyma changes were not noted.

Liver/ Gallbladder

The liver was subjectively normal in size, structure, and contour. The liver parenchyma was uniform and hypoechoic to the spleen with a mild coarse echotexture. The hepatic and portal vasculature were



PATIENT

Nuttah Tontcheva

SPECIES

Canine

BREED

Terrier X

SEX

FS

AGE

8 years

WEIGHT

11.3 kg

INTERPRETED BY

R. McKenzie Daniel,
DVM, DABVP
(Canine and Feline)

IMAGING PERFORMED BY

Dr. Sarah
Barthelemy

HOSPITAL NAME

Southwood
Veterinary Hospital

REFERRING VET

Dr. Harris

INVOICE

10570

DATE

1/21/26

normal in appearance without signs of congestion. The gallbladder was non-distended in size containing primarily anechoic content with moderate, variably congealed yet nonorganized gallbladder debris. The cystic and common bile ducts were normal.

Gastrointestinal

The stomach presented intact wall layering with a normal wall layer ratio. The lumen of the stomach contained mild, nonshadowing ingesta, consistent with food echogenicity without signs of obstruction or foreign material.

The small intestine presented intact wall layering with 1:3 muscularis/mucosa ratio. The lumen of the small intestine was empty with no signs of ileus, obstruction, or foreign material.

Normal visible colon wall layers were present with apparent formed feces in lumen.

Pancreas

The parenchyma of the left limb, body, and right limb of the pancreas presented isoechoic to the adjacent omental fat. A normal curvilinear capsule contour of the pancreas was present. The visible pancreatic duct was normal. No signs of active inflammation or neoplastic disease were evident.

Free Abdomen

No overt lymphadenopathy or peritoneal effusion was present.

ULTRASONOGRAPHIC FINDINGS

- Normal urinary bladder and visible proximal urethra
- Normal area of uterine remnant
- Normal bilateral kidneys
- Congealed nonorganized gallbladder debris - not consistent with mature mucocele

INTERPRETATION OF THE FINDINGS & FURTHER RECOMMENDATIONS

A definitive cause of the patient's clinical signs was not obvious without evidence of upper or lower urinary tract or uterine remnant pathology. Urine C/S on a sterile urine sample is recommended if not done. Ursodiol trial is recommended if there is evidence of cholestasis. Sonographic monitoring of the urinary tract and gallbladder is indicated if there are continued or progressive lower urinary tract signs or cholestasis.



PATIENT

Nuttah Tontcheva

SPECIES

Canine

BREED

Terrier X

SEX

FS

AGE

8 years

WEIGHT

11.3 kg

INTERPRETED BY

R. McKenzie Daniel,
DVM, DABVP
(Canine and Feline)

IMAGING PERFORMED BY

Dr. Sarah
Barthelemy

HOSPITAL NAME

Southwood
Veterinary Hospital

REFERRING VET

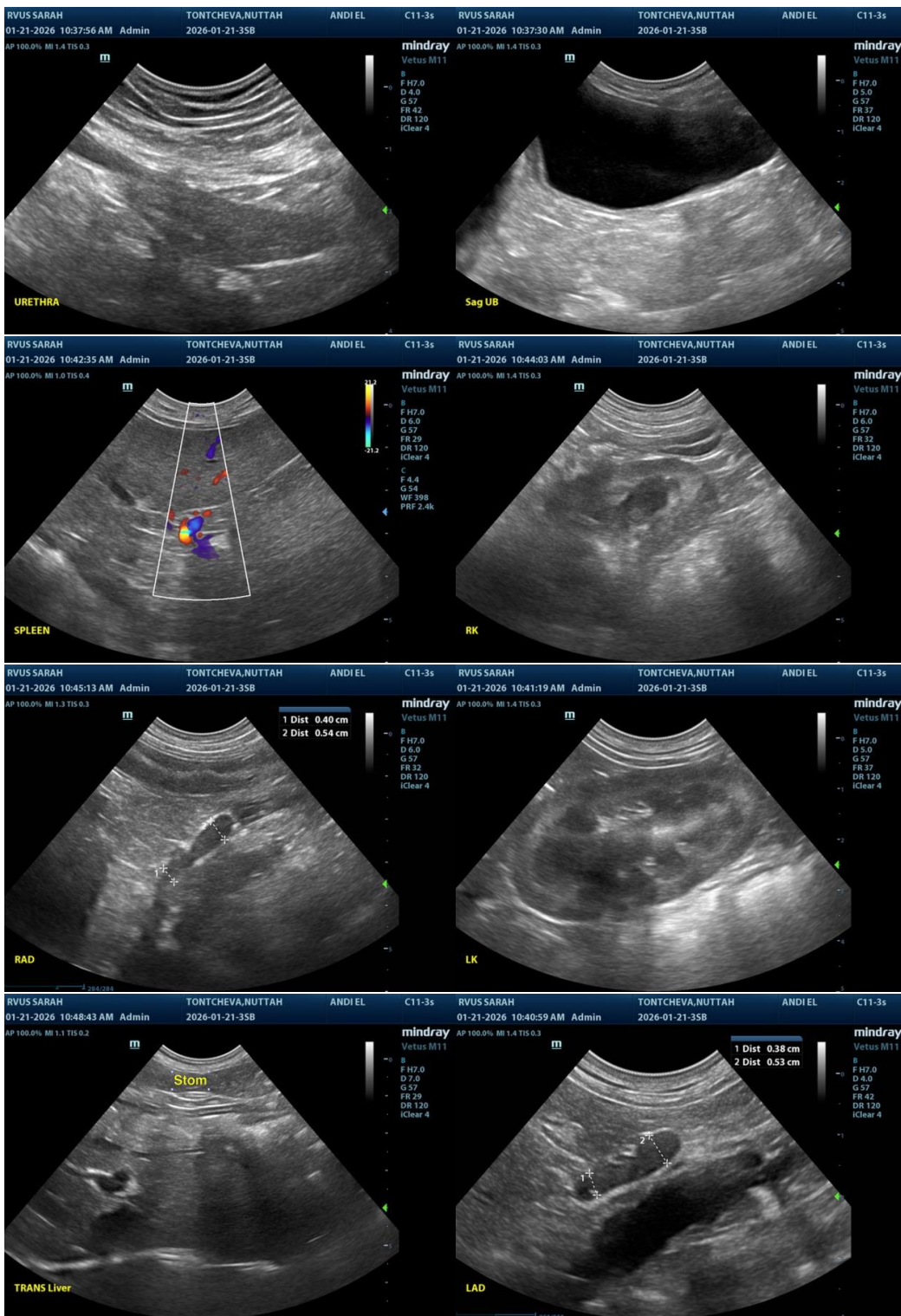
Dr. Harris

INVOICE

10570

DATE

1/21/26





PATIENT

Nuttah Tontcheva

SPECIES

Canine

BREED

Terrier X

SEX

FS

AGE

8 years

WEIGHT

11.3 kg

INTERPRETED BY

R. McKenzie Daniel,
DVM, DABVP
(Canine and Feline)

IMAGING PERFORMED BY

Dr. Sarah
Barthelemy

HOSPITAL NAME

Southwood
Veterinary Hospital

REFERRING VET

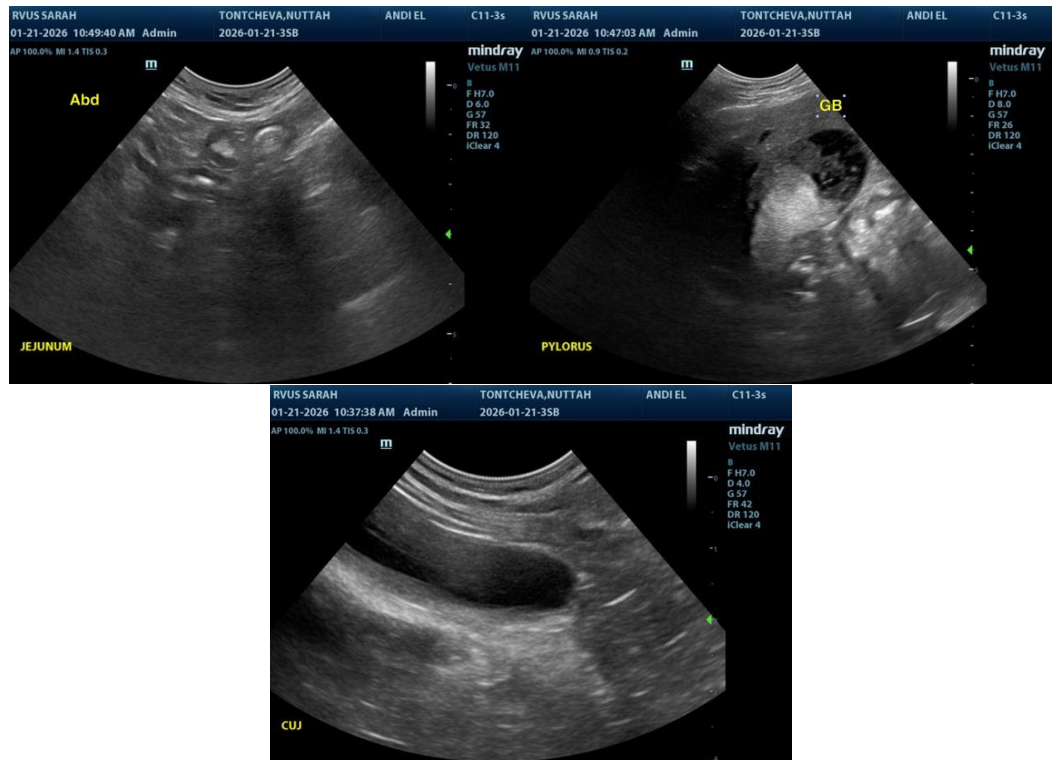
Dr. Harris

INVOICE

10570

DATE

1/21/26



The information and recommendations provided are based on the images presented by the referring veterinarian/sonographer. No evaluation can be communicated regarding pathology that was not visible in the image/video clips provided.

Thank you for this referral. If the clinical or image interpretation does not parallel your findings or if I can be of any further assistance, please contact me.

R. McKenzie Daniel, DVM, DABVP (Canine/Feline Practice)
info@sonopath.com