



PATIENT

Zeus Franklin

SPECIES

Canine

BREED

Pit Bull

SEX

NM

AGE

5 years 7 months

WEIGHT

80.7 lbs.

PRESENTING CLINICAL SIGNS

Reason for Visit: check skin History: 5yr 6m old NM pit bull presented today to check the skin. Both adjacent sides of penis have blood-filled growths (various sizes, relatively same shape). O noticed these growths about 2 months ago, started bleeding in the house. O says P does not seem to be in pain, or itchy. O says P has not received any veterinary care since DPC neutered him 12/2017.

Abnormal PE/Chem/CBC/UA Results: Hydration: Appropriately hydrated Mentation: BAR EENT: No nasal discharge; clear no discharge OU; clean no debris AU; No cough on tracheal palpation. Oral Cavity: Scant dental tartar present Lymph Nodes: Symmetrical, no changes in size, shape, consistency Skin: Good hair coat, no signs of ectoparasites. ~1.5 lobulated purplish growth to R of prepuce. Multiple ~0.5 cm raised red bumps to R of prepuce, one on caudodistal RF CV/Respiratory: No murmur or crackles/wheezing auscultated. Synchronous pulses, normal rate. Normal bronchovesicular sounds. Abd/GI: Soft non painful abdomen, no palpable masses Uro/Perineum: N Musculoskeletal: Ambulatory x4, no lameness noted. No pain on palpation of limbs. BCS 5/9 Neurological: Appropriate Diagnostic Testing Needed: cytology - explained will likely yield blood and be non-diagnostic, AUS - postponed for Saturday Additional Comments: Discussed with O that the "blood blisters" commonly arise from a growth on the spleen. Discussed FNA vs AUS. Discussed yunnan baiyao, can apply triple antibiotic as needed. Briefly discussed what the recommendations would be if there are multiple organs with tumors.

INTERPRETED BY

R. McKenzie Daniel,
DVM, DABVP
(Canine and Feline)

IMAGING PERFORMED BY

Michaleen

HOSPITAL NAME

DPC VH

REFERRING VET

Dr. White

INVOICE

15898

DATE

1-21-23

ULTRASONOGRAPHIC EXAMINATION OF THE ABDOMEN

Urinary System

The urinary bladder, trigone, cystourethral junction, and visible pelvic urethra exhibited normal thickness and tone. Anechoic urine was present in the lumen with no uroliths or sediment. The ureteral papillae were normal. The ureters were not visible which is normal. No evidence of inflammatory or neoplastic changes was noted.

No evidence of medial Iliac or sublumbar lymphadenopathy/masses.

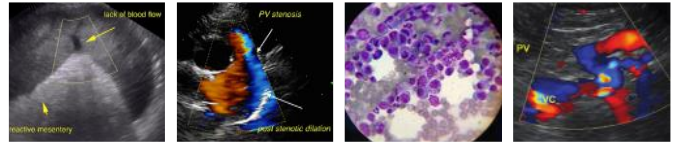
Normal size and margination were present in the kidneys. A normal 1:3 cortex / medulla ratio and normal corticomedullary definition were maintained. The echogenicity of the cortex was similar to or slightly less than normal liver parenchyma while the medulla echogenicity was hypoechoic to the cortex with no evidence of pelvic dilation. The left kidney measured 7.1 cm in length. The right kidney measured 6.6 cm in length.

Adrenal Glands

No overt pathology was noted in the area of the left or right adrenal glands, although not definitively visualized.

Spleen

The spleen exhibited a finely textured and homogenous parenchyma which was hyperechoic to the liver and renal cortical parenchyma. The capsule was smooth and regular without apparent expansion. The splenic vasculature at the hilus was normal in volume with no evidence of congestion or thrombosis. Acute to chronic inflammatory, neoplastic, or benign parenchyma changes were not noted.



PATIENT

Liver/ Gallbladder

Zeus Franklin

The liver was subjectively normal in size, structure, and contour. The liver parenchyma was uniform and hypoechoic to the spleen with a mild coarse echotexture. The hepatic and portal vasculature were normal in appearance without signs of congestion. The gallbladder was non-distended in size with thin walls and primarily anechoic luminal content. The cystic and common bile ducts were normal.

SPECIES

Canine

BREED

Pit Bull

SEX

NM

AGE

5 years 7 months

Gastrointestinal

The stomach presented intact wall layering with a normal wall layer ratio. Mild nonshadowing ingesta / chyme was present.

The small intestine presented intact wall layering with 1:3 muscularis/mucosa ratio. The lumen of the small intestine was empty with no signs of ileus, obstruction, or foreign material.

Normal visible colon wall layers were present with apparent formed feces in lumen.

WEIGHT

80.7 lbs.

Pancreas

The parenchyma of the left limb, body, and right limb of the pancreas presented isoechoic to the adjacent omental fat. A normal curvilinear capsule contour of the pancreas was present. The visible pancreatic duct was normal. No signs of active inflammation or neoplastic disease were evident.

INTERPRETED BY

R. McKenzie Daniel,
DVM, DABVP
(Canine and Feline)

Free Abdomen

No omental masses, lymphadenopathy, or evidence of peritoneal effusion were noted.

IMAGING PERFORMED BY

Michaleen

ULTRASONOGRAPHIC FINDINGS

- Sonographically normal abdomen

INTERPRETATION OF THE FINDINGS & FURTHER RECOMMENDATIONS

No sonographic evidence of visceral pathology, including no evidence of primary or metastatic intraabdominal neoplastic criteria.

HOSPITAL NAME

DPC VH

REFERRING VET

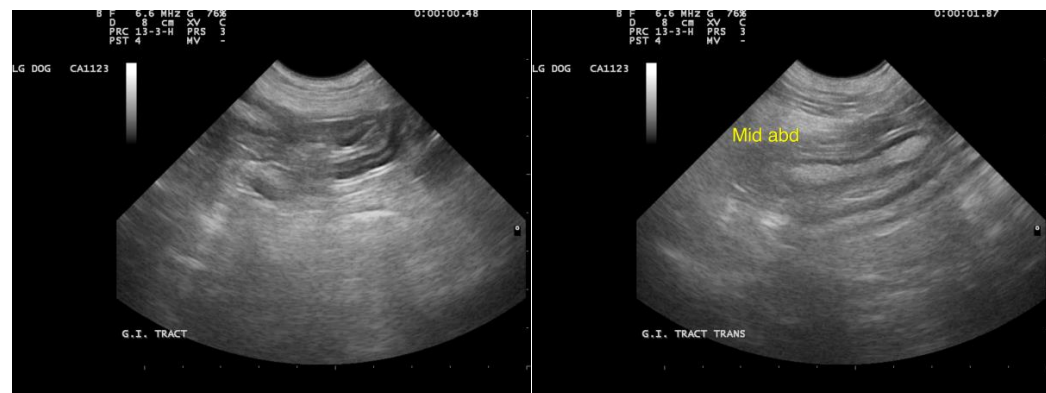Dr. White

INVOICE

15898

DATE

1-21-23





PATIENT

Zeus Franklin

SPECIES

Canine

BREED

Pit Bull

SEX

NM

AGE

5 years 7 months

WEIGHT

80.7 lbs.

INTERPRETED BY

R. McKenzie Daniel,
DVM, DABVP
(Canine and Feline)

IMAGING PERFORMED BY

Michaleen

HOSPITAL NAME

DPC VH

REFERRING VET

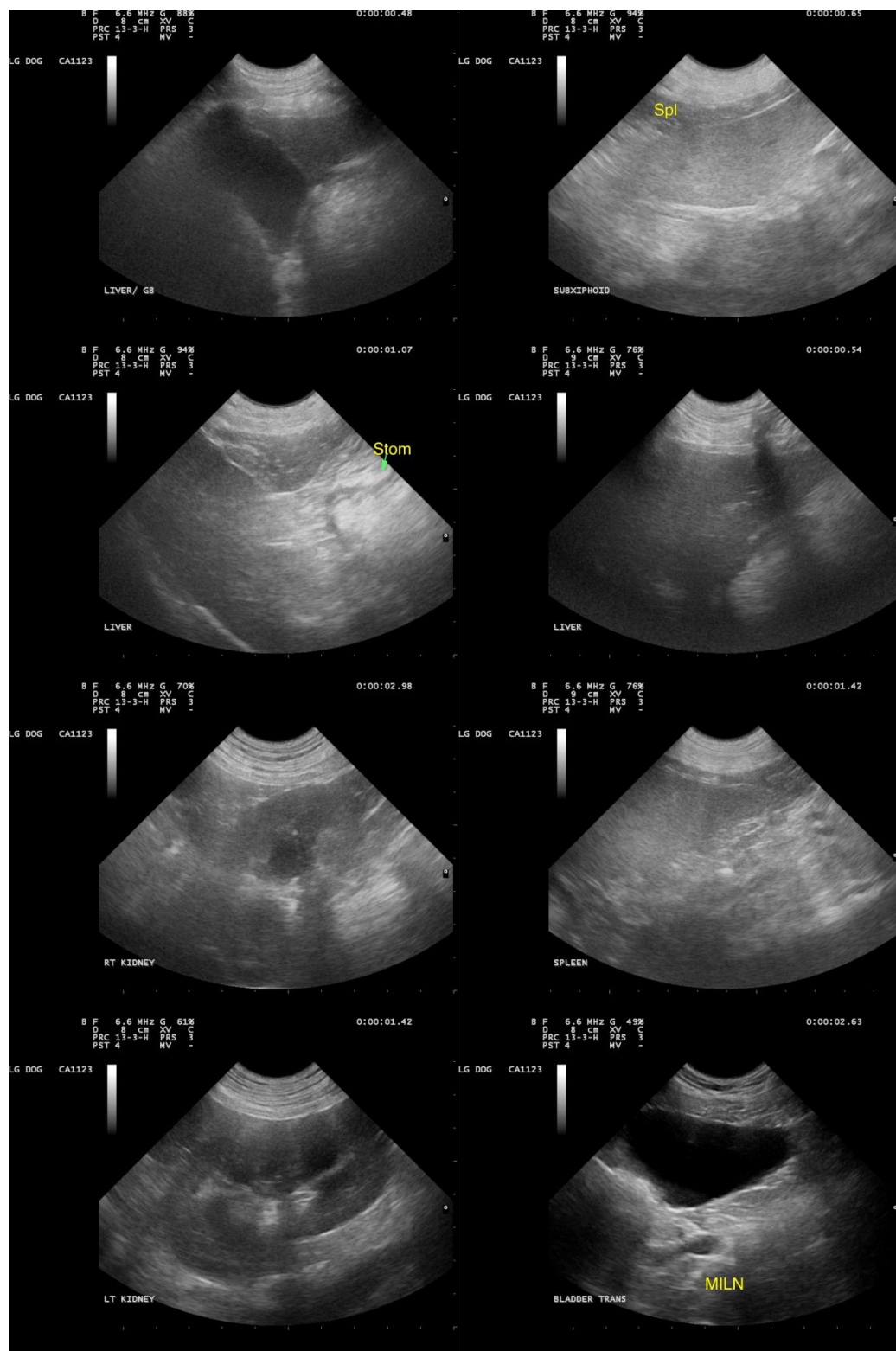
Dr. White

INVOICE

15898

DATE

1-21-23



The information and recommendations provided are based on the images presented by the referring veterinarian/sonographer. No evaluation can be communicated regarding pathology that was not visible in the image/video clips provided.



PATIENT

Zeus Franklin

Thank you for this referral. If the clinical or image interpretation does not parallel your findings or if I can be of any further assistance please contact me.

SPECIES

Canine

R. McKenzie Daniel, DVM, DABVP (Canine / Feline Practice)
info@SonoPath.com

BREED

Pit Bull

SEX

NM

AGE

5 years 7 months

WEIGHT

80.7 lbs.

INTERPRETED BY

R. McKenzie Daniel,
DVM, DABVP
(Canine and Feline)

**IMAGING
PERFORMED BY**

Michaleen

HOSPITAL NAME

DPC VH

REFERRING VET

Dr. White

INVOICE

15898

DATE

1-21-23