

PATIENT	PRESENTING CLINICAL SIGNS
Watermelon Gibson	rads suggestive of mass anterior cranial abdomen. not on any meds. Abnormal PE/Chem/CBC/UA Results: elevated rft's
SPECIES	ULTRASONOGRAPHIC EXAMINATION OF THE ABDOMEN
Feline	<i>Urinary System</i>
BREED	The urinary bladder, trigone, cystourethral junction, and visible pelvic urethra to a depth of 2.0 cm exhibited normal thickness and tone. Anechoic urine was present in the lumen with no uroliths or sediment. The ureteral papillae were normal. The ureters were not visible which is normal. No evidence of inflammatory or neoplastic changes were noted.
DSH	The area of the residual prostate appeared normal and free of pathology.
SEX	No evidence of pathology in the area of the aortic trifurcation.
MN	Normal size and margination was present in the kidneys. A normal 1:3 cortex / medulla ratio and normal corticomedullary definition were maintained. The echogenicity of the cortex was similar to or slightly less than normal liver parenchyma while the medulla echogenicity was hypoechoic to the cortex with no evidence of pelvic dilation. The left kidney measured 4.3 cm in length. The right kidney measured 4.8 cm in length.
AGE	<i>Adrenal Glands</i>
11 Years	The left adrenal gland was uniform in size and contour with a uniformly hypoechoic parenchyma. The left adrenal gland measured 0.29 cm width.
WEIGHT	No overt pathology in the area of the right adrenal gland.
17.8 lbs	<i>Spleen</i>
INTERPRETED BY	The spleen exhibited a finely textured and homogenous parenchyma which was hyperechoic to the liver and renal cortical parenchyma. The capsule was smooth and regular without apparent expansion. The splenic vasculature at the hilus was normal in volume with no evidence of congestion or thrombosis. Acute to chronic inflammatory, neoplastic, or benign parenchyma changes were not noted. The spleen measured 0.83 cm width.
R. McKenzie Daniel, DVM, DABVP (Canine and Feline)	<i>Liver / Gallbladder</i>
IMAGING PERFORMED BY	The left to mid liver exhibited normal size and contour with uniform parenchyma exhibiting normal echogenicity extending into the area of the right liver. Moderately sized to large nonhomogeneous hyperechoic to microcystic mass appearing to occupy and originate from the area of the mid to right liver extending caudally into the cranial to mid abdomen measuring approximately 9.0 x 5.0 cm. The mass was located adjacent to but yet not apparently impinging upon the area of the portal vein and potential caudal vena cava.
Diane McFadden	The gallbladder was non-distended in size containing anechoic fluid. Suspect nonspecific cystic biliary duct dilation containing anechoic fluid without evidence of concurrent common bile duct dilation.
HOSPITAL NAME	<i>Gastrointestinal</i>
Morris Hills VC	The stomach exhibited intact and sonographically unremarkable wall layering with mild to moderate retained anechoic fluid. No evidence of retained ingesta or foreign material. No overt evidence of mechanical pyloric outflow obstruction.
REFERRING VET	
Dr. Hirshenson	
INVOICE	
49711	
DATE	
1-21-22	



PATIENT	The small intestine presented intact wall layering with 1:3 muscularis/mucosa ratio. The lumen of the small intestine was empty with no signs of ileus, obstruction or foreign material.
Watermelon Gibson	Normal visible colon wall layers were present with apparent formed feces in lumen.
SPECIES	<i>Pancreas</i>
Feline	The parenchyma of the left limb, body and right limb of the pancreas presented isoechoic to the adjacent omental fat. A normal curvilinear capsule contour of the pancreas was present. The visible pancreatic duct was normal. No signs of active inflammation or neoplastic disease was evident.
BREED	<i>Free Abdomen</i>
DSH	No overt lymphadenopathy or peritoneal effusion was present.
SEX	ULTRASONOGRAPHIC FINDINGS
MN	<ul style="list-style-type: none"> • Mid to right liver mass. • Nondistended gallbladder with suspect nonspecific cystic biliary duct dilation - potential for bilobed gallbladder. • Mild retained gastric fluid - potential for mild metabolic stasis or hypomotility.
AGE	<u>INTERPRETATION OF THE FINDINGS & FURTHER RECOMMENDATIONS</u>
11 Years	Sonographic appearance of the mass was most consistent with hepatic origin with considerations including cystic biliary adenoma, cystic biliary adenocarcinoma, or other. Correlation with pending cytology obtained during the ultrasound of the mass without complication is recommended. Resectability of the mass is questionable given its location potentially adjacent to the porta hepatis, portal vein, and caudal vena cava.
WEIGHT	Potential for bilobed gallbladder is considered a normal patient variant in a cat and likely incidental.
17.8 lbs	No overt evidence of post-hepatic obstruction secondary to the hepatic mass.
INTERPRETED BY	Pending mass cytology, monitoring for evidence of cholestasis or gastric hypomotility would be appropriate.
R. McKenzie Daniel, DVM, DABVP (Canine and Feline)	
IMAGING PERFORMED BY	
Diane McFadden	
HOSPITAL NAME	
Morris Hills VC	
REFERRING VET	
Dr. Hirshenson	
INVOICE	
49711	
DATE	
1-21-22	



PATIENT

Watermelon Gibson

SPECIES

Feline

BREED

DSH

SEX

MN

AGE

11 Years

WEIGHT

17.8 lbs

INTERPRETED BY

R. McKenzie Daniel,
DVM, DABVP
(Canine and Feline)

IMAGING PERFORMED BY

Diane McFadden

HOSPITAL NAME

Morris Hills VC

REFERRING VET

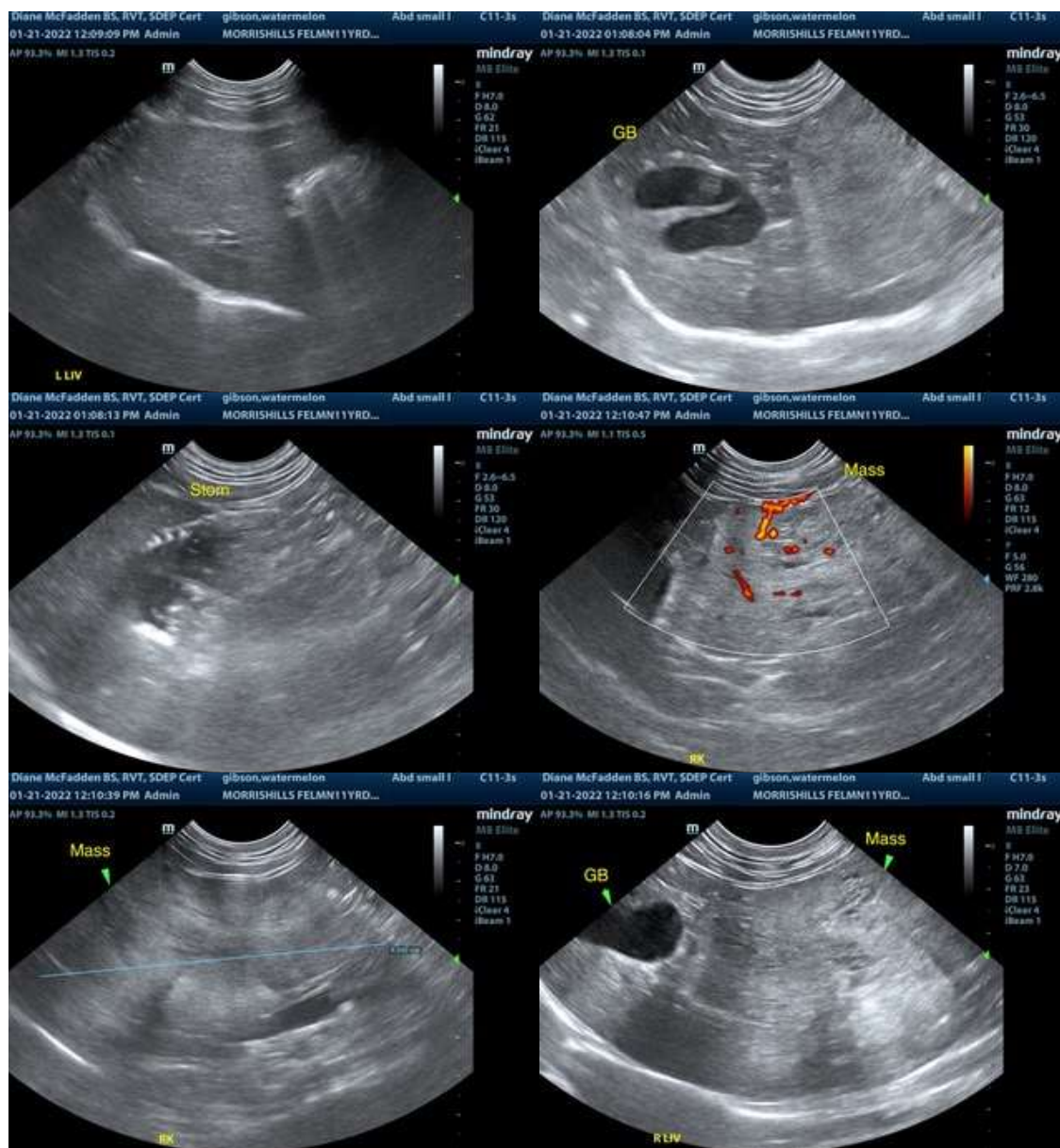
Dr. Hirshenson

INVOICE

49711

DATE

1-21-22





PATIENT

Watermelon Gibson

SPECIES

Feline

BREED

DSH

SEX

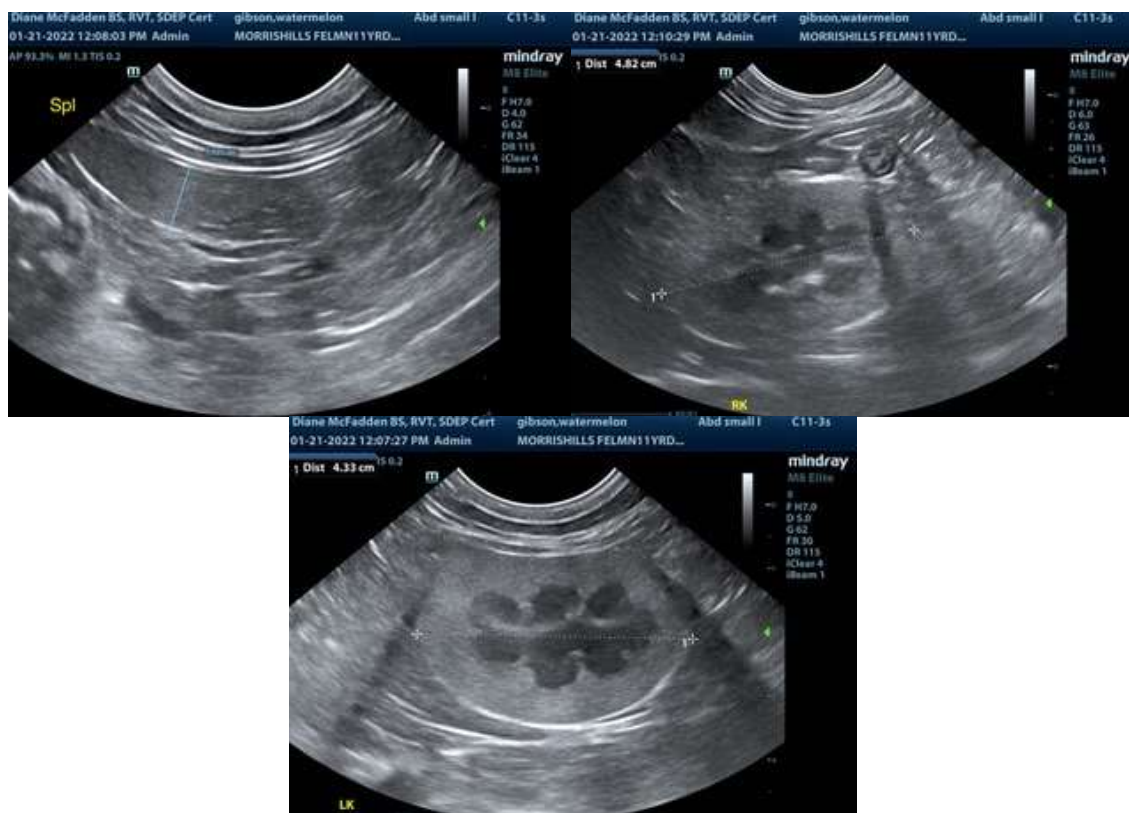
MN

AGE

11 Years

WEIGHT

17.8 lbs



INTERPRETED BY

R. McKenzie Daniel,
DVM, DABVP
(Canine and Feline)

IMAGING PERFORMED BY

Diane McFadden

HOSPITAL NAME

Morris Hills VC

REFERRING VET

Dr. Hirshenson

INVOICE

49711

DATE

1-21-22

The information and recommendations provided are based on the images presented by the referring veterinarian/sonographer. No evaluation can be communicated regarding pathology that was not visible in the image/video clips provided.

Thank you for this referral. If the clinical or image interpretation does not parallel your findings or if I can be of any further assistance please contact me.

R. McKenzie Daniel, DVM, DABVP (Canine / Feline Practice)
info@SonoPath.com