



PATIENT

Sandy Olson

SPECIES

Canine

BREED

Miniature Schnauzer

SEX

FS

AGE

8yr

WEIGHT

21lb

INTERPRETED BY

R. McKenzie Daniel,
DVM, DABVP
(Canine and Feline)

IMAGING PERFORMED BY

Jasmine Palacio

HOSPITAL NAME

River's Edge Pet
Medical Center

REFERRING VET

Dr. Shelby Young

INVOICE 23413

DATE
1-2-26

PRESENTING CLINICAL SIGNS

restless & itching, firm abdomen x5 days. no V/D, no C/S. Normal appetite. Scratching & restless since Monday, hiding, overall odd behavior. rDVM instructed O to pursue AUS if not improving with treatment started yesterday. Current Medications: all started yesterday: zenrelia 4.8mg, amoxicillin 100mg, gabapentin 100mg, liquid hepatic supplement. Dose of butorphanol administered in clinic prior to AUS.

Abnormal PE/Chem/CBC/UA Results: rDVM yesterday: hct 41.7%, mchc 40.5 (H), mch 27.6 (H), plt 358, wbc 9.1 (wnl). chem 10: tcho >450 (h), glob 3.8 (H), alp >993 (H), ggt 28 (rr 0-14), alt wnl, tbil wnl, crea & bun wnl. Pancreatic snap test possible faint positive per O report, no records. Today: panc lipase 66 (rr 0-200)

ULTRASONOGRAPHIC EXAMINATION OF THE ABDOMEN

Urinary System

The urinary bladder, trigone, cystourethral junction, and visible pelvic urethra to a depth of 2 cm exhibited normal thickness and tone. Anechoic urine was present in the lumen with urine sediment and multiple small urinary bladder cystourethral junction and proximal urethra non-obstructive lumen calculi. The ureteral papillae were normal. The ureters were not visible which is normal. No evidence of inflammatory or neoplastic changes was noted.

Normal size and margination were present in the kidneys. A normal 1:3 cortex / medulla ratio and normal corticomedullary definition were maintained. The echogenicity of the cortex was similar to or slightly less than normal liver parenchyma while the medulla echogenicity was hypoechoic to the cortex with no evidence of pelvic dilation. Bilateral areas of medullary mineral were present. The left kidney measured - cm in length. The right kidney measured - cm in length.

The area of the aortic trifurcation was free of pathology.

Adrenal Glands

The left adrenal gland was uniform in size and contour with a uniformly hypoechoic parenchyma. The left adrenal gland measured 0.52 cm width at the caudal pole. The right adrenal gland was uniform in size and contour with a uniformly hypoechoic parenchyma. The right adrenal gland measured 0.52 cm width at the caudal pole.

Spleen

The spleen exhibited a finely textured and homogenous parenchyma which was hyperechoic to the liver and renal cortical parenchyma. The capsule was smooth and regular without apparent expansion. The splenic vasculature at the hilus was normal in volume with no evidence of congestion or thrombosis. Acute to chronic inflammatory, neoplastic, or benign parenchyma changes were not noted.

Liver/Gallbladder

The liver presented possibly borderline increased in size. The parenchyma of the liver was subjectively mildly increased in echogenicity compared to the spleen and renal cortices. The echotexture of the



PATIENT

Sandy Olson

liver parenchyma was uniform with a mild coarse echotexture. The capsule of the liver was symmetrical in margination. The hepatic and portal vasculature were normal in appearance without signs of congestion. The gallbladder was non-distended in size with moderate congealed non-organized debris. The cystic and common bile ducts were normal.

SPECIES

Canine

Gastrointestinal

The stomach presented intact wall layering with a normal wall layer ratio. The lumen of the stomach contained mild variably echogenic to focally shadowing ingesta sonographically suggestive of food echogenicity with no signs of obstruction or foreign material.

BREED

Miniature Schnauzer

The small intestine presented intact wall layering with 1:3 muscularis/mucosa ratio. The lumen of the small intestine was empty with no signs of mechanical/metabolic ileus, obstruction or foreign material.

SEX

FS

Normal visible colon wall layers were present with apparent formed feces in lumen.

Pancreas

The pancreas was normal in size and contour with isoechoic to heterogeneous parenchyma compared to adjacent omentum. No signs of active inflammation or neoplasia.

AGE

8yr

Free Abdomen

No omental masses, overt lymphadenopathy or peritoneal effusion was present.

WEIGHT

21lb

Increased omental fat to possible indistinct abdominal lipomas.

ULTRASONOGRAPHIC FINDINGS

Primary

- Non-obstructive small urinary bladder calculi with urine sediment.
- Bilateral mild renal medullary mineral
- Normal bilateral adrenal glands
- Benign hepatopathy pattern.
- Congealed gallbladder debris to possible early immature mucocele
- Pancreatic remodeling.

INTERPRETED BY

R. McKenzie Daniel,
DVM, DABVP
(Canine and Feline)

INTERPRETATION OF THE FINDINGS & FURTHER RECOMMENDATIONS

Urinary workup including urine C/S is recommended. No evidence of intra-abdominal neoplastic criteria. Chronic pancreatitis may be suspected if cranial abdomen/subxiphoid discomfort on palpation, yet benign remodeling potentially secondary to previous inflammation is favored given no evidence of gastrointestinal signs and normal pancreatic lipase. Continued hepatosupportive medications and generalized as needed supportive care with clinical monitoring is recommended.

IMAGING PERFORMED BY

Jasmine Palacio

HOSPITAL NAME

River's Edge Pet
Medical Center

REFERRING VET

Dr. Shelby Young

INVOICE

23413

DATE

1-2-26



PATIENT

Sandy Olson

SPECIES

Canine

BREED

Miniature Schnauzer

SEX

FS

AGE

8yr

WEIGHT

21lb

INTERPRETED BY

R. McKenzie Daniel,
DVM, DABVP
(Canine and Feline)

IMAGING PERFORMED BY

Jasmine Palacio

HOSPITAL NAME

River's Edge Pet
Medical Center

REFERRING VET

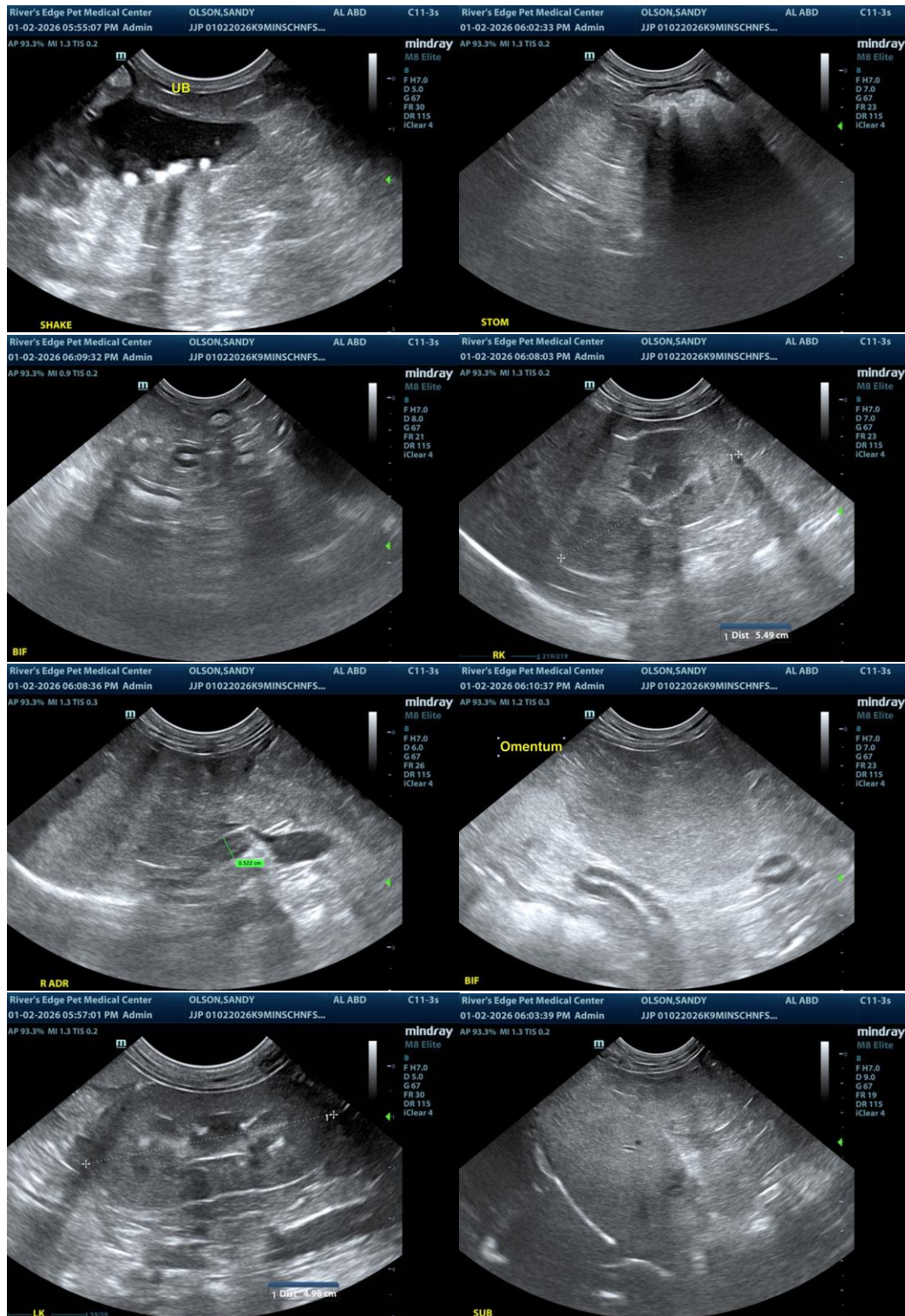
Dr. Shelby Young

INVOICE

23413

DATE

1-2-26





PATIENT

Sandy Olson

SPECIES

Canine

BREED

Miniature Schnauzer

SEX

FS

AGE

8yr

WEIGHT

21lb

INTERPRETED BY

R. McKenzie Daniel,
DVM, DABVP
(Canine and Feline)

IMAGING PERFORMED BY

Jasmine Palacio

HOSPITAL NAME

River's Edge Pet
Medical Center

REFERRING VET

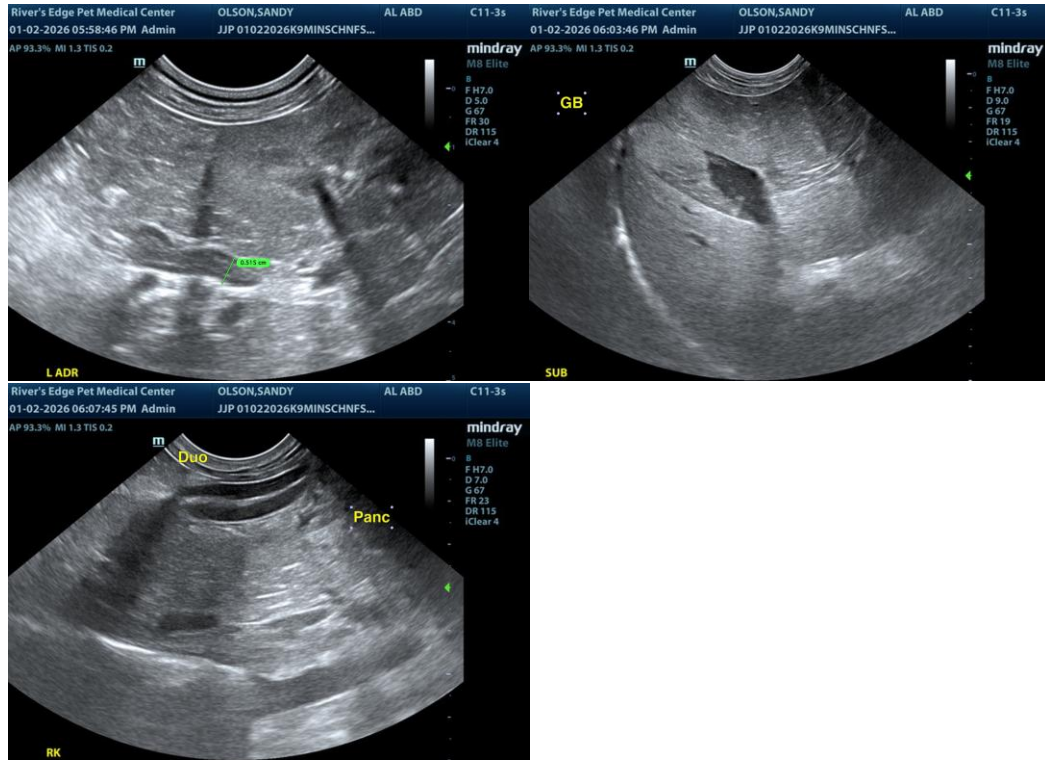
Dr. Shelby Young

INVOICE

23413

DATE

1-2-26



The information and recommendations provided are based on the images presented by the referring veterinarian/sonographer. No evaluation can be communicated regarding pathology that was not visible in the image/video clips provided.

Thank you for this referral. If the clinical or image interpretation does not parallel your findings or if I can be of any further assistance, please contact me.

R. McKenzie Daniel, DVM, DABVP (Canine/Feline Practice)
info@sonopath.com