



## PATIENT

Sam Katz

## SPECIES

Canine

## BREED

Mini Schnauzer

## SEX

Neutered Male

## AGE

1 Year 11 Months

## WEIGHT

8 kg

## INTERPRETED BY

R. McKenzie Daniel,  
DVM, DABVP

## IMAGING PERFORMED BY

Dr. Sookhoo

## HOSPITAL NAME

Calusa Veterinary  
Center

## REFERRING VET

Dr. Papell

## INVOICE

12915

## DATE

01/02/26

## PRESENTING CLINICAL SIGNS

Persistent diarrhea despite visbiome and pro pectalin. O administered Cerenia and visbiome a couple days ago and pt vomited the meds up about 5 times per O, no vomit after that day. Pt is E/D?U wnl and no C/S or lethargy reported.

Abnormal PE/Chem/CBC/UA Results: Baseline cortisol - 1.58ug/dL ACTH stim test today - pending

## ULTRASONOGRAPHIC EXAMINATION OF THE ABDOMEN

### Urinary System

The urinary bladder, trigone, cystourethral junction, and visible pelvic urethra to a depth of 3.0 cm exhibited normal thickness and tone. Anechoic urine was present in the lumen with no uroliths or sediment. The ureteral papillae were normal. The ureters were not visible which is normal. No evidence of inflammatory or neoplastic change were noted.

The residual prostate was sonographically normal.

The area of the aortic trifurcation was free of pathology.

Normal size and margination was present in the kidneys. A normal 1:3 cortex / medulla ratio and normal corticomedullary definition were maintained. The echogenicity of the cortex was similar to or slightly less than normal liver parenchyma while the medulla echogenicity was hypoechoic to the cortex with no evidence of pelvic dilation. The left kidney measured 4.5 cm in length. The right kidney measured 3.5 cm in length.

### Adrenal Glands

The left and right adrenal glands were subjective borderline subnormal in size with symmetrical contour and homogenous parenchyma. The left adrenal gland measured 0.29 cm width at the caudal pole. The right adrenal gland measured 0.31 cm width at the caudal pole.

### Spleen

The spleen exhibited a finely textured and homogenous parenchyma which was hyperechoic to the liver and renal cortical parenchyma. The capsule was smooth and regular without apparent expansion. The splenic vasculature at the hilus was normal in volume with no evidence of congestion or thrombosis. Acute to chronic inflammatory, neoplastic, or benign parenchyma changes were not noted.

### Liver

The liver was subjectively normal in size, structure, and contour. The liver parenchyma was uniform and hypoechoic to the spleen with a mild coarse echotexture. The hepatic and portal vasculature were normal in appearance without signs of congestion. The gallbladder was non-distended in size with thin walls and primarily anechoic luminal content. The cystic and common bile ducts were normal.

### Gastrointestinal

The stomach presented intact wall layering with a normal wall layer ratio. The lumen of the stomach contained variably echogenic, mild nonshadowing ingesta without signs of obstruction or foreign material.



## PATIENT

Sam Katz

## SPECIES

Canine

## BREED

Mini Schnauzer

## SEX

Neutered Male

## AGE

1 Year 11 Months

## WEIGHT

8 kg

## INTERPRETED BY

R. McKenzie Daniel,  
DVM, DABVP

## IMAGING PERFORMED BY

Dr. Sookhoo

## HOSPITAL NAME

Calusa Veterinary  
Center

## REFERRING VET

Dr. Papell

## INVOICE

12915

## DATE

01/02/26

The small intestine presented intact wall layering with 1:3 muscularis/mucosa ratio. The lumen of the small intestine was empty with no signs of ileus, obstruction or foreign material.

Normal visible colon wall layers were present with semi formed to soft fecal matter in lumen.

### **Pancreas**

The parenchyma of the left limb, body and right limb of the pancreas presented isoechoic to the adjacent omental fat. A normal curvilinear capsule contour of the pancreas was present. The visible pancreatic duct was normal. No signs of active inflammation or neoplastic disease was evident.

### **Free Abdomen**

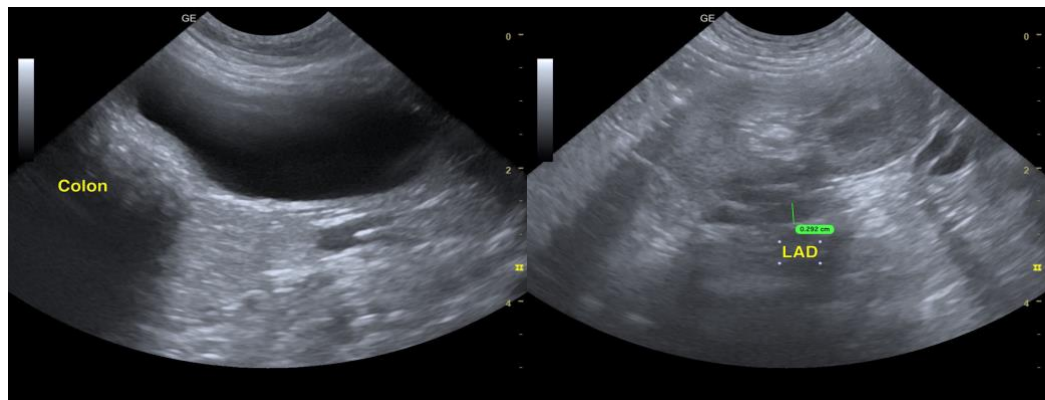
No overt lymphadenopathy or peritoneal effusion was present.

## ULTRASONOGRAPHIC FINDINGS

- Sonographically normal gastrointestinal tract with mild nonshadowing gastric ingesta.
- Normal colon containing semi formed to soft fecal matter.
- Subjective borderline subnormal adrenal glands.

## INTERPRETATION OF THE FINDINGS & FURTHER RECOMMENDATIONS

Correlation with pending ACTH stimulation test to assess/rule out occult Addison's disease is recommended. A GI panel to include PLI, TLI, cobalamin and folate and fresh fecal analysis if not recently done is warranted. A novel protein or hydrolyzed diet trial with possible long term dietary therapy, high colony count probiotics such as current VisBiome, empirical deworming despite fecal testing (Panacur 50 mg/kg SID for five days with repeat protocol in three weeks) and cobalamin supplementation (pending assessment of cobalamin level) may prove beneficial.





**PATIENT**

Sam Katz

**SPECIES**

Canine

**BREED**

Mini Schnauzer

**SEX**

Neutered Male

**AGE**

1 Year 11 Months

**WEIGHT**

8 kg

**INTERPRETED BY**

R. McKenzie Daniel,  
DVM, DABVP

**IMAGING  
PERFORMED BY**

Dr. Sookhoo

**HOSPITAL NAME**

Calusa Veterinary  
Center

**REFERRING VET**

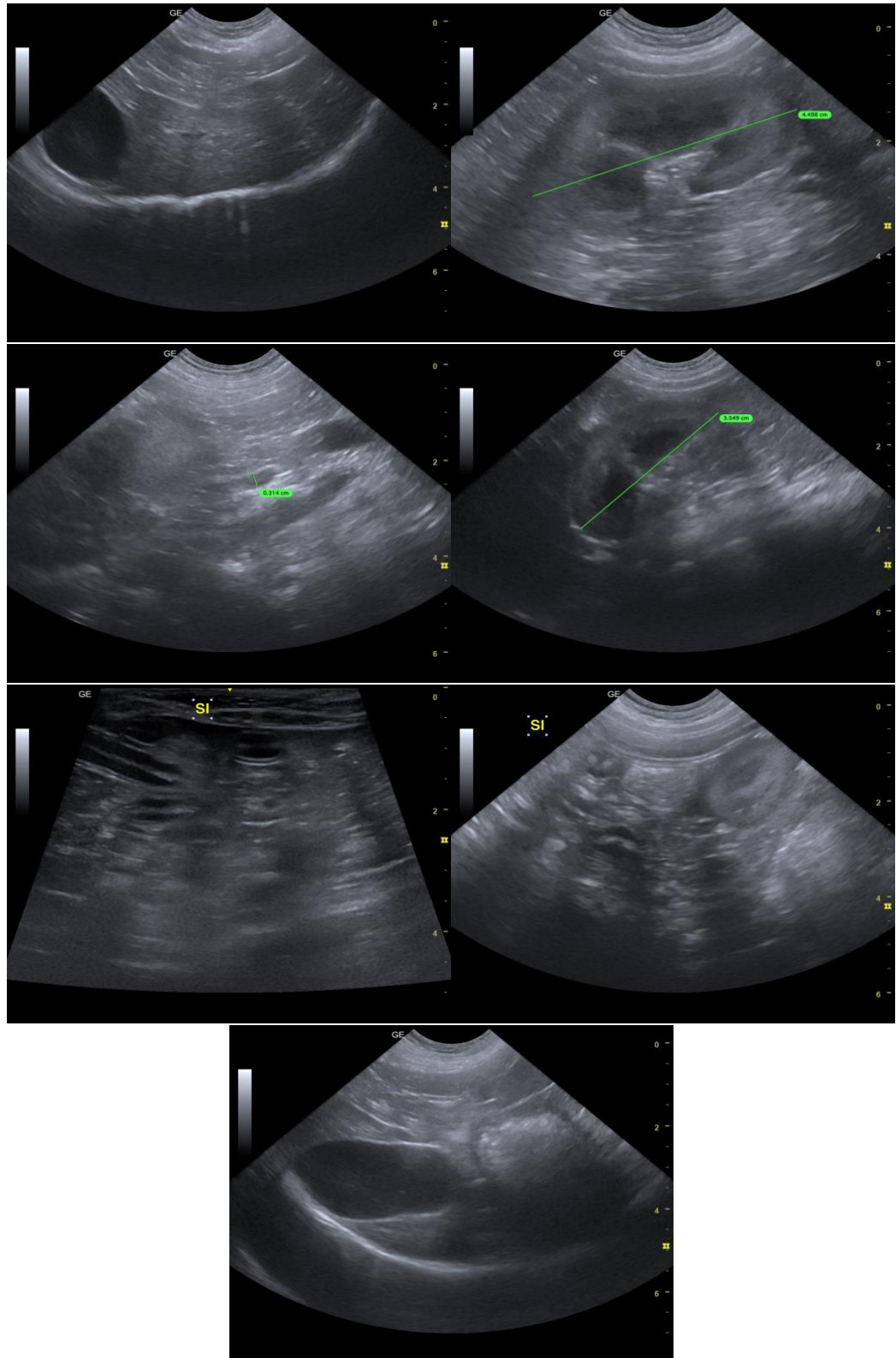
Dr. Papell

**INVOICE**

12915

**DATE**

01/02/26





## PATIENT

Sam Katz

## SPECIES

Canine

## BREED

Mini Schnauzer

## SEX

Neutered Male

## AGE

1 Year 11 Months

## WEIGHT

8 kg

## INTERPRETED BY

R. McKenzie Daniel,  
DVM, DABVP

## IMAGING PERFORMED BY

Dr. Sookhoo

## HOSPITAL NAME

Calusa Veterinary  
Center

## REFERRING VET

Dr. Papell

## INVOICE

12915

## DATE

01/02/26

The information and recommendations provided are based on the images presented by the referring veterinarian/sonographer. No evaluation can be communicated regarding pathology that was not visible in the image/video clips provided.

Thank you for this referral. If the clinical or image interpretation does not parallel your findings or if I can be of any further assistance, please contact me.

R. McKenzie Daniel, DVM, DABVP (Canine / Feline Practice)

[info@SonoPath.com](mailto:info@SonoPath.com)