



PATIENT

Ellie Pacetti

SPECIES

Canine

BREED

German Shepherd

SEX

FS

AGE

7

WEIGHT

103.2

INTERPRETED BY

R. McKenzie Daniel,
DVM, DABVP
(Canine and Feline)

IMAGING PERFORMED BY

Dr Gallick

HOSPITAL NAME

Magnolia Springs
Veterinary Center

REFERRING VET

Dr Gallick

INVOICE

23409

DATE

1-2-26

PRESENTING CLINICAL SIGNS

History: Hx of hematuria was put on antibiotics (clava) hematuria persisted, vaginal exam palpated normal

The submitted study contained 32 still images and videos of the urinary tract.

LIMITED ULTRASONOGRAPHIC EXAMINATION OF THE URINARY TRACT

Urinary System

The urinary bladder was normal in size and tone. Mildly thickened apical wall exhibiting mild polyploid component measuring 0.8 cm wall width was present. The trigone, cystourethral junction, and visible pelvic urethra to a depth of 2 cm exhibited normal thickness and tone. Anechoic urine was present in the lumen with mild primarily dependent lumen particulate sediment. No mineral or calculi.

The area of the uterine remnant appeared normal and free of pathology

Normal size and margination were present in the kidneys. A normal 1:3 cortex / medulla ratio and normal corticomedullary definition were maintained. The echogenicity of the cortex was similar to or slightly less than normal liver parenchyma while the medulla echogenicity was hypoechoic to the cortex with no evidence of pelvic dilation. The left kidney was primarily visualized in transverse plane. The right kidney measured 6.9 cm in length.

ULTRASONOGRAPHIC FINDINGS

Primary

- Mild apical polyploid cystitis pattern
- Normal bilateral kidneys

INTERPRETATION OF THE FINDINGS & FURTHER RECOMMENDATIONS

Recheck urine C/S on sterile urine sample warranted if seven days post completion of recent antibiotic protocol. Potential for emerging apical neoplastic criteria considered less likely. Screening BRAF assay warranted. No evidence of renal pathology or pyelonephritis as a contributing factor.



PATIENT

Ellie Pacetti

SPECIES

Canine

BREED

German Shepherd

SEX

FS

AGE

7

WEIGHT

103.2

INTERPRETED BY

R. McKenzie Daniel,
DVM, DABVP
(Canine and Feline)

IMAGING PERFORMED BY

Dr Gallick

HOSPITAL NAME

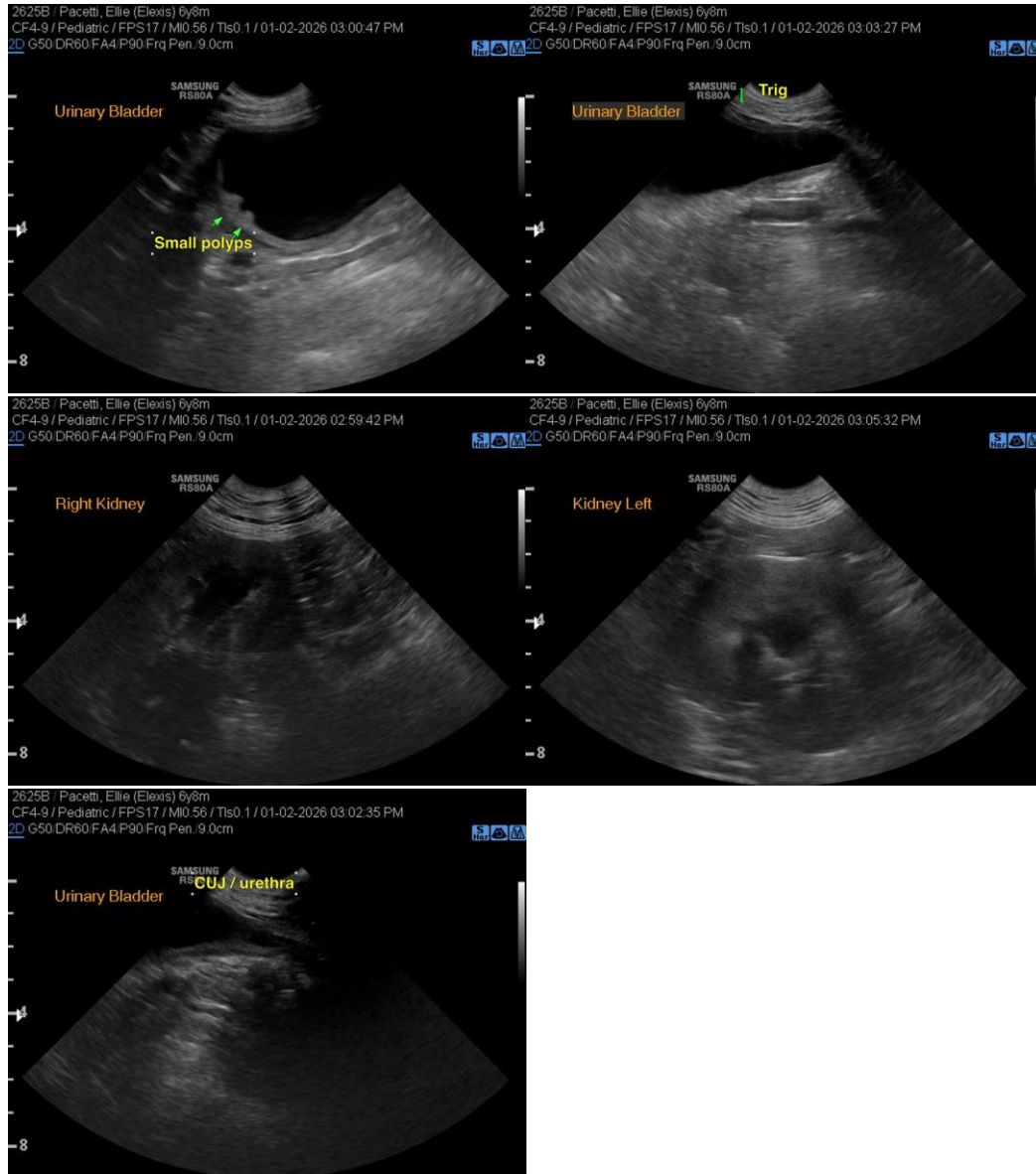
Magnolia Springs
Veterinary Center

REFERRING VET

Dr Gallick

INVOICE
23409

DATE
1-2-26



The information and recommendations provided are based on the images presented by the referring veterinarian/sonographer. No evaluation can be communicated regarding pathology that was not visible in the image/video clips provided.

Thank you for this referral. If the clinical or image interpretation does not parallel your findings or if I can be of any further assistance, please contact me.

R. McKenzie Daniel, DVM, DABVP (Canine/Feline Practice)
info@sonopath.com