



PATIENT

Luna Brown

SPECIES

Canine

BREED

French Bulldog

SEX

F

AGE

5yr

WEIGHT

14.4kg

INTERPRETED BY

R. McKenzie Daniel,
DVM, DABVP
(Canine and Feline)

IMAGING PERFORMED BY

Dr. Laura De Cordon

HOSPITAL NAME

Lakeview Animal
Hospital

REFERRING VET

Dr. Laura De Cordon

INVOICE 23397

DATE 01/02/2025

PRESENTING CLINICAL SIGNS

- is having a left anal gland saccullectomy - want to make sure there is no abdominal pathology

ULTRASONOGRAPHIC EXAMINATION OF THE ABDOMEN

Urinary System

The urinary bladder, trigone, cystourethral junction, and visible pelvic urethra to a depth of 3 cm exhibited normal thickness and tone. Anechoic urine was present in the lumen with no evidence of urine/lumen sediment, mineral, or calculi. The ureteral papillae were normal. The ureters were not visible which is normal. No evidence of inflammatory or neoplastic changes was noted.

Normal size and margination were present in the kidneys. A normal 1:3 cortex / medulla ratio and normal corticomedullary definition were maintained. The echogenicity of the cortex was similar to or slightly less than normal liver parenchyma while the medulla echogenicity was hypoechoic to the cortex with no evidence of pelvic dilation. The left kidney measured 4.6 cm in length. The right kidney measured 5.2 cm in length.

The area of the iliac trifurcation was free of pathology including no evidence of medial iliac or sublumbar lymphadenopathy or masses.

Adrenal Glands

The left adrenal gland was uniform in size and contour with a uniformly hypoechoic parenchyma. The left adrenal gland measured 0.41 cm width at the caudal pole. The right adrenal gland was not definitively visualized.

Spleen

The spleen exhibited a finely textured and homogenous parenchyma which was hyperechoic to the liver and renal cortical parenchyma. The capsule was smooth and regular without apparent expansion. The splenic vasculature at the hilus was normal in volume with no evidence of congestion or thrombosis. Acute to chronic inflammatory, neoplastic, or benign parenchyma changes were not noted.

Liver/Gallbladder

The liver was subjectively normal in size, structure, and contour. The liver parenchyma was uniform and hypoechoic to the spleen with a mild coarse echotexture. Normal vascular volume. The hepatic and portal vasculature were normal in appearance without signs of congestion. The gallbladder was non-distended in size with thin walls and mild gravity dependent non-organized debris. The cystic and common bile ducts were normal.

Gastrointestinal

The stomach presented intact wall layering with a normal wall layer ratio. The lumen of the stomach was empty with no signs of ileus, obstruction or foreign material.

The small intestine presented intact wall layering with 1:3 muscularis/mucosa ratio. The lumen of the small intestine was empty with no signs of mechanical/metabolic ileus, obstruction or foreign material.

Normal visible colon wall layers were present with apparent formed feces in lumen.



PATIENT

Pancreas

Luna Brown

The parenchyma of the left limb, body and right limb of the pancreas presented isoechoic to the adjacent omental fat. A normal curvilinear capsule contour of the pancreas was present. The visible pancreatic duct was normal. No signs of active inflammation or neoplastic disease was evident.

SPECIES

Canine

Free Abdomen

No omental masses, overt lymphadenopathy or peritoneal effusion was present.

BREED

French Bulldog

ULTRASONOGRAPHIC FINDINGS

Primary

SEX

F

- Sonographically normal abdomen
- Mild non-organized gallbladder debris (non-mucocele)

AGE

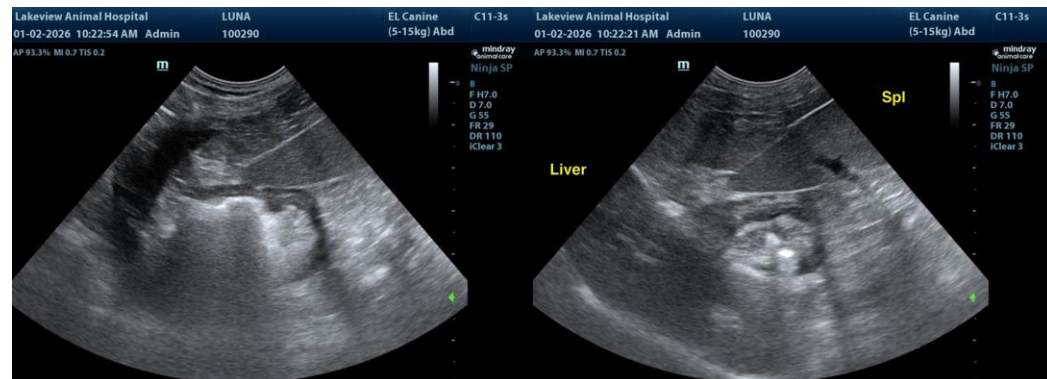
5yr

INTERPRETATION OF THE FINDINGS & FURTHER RECOMMENDATIONS

No evidence of primary or metastatic abdominal or retroperitoneal neoplastic criteria.

WEIGHT

14.4kg

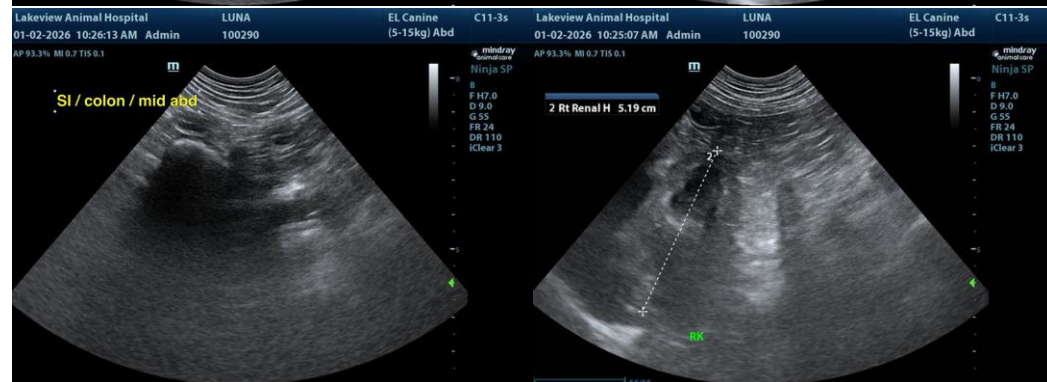


INTERPRETED BY

R. McKenzie Daniel,
DVM, DABVP
(Canine and Feline)

IMAGING PERFORMED BY

Dr. Laura De Cordon



HOSPITAL NAME

Lakeview Animal
Hospital

REFERRING VET

Dr. Laura De Cordon

INVOICE
23397

DATE
01/02/2025



PATIENT

Luna Brown

SPECIES

Canine

BREED

French Bulldog

SEX

F

AGE

5yr

WEIGHT

14.4kg

INTERPRETED BY

R. McKenzie Daniel,
DVM, DABVP
(Canine and Feline)

IMAGING PERFORMED BY

Dr. Laura De Cordon

HOSPITAL NAME

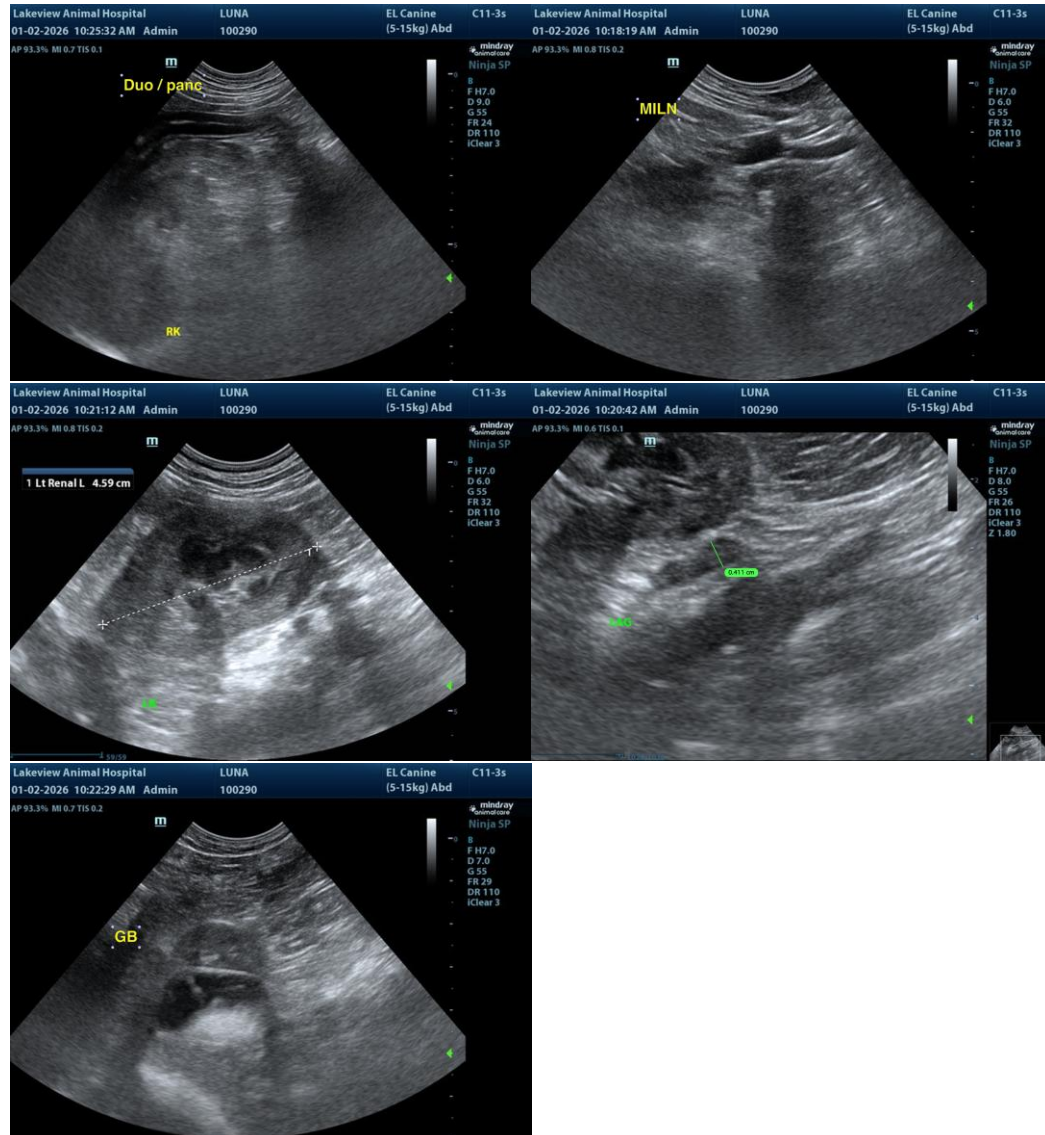
Lakeview Animal
Hospital

REFERRING VET

Dr. Laura De Cordon

INVOICE
23397

DATE
01/02/2025



The information and recommendations provided are based on the images presented by the referring veterinarian/sonographer. No evaluation can be communicated regarding pathology that was not visible in the image/video clips provided.

Thank you for this referral. If the clinical or image interpretation does not parallel your findings or if I can be of any further assistance, please contact me.

R. McKenzie Daniel, DVM, DABVP (Canine/Feline Practice)
info@sonopath.com