



**PATIENT**

Zoe Llewellyn

**SPECIES**

Canine

**BREED**

Cavapoo

**SEX**

Spayed Female

**AGE**

5 Years

**WEIGHT**

29.8

**INTERPRETED BY**

R. McKenzie Daniel,  
DVM, DABVP

**IMAGING PERFORMED BY**

Marco Litchfield

**HOSPITAL NAME**

Sova Animal Hospital

**REFERRING VET**

Dr. Alteire

**INVOICE**

13260

**DATE**

01/19/26

**PRESENTING CLINICAL SIGNS**

- Pet has a history of reoccurring UTI and hematuria along with a hooded vulva

Abnormal PE/Chem/CBC/UA Results: Pending UA and culture results

**LIMITED ULTRASONOGRAPHIC EXAMINATION**

**Urinary System**

The urinary bladder presented normal in size and tone. Mild thickened ventroapical to dorsoapical urinary bladder wall with associated mild asymmetrical luminal surface contour. The trigone and cystourethral junction were free of pathology. Anechoic urine was present in the lumen with nondependent particulate urine sediment along with subjective areas of focal nondependent to adhered apical to ventroapical luminal surface mineral. The ureteral papillae were normal. The ureters were not visible which is normal.

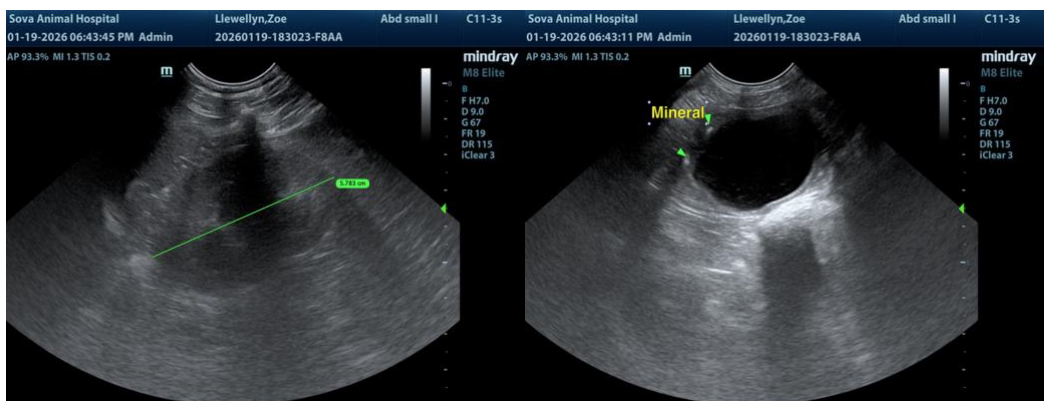
Normal size and margination was present in the kidneys. A normal 1:3 cortex / medulla ratio and normal corticomedullary definition were maintained. The echogenicity of the cortex was similar to or slightly less than normal liver parenchyma while the medulla echogenicity was hypoechoic to the cortex with no evidence of pyelectasia. The left kidney measured 5.8 cm in length. The right kidney measured 5.4 cm in length.

**ULTRASONOGRAPHIC FINDINGS**

- Cystitis pattern with urine sediments and nondependent to focally adhered luminal apical lumen surface mineral.
- Normal bilateral kidneys.

**INTERPRETATION OF THE FINDINGS & FURTHER RECOMMENDATIONS**

Correlation with pending urinalysis and culture/sensitivity is recommended. No evidence of urinary bladder neoplastic criteria or visualized overt congenital defect. Ascending infection owing to vulva conformational abnormality may be suspected.





## PATIENT

Zoe Llewellyn

## SPECIES

Canine

## BREED

Cavapoo

## SEX

Spayed Female

## AGE

5 Years

## WEIGHT

29.8

## INTERPRETED BY

R. McKenzie Daniel,  
DVM, DABVP

## IMAGING PERFORMED BY

Marco Litchfield

## HOSPITAL NAME

Sova Animal Hospital

## REFERRING VET

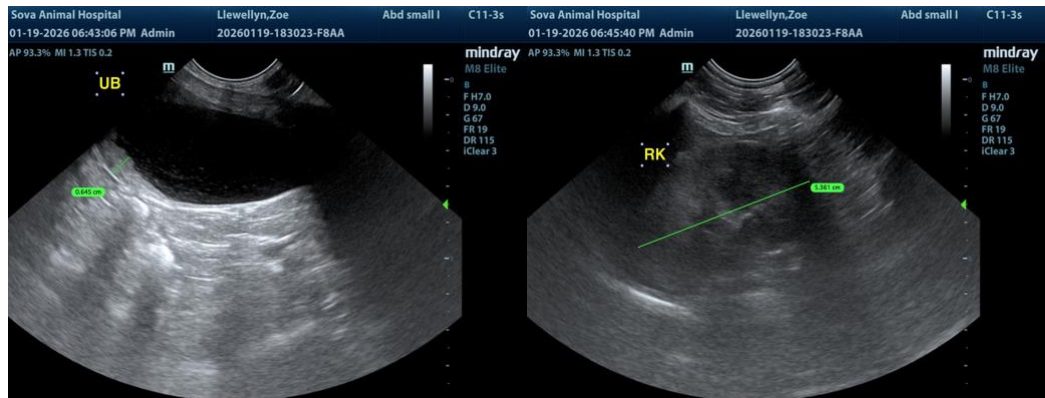
Dr. Alteire

## INVOICE

13260

## DATE

01/19/26



The information and recommendations provided are based on the images presented by the referring veterinarian/sonographer. No evaluation can be communicated regarding pathology that was not visible in the image/video clips provided.

Thank you for this referral. If the clinical or image interpretation does not parallel your findings or if I can be of any further assistance, please contact me.

R. McKenzie Daniel, DVM, DABVP (Canine / Feline Practice)

[info@SonoPath.com](mailto:info@SonoPath.com)