



PATIENT

Hades Christian

SPECIES

Feline

BREED

DSH

SEX

Neutered Male

AGE

6 Years

WEIGHT

9.1 Pounds

PRESENTING CLINICAL SIGNS

History: Newly dx grade II/VI heart murmur, asymptomatic. No current meds.
Abnormal PE/Chem/CBC/UA Results: Pending, cysto pending.

ULTRASONOGRAPHIC EXAMINATION OF THE HEART & ABDOMEN

FELINE CARDIAC PARAMETERS	BODY WEIGHT (kg)	HR (BPM)	IVSd (cm)	LVIDd (cm)	LVWd (cm)	FS (%)	EF (%)
NORMAL PARAMETER	-----	150-240	0.3-0.6	1.0-2.1	0.25-0.6	35-67	80-100
PATIENT	--	181	0.44	1.3	0.40	51	86
FELINE CARDIAC PARAMETERS	LA/AO (Boon)	LA/AO HEART BASE (Sisson)	LA 2D 4-chamber long axis AS to FW (Sisson) (cm)	LVOT VEL. (m/s)	RVOT VEL. (m/s)	IVRT (m/)	
NORMAL PARAMETER	<1.5	0.88-1.79	0.7-1.7	<1.6	<1.3	40-60	
PATIENT	1.3	1.3	1.3	1.0	1.1	NM	
Adapted from June Boon, Veterinary Echocardiography, 1998 Sisson D et al. JVIM 1991; 5: 232, Jacobs et al. Am J Vet Res 1985; 46:1705							

Cardiac Presentation

The echocardiogram in this patient demonstrated normal **left atrial** size based on 3 separate LA measurements. The cranial and caudal **mitral** valve leaflets presented normal linear structure and kinetics. No overt MR on doppler. The **left ventricle** presented normal thicknesses with linear contour and was not dilated nor restricted. The **myocardium** presented normal echogenicity without subjective evidence of significant fibrotic or ischemic disease. **Contractility** of the ventricular walls was adequate and in normal range for this patient evidenced by the fractional shortening measurement and subjective evaluation of the different regions and angles of the myocardium. The **left ventricular outflow** tract demonstrated normal laminar flow and subjective structural integrity. Normal measured LVOT velocity was noted. The **right atrium** and auricle revealed normal size, structure and content. No evidence of masses was noted or chamber overload. **Tricuspid** valvular assessment demonstrated adequate linear morphology and kinetics. The **right ventricle** was of normal size (1/3 diameter of LV), chordae structure, myocardial echogenicity and thickness. **Pulmonic** tract assessment revealed normal valve structure, laminar flow, and diameter (approx.1:1 pa/ao ratio). Normal measured RVOT velocity was noted. No visible **pericardial** or free pleura fluid was noted or extra cardiac pathology in the visible planes. The cranial **mediastinum and pericardial regions** were free of masses in the visible window.

Urinary System

The urinary bladder, trigone, cystourethral junction, and visible pelvic urethra to a depth of 2.0 cm exhibited normal thickness and tone. Primarily anechoic urine was present in the lumen. Moderate nondependent particulate mildly hyperechoic sediment was present, which may indicate cellular debris/protein, crystalline debris, lipid or mucus. The ureteral papillae were normal. The ureters were

INTERPRETED BY

R. McKenzie Daniel,
DVM, DABVP
(Canine and Feline)

IMAGING PERFORMED BY

Shari Reffi, CVT

HOSPITAL NAME

Newton VH

REFERRING VET

Dr. Kim

INVOICE

20625

DATE

1/19/23



PATIENT	not visible which is normal. No evidence of inflammatory or neoplastic mural changes were noted. No evidence of inflammatory mural changes. Aortic trifurcation was normal.
Hades Christian	
SPECIES	Normal size and margination were present in the kidneys. A normal 1:3 cortex / medulla ratio and normal corticomedullary definition were maintained. The echogenicity of the cortex was similar to or slightly less than normal liver parenchyma while the medulla echogenicity was hypoechoic to the cortex with no evidence of pelvic dilation. The left kidney measured 4.0 cm in length. The right kidney measured 4.4 cm in length.
Feline	
BREED	Adrenal Glands
DSH	No evidence of pathology in the area of the left or right adrenal glands.
SEX	Spleen
Neutered Male	The spleen exhibited a finely textured and homogenous parenchyma which was hyperechoic to the liver and renal cortical parenchyma. The capsule was smooth and regular without apparent expansion. The splenic vasculature at the hilus was normal in volume with no evidence of congestion or thrombosis. Acute to chronic inflammatory, neoplastic, or benign parenchyma changes were not noted. The spleen measured 0.8 cm in width at the level of the hilus.
AGE	Liver
6 Years	The liver was subjectively normal in size, structure, and contour. The liver parenchyma was uniform and hypoechoic to the spleen with a mild coarse echotexture. The hepatic and portal vasculature were normal in appearance without signs of congestion.
WEIGHT	The gallbladder was normal in size, appearing to be divided into two separate compartments, both containing anechoic content without evidence of inflammatory criteria. The cystic and common bile ducts were normal.
9.1 Pounds	
INTERPRETED BY	Gastrointestinal
R. McKenzie Daniel, DVM, DABVP (Canine and Feline)	The stomach presented intact wall layering with a normal wall layer ratio. The lumen of the stomach was empty with no signs of ileus, obstruction or foreign material.
IMAGING PERFORMED BY	The small intestine presented intact wall layering with 1:3 muscularis/mucosa ratio. The lumen of the small intestine was empty with no signs of ileus, obstruction or foreign material.
Shari Reffi, CVT	
HOSPITAL NAME	Normal visible colon wall layers were present with apparent formed feces in lumen.
Newton VH	
REFERRING VET	Pancreas
Dr. Kim	The pancreas appeared to be mildly prominent in size with maintained symmetrical capsule contour with mild uniform hypoechoic parenchyma compared to adjacent nonreactive or hyperechoic peripancreatic omentum.
INVOICE	Free Abdomen
20625	No omental masses, lymphadenopathy or peritoneal effusion was present.
DATE	ULTRASONOGRAPHIC FINDINGS
1/19/23	<ul style="list-style-type: none"> Normal echocardiogram- benign flow murmur



PATIENT

Hades Christian

- Urinary bladder sediment
- Mildly prominent to hypoechoic pancreas
- Bilobed gallbladder- normal variant in a cat

SPECIES

Feline

BREED

DSH

SEX

Neutered Male

AGE

6 Years

WEIGHT

9.1 Pounds

INTERPRETED BY

R. McKenzie Daniel,
DVM, DABVP
(Canine and Feline)

IMAGING PERFORMED BY

Shari Reffi, CVT

HOSPITAL NAME

Newton VH

REFERRING VET

Dr. Kim

INVOICE

20625

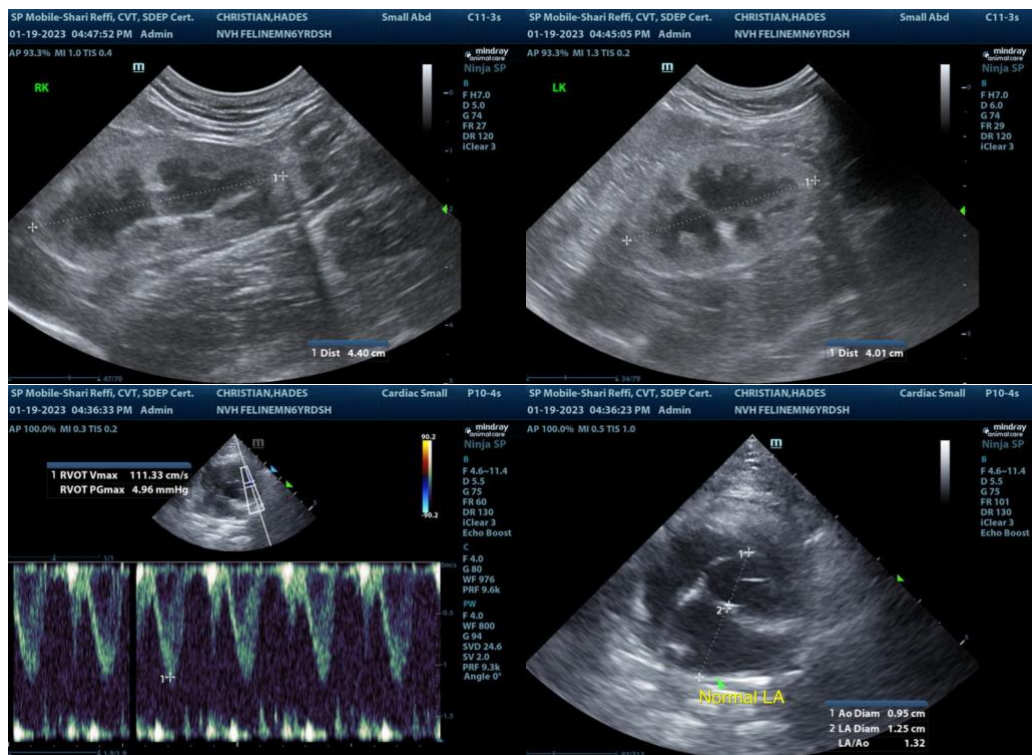
DATE

1/19/23

INTERPRETATION OF THE FINDINGS & FURTHER RECOMMENDATIONS

No evidence of structural or functional cardiomyopathy, without a definitive cause of the murmur identified. No evidence of left or right heart chamber enlargement, significant valvular insufficiencies or stenotic disease. In the absence of volume changes, such as dehydration or anemia, benign flow murmur appears to be present. No indication for cardiac medications. Conservative monitoring of the murmur at this stage is recommended. Recheck echocardiogram is recommended in 12 months or sooner if murmur intensity increases or if clinical signs arise. Correlation with urinary bladder sediment with pending urinalysis +/- culture and sensitivity if evidence of inflammatory cells.

The pancreas may be a normal patient variant. Potential for low grade pancreatitis may be suspected if evidence of cranial abdominal or subxiphoid discomfort on palpation. Correlation with a spec fPL could be considered if clinically indicated.





PATIENT

Hades Christian

SPECIES

Feline

BREED

DSH

SEX

Neutered Male

AGE

6 Years

WEIGHT

9.1 Pounds

INTERPRETED BY

R. McKenzie Daniel,
DVM, DABVP
(Canine and Feline)

IMAGING PERFORMED BY

Shari Reffi, CVT

HOSPITAL NAME

Newton VH

REFERRING VET

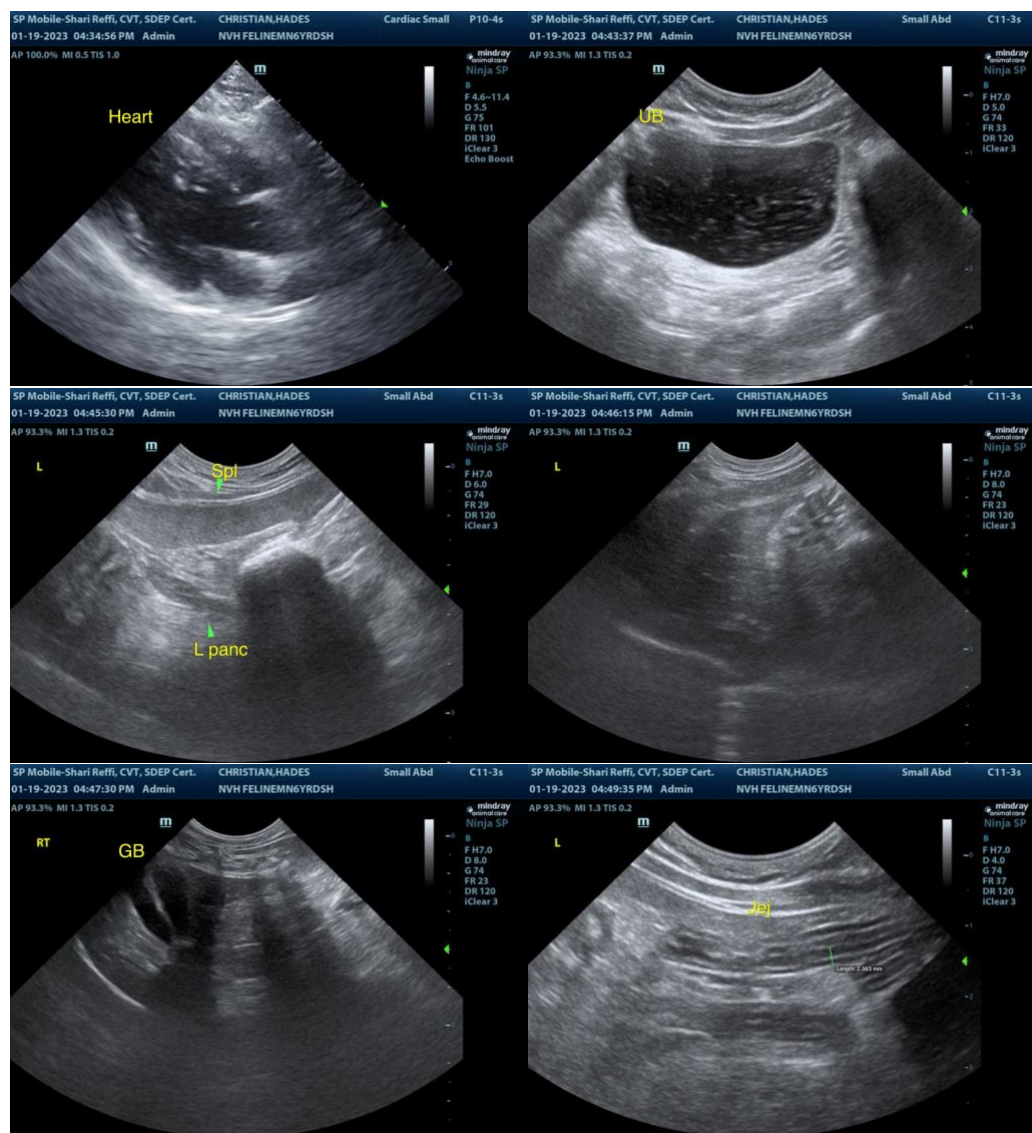
Dr. Kim

INVOICE

20625

DATE

1/19/23



The information and recommendations provided are based on the images presented by the referring veterinarian. No evaluation can be communicated regarding pathology that was not visible in the image/video clips provided.

Thank you for this referral. If the clinical or image interpretation does not parallel your findings or if I can be of any further assistance please contact me.

R. McKenzie Daniel, DVM, DABVP (Canine / Feline Practice)
info@SonoPath.com