



PATIENT

Macy Anderson

SPECIES

Canine

BREED

Cockapoo

SEX

FS

AGE

15yr

WEIGHT

22.6lb

INTERPRETED BY

R. McKenzie Daniel,
DVM, DABVP
(Canine and Feline)

IMAGING PERFORMED BY

Pamela Harrigan,
RDCS, Certified
Veterinary
Sonographer (IVUSS)

HOSPITAL NAME

Norfolk County
Veterinary Service

REFERRING VET

Aurora Richards, DVM

PRESENTING CLINICAL SIGNS

December 2024 - neurological episodes, seizure-like activity, unable to walk. Cleared up on anti-inflammatory dose of prednisone. Profuse sebaceous adenomas with resistant secondary skin infections (owner declined biopsies). Elevated liver values: ALT 219, ALP 1681 GGTP 48. BIN 52, SDMA 14.6, chol 452, trig 892. T4 0.4; FT4 normal. R/O lyme disease, adrenal disease, kidney disease neoplasia. On: :Prednisone 5 mg, 1.5 SID, Keppra 250 mg TID, Deamarin

ULTRASONOGRAPHIC EXAMINATION OF THE ABDOMEN

Urinary System

The urinary bladder, trigone, cystourethral junction, and visible pelvic urethra to a depth of 3 cm exhibited normal thickness and tone. Anechoic urine was present in the lumen with no evidence of urine or lumen sediment, mineral, or calculi. The ureteral papillae were normal. The ureters were not visible which is normal. No evidence of inflammatory or neoplastic changes was noted.

Normal renal size with asymmetrical margination was present in both kidneys. The renal cortex presented uniformly increased in echogenicity with uniform echotexture. The renal cortex appeared to be hypertrophied resulting in an altered cortex: medulla ratio. Mild loss of corticomedullary distinction was also present. The renal medullary volume was subjectively reduced. Bilateral areas of pinpoint medullary mineral were present. The left kidney measured 4.8 cm in length. The right kidney measured 4.8 cm in length.

The area of the aortic trifurcation was free of pathology.

Adrenal Glands

The bilateral adrenal glands were normal in size. Mild parenchyma heterogeneity and mild capsule asymmetry was present without suspicion for overt neoplasia. The left adrenal gland measured 0.41 cm width in the caudal pole. The right adrenal gland measured 0.37 cm width in the caudal pole.

Spleen

The spleen exhibited multiple solitary to coalescing hyperechoic nodules, mild asymmetrical splenic capsule contour and overall heterogeneous parenchyma. An example of a nodule measured 0.73 cm in diameter.

Liver/Gallbladder

The liver exhibited enlargement. The liver parenchyma was mildly non-homogenous and hypoechoic to the spleen with a moderate variable coarse echotexture and subjective mild to benign parenchymal remodeling. A moderately sized to expansive non-homogenous mixed echogenic to non-uniform hyperechoic mass occupying the mid to left liver exhibiting intermittent intramass cystic nodules measuring ~ 6-7 cm in diameter was present. The hepatic and portal vasculature were normal in appearance without signs of congestion. The gallbladder was non-distended in size with thin walls and mild non-organized debris. The cystic and common bile ducts were normal.

Gastrointestinal

INVOICE

23594

DATE

01/18/2026



PATIENT

Macy Anderson

SPECIES

Canine

BREED

Cockapoo

SEX

FS

AGE

15yr

WEIGHT

22.6lb

INTERPRETED BY

R. McKenzie Daniel,
DVM, DABVP
(Canine and Feline)

IMAGING PERFORMED BY

Pamela Harrigan,
RDCS, Certified
Veterinary
Sonographer (IVUSS)

HOSPITAL NAME

Norfolk County
Veterinary Service

REFERRING VET

Aurora Richards, DVM

INVOICE

23594

DATE

01/18/2026

The stomach presented intact wall layering with a normal wall layer ratio. The lumen of the stomach was empty with no signs of ileus, obstruction or foreign material.

The small intestine presented intact wall layering with 1:3 muscularis/mucosa ratio. The lumen of the small intestine was empty with no signs of mechanical/metabolic ileus, obstruction or foreign material.

Normal visible colon wall layers were present with apparent formed feces in lumen.

Pancreas

The pancreas was normal in size and contour with isoechoic to heterogeneous parenchyma compared to adjacent omentum. No signs of active inflammation or neoplasia.

Free Abdomen

No evidence of overt lymphadenopathy was present.

Minor perihepatic effusion was present.

ULTRASONOGRAPHIC FINDINGS

Primary

- Hepatopathy with mid to left liver mass
- Non-organized gallbladder debris
- Hyperechoic to coalescing splenic nodules-most suggestive of benign criteria, i.e. myelolipomas
- Bilateral chronic renal changes
- Normal age-related adrenal changes
- Pancreatic remodeling

INTERPRETATION OF THE FINDINGS & FURTHER RECOMMENDATIONS

Although sampling is required for further clarification, the liver mass is strongly suggestive of neoplastic criteria, i.e. carcinoma or other. Assuming normal clotting status and using a 25g needle, a liver mass FNA for screening cytology could be considered for further assessment. No evidence of adrenal pathology.

Continued hepatosupportive medications including ursodiol if tolerated with clinical and as needed sonographic monitoring would be more conservative. A UA +/- C/S or UPC level for renal staging may be considered.



PATIENT

Macy Anderson

SPECIES

Canine

BREED

Cockapoo

SEX

FS

AGE

15yr

WEIGHT

22.6lb

INTERPRETED BY

R. McKenzie Daniel,
DVM, DABVP
(Canine and Feline)

IMAGING PERFORMED BY

Pamela Harrigan,
RDCS, Certified
Veterinary
Sonographer (IVUSS)

HOSPITAL NAME

Norfolk County
Veterinary Service

REFERRING VET

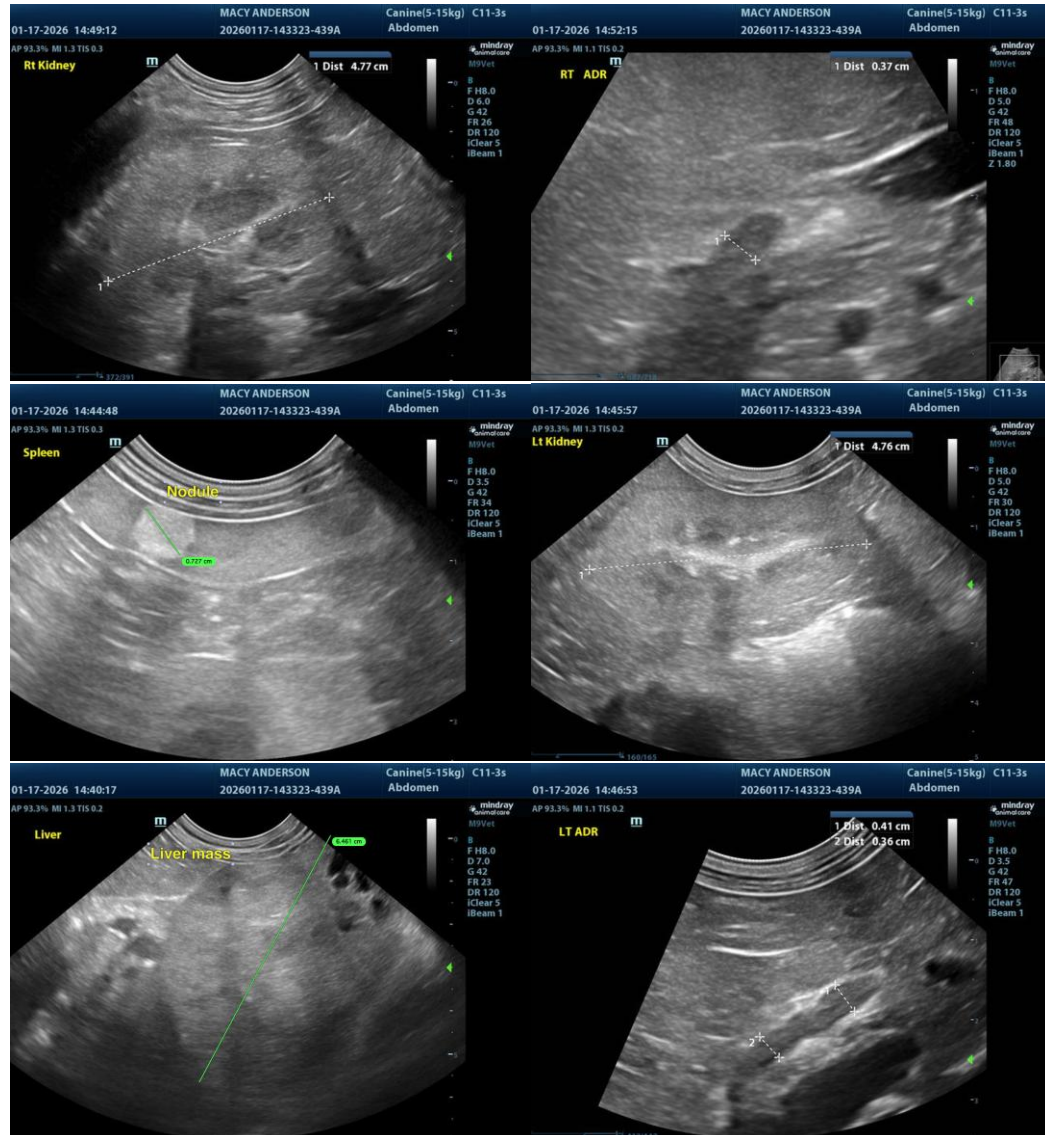
Aurora Richards, DVM

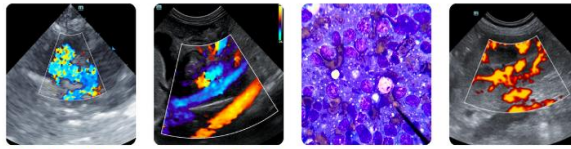
INVOICE

23594

DATE

01/18/2026





PATIENT

Macy Anderson

SPECIES

Canine

BREED

Cockapoo

SEX

FS

AGE

15yr

WEIGHT

22.6lb

INTERPRETED BY

R. McKenzie Daniel,
DVM, DABVP
(Canine and Feline)

IMAGING PERFORMED BY

Pamela Harrigan,
RDCS, Certified
Veterinary
Sonographer (IVUSS)

HOSPITAL NAME

Norfolk County
Veterinary Service

REFERRING VET

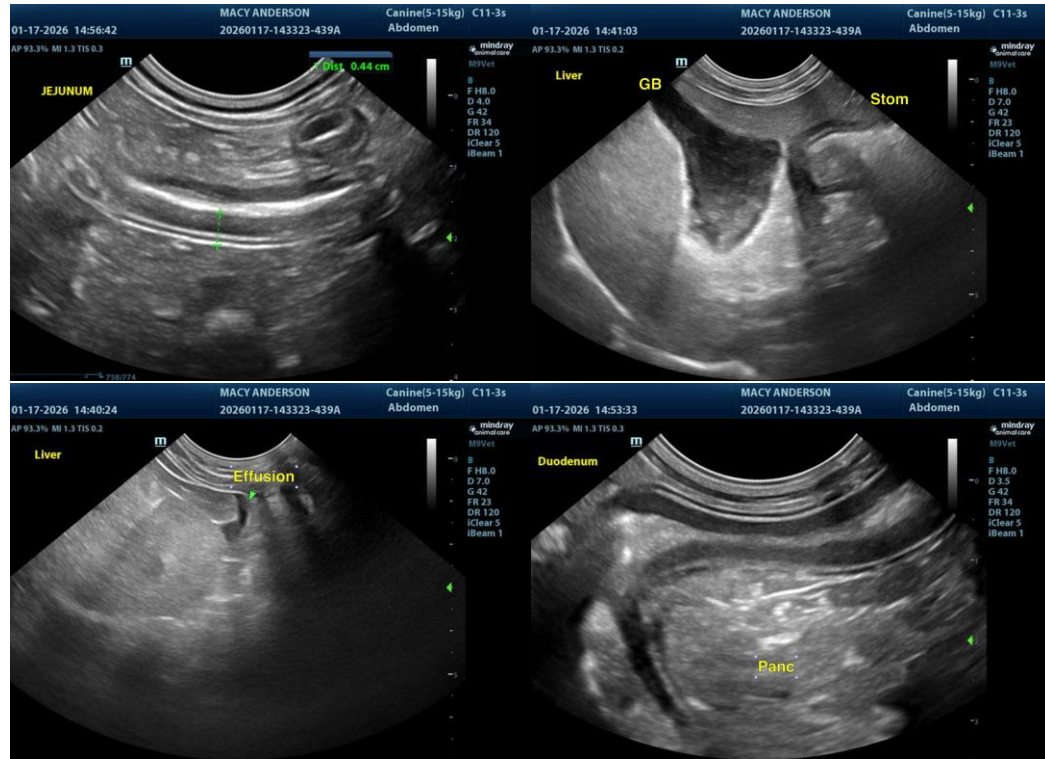
Aurora Richards, DVM

INVOICE

23594

DATE

01/18/2026



The information and recommendations provided are based on the images presented by the referring veterinarian/sonographer. No evaluation can be communicated regarding pathology that was not visible in the image/video clips provided.

Thank you for this referral. If the clinical or image interpretation does not parallel your findings or if I can be of any further assistance, please contact me.

R. McKenzie Daniel, DVM, DABVP (Canine/Feline Practice)
info@sonopath.com