SonoPath
Clinical Sonography & Telecytology
EDUCATIONAL TELECONSULTATION SERVICES™

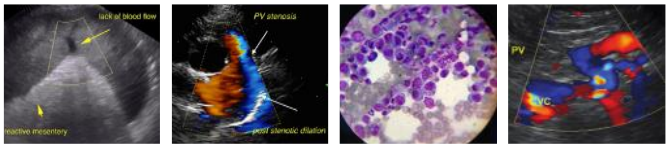

SonoPath.com™
1-800-838-4268 info@sonopath.com

PATIENT
Lucy Bertrand

SPECIES
Canine

BREED
Bichon Mix

SEX
FS

AGE
21

WEIGHT
13 y

INTERPRETED BY
R. McKenzie Daniel, DVM, DABVP (Canine and Feline)

IMAGING PERFORMED BY
Hope Brossman

HOSPITAL NAME
Animal Mansion VH

REFERRING VET
Jon Bertoldo DVM

INVOICE
15861

DATE
1/18/23

PRESENTING CLINICAL SIGNS

Coughing- treated for tracheobronchitis to no relief, Grade 2-3 L sided murmur, Enlarged silhouette on radiographs

ULTRASONOGRAPHIC EXAMINATION OF THE HEART

CANINE CARDIAC PARAMETERS	MR VMAX (m/s)	TR VMAX (m/s)	LA/AO (Boon method)	LA/AO (Heart Base; Swe)	FS (%)	EF (%)	EPSS (cm)
NORMAL PARAMETER	4.5-5.5	<2.7	1.3	<1.3	28-40	40-100	<0.6
PATIENT				2.0	52	86	0.22
CANINE CARDIAC PARAMETERS	**HR** (BPM)	**AV VMAX** (m/s)	**PV MAX** (m/s)	**BODY WEIGHT** (kg)	**LA** 2D short axis Base view (cm)	**LVIDd** Avg; 2D and m-mode short axis (cm)	**LVIDs** Avg; 2D and m-mode short axis (cm)
NORMAL PARAMETER	50-100	0.7-1.7	0.7-1.6				
PATIENT	NM	NM	NM		4.0	3.4	

Cardiac Presentation

The echocardiogram in this patient demonstrated moderate increased **left atrial** size based on 2 different LA measurement methods. Mild deviation of the interatrial septum towards the right atrium, suggestive of mild increased left atrial pressure, was present. The cranial and caudal **mitral** valve leaflets presented moderate thickening consistent with endocardiosis more prominent in the septal leaflet with mild septal leaflet prolapse. No chordae tendineae rupture was noted. Doppler indicated moderate eccentric insufficiency. The **left ventricle** presented normal thicknesses with linear contour and mild to moderate increased LV volume. The **myocardium** presented normal echogenicity without subjective evidence of significant fibrotic or ischemic disease. **Contractility** of the ventricular walls was adequate and in normal range for this patient evidenced by the fractional shortening measurement and subjective evaluation of the different regions of the myocardium. The **left ventricular outflow** tract demonstrated normal laminar flow and subjective structural integrity. The **right atrium** and auricle revealed normal size, structure and content. No evidence of masses was noted or chamber overload. **Tricuspid** valvular assessment demonstrated adequate linear morphology. The **right ventricle** was of normal size (1/3 diameter of LV), chordae structure, myocardial echogenicity and thickness. **Pulmonic** tract assessment revealed normal valve structure, laminar flow, and diameter (approx.1:1 pa/ao ratio). No visible **pericardial** or free pleura fluid was noted. No echographically detectable evidence of infiltrative disease was visible. The cranial **mediastinum and pericardial regions** were free of masses in the visible window. No arrhythmia was noted.

ULTRASONOGRAPHIC FINDINGS

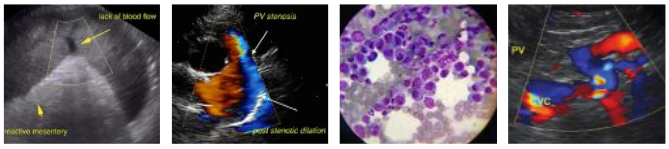

SonoPath.com™
1-800-838-4268 info@sonopath.com

PATIENT

Lucy Bertrand

SPECIES

Canine

BREED

Bichon Mix

SEX

FS

AGE

21

WEIGHT

13 y

INTERPRETED BY

R. McKenzie Daniel, DVM, DABVP (Canine and Feline)

IMAGING PERFORMED BY

Hope Brossman

HOSPITAL NAME

Animal Mansion VH

REFERRING VET

Jon Bertoldo DVM

INVOICE

15861

DATE

1/18/23

- Chronic mitral valve disease with mild septal leaflet prolapse (ACVIM B2)

INTERPRETATION OF THE FINDINGS & FURTHER RECOMMENDATIONS

The moderately increased left atrial size indicates that the current and future risk secondary to MR is moderately elevated. No other additional clinical issues such as LV systolic dysfunction or evidence of RA/RV enlargement, which may indicate clinical pulmonary hypertension, were present.

The coughing in this patient may be multifactorial in origin potentially owing to emerging congestion, mainstem bronchi, compression or irritation owing to moderate LA enlargement, and / or concurrent chronic lower airway disease. Pimobendan 0.3 mg/kg PO BID, lowest effective dose of Lasix 1.0-2.0 mg/kg PO BID, as well as anti-tussive medication Hydrocodone at the appropriate dose, with as-needed respiratory support is recommended with an assessment of clinical response. Baseline monitoring of resting respiration rate going forward is advised. ACE inhibitor medication may be considered if systemic BP is greater than 130, (not advised if BP <130). Omega-3 fatty acids and mild salt restriction may prove beneficial.

Prognosis is highly variable and serial sonographic monitoring is recommended. Recheck echocardiogram is suggested in 6 months, sooner if progressive clinical signs arise.

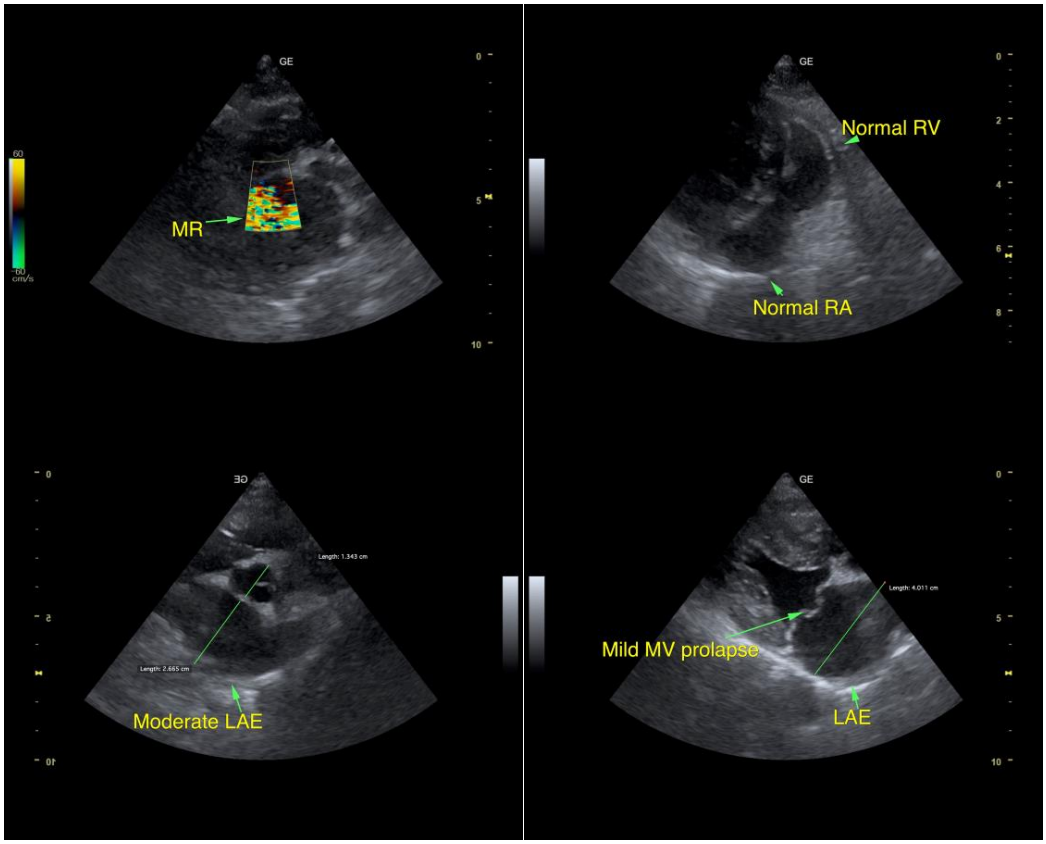

The information and recommendations provided are based on the images presented by the referring veterinarian/sonographer. No evaluation can be communicated regarding pathology that was not visible in the image/video clips provided.

SonoPath
Clinical Sonography & Telecytology
EDUCATIONAL TELECONSULTATION SERVICES™

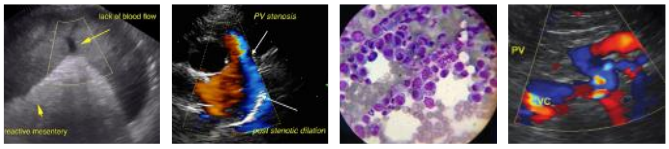

SonoPath.com™
1-800-838-4268 info@sonopath.com

PATIENT

Lucy Bertrand

SPECIES

Canine

BREED

Bichon Mix

SEX

FS

AGE

21

WEIGHT

13 y

INTERPRETED BY

R. McKenzie Daniel, DVM, DABVP (Canine and Feline)

IMAGING PERFORMED BY

Hope Brossman

HOSPITAL NAME

Animal Mansion VH

REFERRING VET

Jon Bertoldo DVM

INVOICE

15861

DATE

1/18/23

Thank you for this referral. If the clinical or image interpretation does not parallel your findings or if I can be of any further assistance please contact me.

R. McKenzie Daniel, DVM, DABVP (Canine / Feline Practice)
info@SonoPath.com