



PATIENT

Fritz Dostoevsky

SPECIES

Feline

BREED

DSH

SEX

MN

AGE

15 years

WEIGHT

10 lbs.

INTERPRETED BY

R. McKenzie Daniel,
DVM, DABVP
(Canine and Feline)

IMAGING PERFORMED BY

Kim Liedberg

HOSPITAL NAME

SVS Imaging WI

REFERRING VET

Dr Klein, Pet Care in Motion

INVOICE

13097

DATE

1/18/22

PRESENTING CLINICAL SIGNS

Double cavity check for any abnormalities. Litter mate passed away suddenly of carcinomatosis.

ULTRASONOGRAPHIC EXAMINATION OF THE HEART & ABDOMEN

FELINE CARDIAC PARAMETERS	BODY WEIGHT (kg)	HR (BPM)	IVSd (cm)	LVIDd (cm)	LVWd (cm)	FS (%)	EF (%)
NORMAL PARAMETER	-----	150-240	0.3-0.6	1.0-2.1	0.25-0.6	35-67	80-100
PATIENT		209	0.43	1.3	0.35	56.9	91.4
FELINE CARDIAC PARAMETERS	LA/AO (Boon)	LA/AO HEART BASE (Sisson)	LA 2D 4-chamber long axis AS to FW (Sisson) (cm)	LVOT VEL. (m/s)	RVOT VEL. (m/s)	IVRT (m/)	
NORMAL PARAMETER	<1.5	0.88-1.79	0.7-1.7	<1.6	<1.3	40-60	
PATIENT	1.25	1.1	1.1	1.0	1.0	NM	
Adapted from June Boon, Veterinary Echocardiography, 1998							
Sisson D et al. JVIM 1991; 5: 232, Jacobs et al. Am J Vet Res 1985; 46:1705							

Cardiac Presentation

The echocardiogram in this patient demonstrated enlarged **left atrial** size based on 3 separate LA measurements. The cranial and caudal **mitral** valve leaflets presented normal linear structure and kinetics. The **left ventricular** septum and free wall revealed adequate contractility, normal IVS, and LV free wall thickness with normal LV volume, yet some mild myocardial remodeling of the septum and free wall were noted. This is most consistent with some level of **myocardial fibrosis**. The **left ventricular outflow** tract demonstrated normal laminar flow and subjective structural integrity. Trace AV insufficiency was present on color doppler assessment. The **right atrium** and auricle revealed increased size and normal content. No evidence of masses was noted or chamber overload. **Tricuspid** valvular assessment demonstrated adequate linear morphology and kinetics. Mild TV insufficiency was present on color doppler assessment. TR measured 1.3 m/s. The **right ventricle** was of normal size (1/3 diameter of LV), chordae structure, myocardial echogenicity and thickness. **Pulmonic** tract assessment revealed normal valve structure, laminar flow, and diameter (approx. 1:1 pa/ao ratio). No visible **pericardial** or free pleura fluid was noted or extra cardiac pathology in the visible planes. The cranial **mediastinum and pericardial regions** were free of masses in the visible window.

Urinary System

The urinary bladder, trigone, cystourethral junction, and visible pelvic urethra to a depth of 2.0 cm exhibited normal thickness and tone. Anechoic urine was present in the lumen with no uroliths or



PATIENT

Fritz Dostoevsky

sediment. The ureteral papillae were normal. The ureters were not visible which is normal. No evidence of inflammatory or neoplastic changes was noted.

SPECIES

Feline

The area of the aortic trifurcation was free of pathology.

BREED

DSH

Normal size and margination were present in the kidneys. A normal 1:3 cortex / medulla ratio was maintained. The medulla and cortices were uniform in texture with some increased echogenicity and mild loss of corticomedullary symmetry and definition expected for the age of the patient. No evidence of pelvic dilation was present. The left kidney measured 3.4 cm in length. The right kidney measured 3.5 cm in length.

SEX

MN

Adrenal Glands

The left adrenal gland was uniform in size and contour with a uniformly hypoechoic parenchyma. The left adrenal gland measured 0.47 cm width. The right adrenal gland was uniform in size and contour with a uniformly hypoechoic parenchyma. The right adrenal gland measured 0.40 cm width.

AGE

15 years

Spleen

The spleen exhibited primarily finely textured and homogenous parenchyma which was hyperechoic to the liver and renal cortical parenchyma. Small, hyperechoic echogenic nodules were present throughout the cranial to caudal parenchyma. The capsule was smooth and regular without apparent expansion. The splenic vasculature at the hilus was normal in volume with no evidence of congestion or thrombosis. Acute to chronic inflammatory or neoplastic changes were not noted. The echogenic nodules tend to trend benign and are most consistent with benign hyperplasia or myelolipomas. The overall spleen measured 0.83 cm width.

WEIGHT

10 lbs.

INTERPRETED BY

R. McKenzie Daniel,
DVM, DABVP
(Canine and Feline)

Liver/ Gallbladder

The liver was subjectively normal in size, structure, and contour. The liver parenchyma was mildly nonuniform and hypoechoic to the spleen with a moderate coarse echotexture and subjective mild to benign parenchymal remodeling. A solitary, non-expansive discreet hypoechoic intraparenchymal nodule was noted in the mid ventral liver, measuring 0.93 cm in diameter. The hepatic and portal vasculature were normal in appearance without signs of congestion. The gallbladder was non-distended in size with thin walls and primarily anechoic luminal content. The cystic and common bile ducts were normal.

IMAGING PERFORMED BY

Kim Liedberg

HOSPITAL NAME

SVS Imaging WI

REFERRING VET

Dr Klein, Pet Care in Motion

Gastrointestinal

The stomach presented intact wall layering with a normal wall layer ratio. The lumen of the stomach was empty with no signs of ileus, obstruction, or foreign material.

INVOICE

13097

The small intestine presented intact wall layering with 1:3 muscularis/mucosa ratio. The lumen of the small intestine was empty with no signs of ileus, obstruction, or foreign material. The jejunal wall width measured 0.20 cm. The ileocolic wall width measured 0.42 cm.

DATE

1/18/22

Normal visible colon wall layers were present with apparent formed feces in lumen.

Pancreas



PATIENT

Fritz Dostoevsky

The pancreas was normal in size and contour with isoechoic to heterogeneous parenchyma compared to adjacent omentum. No signs of active inflammation or neoplasia.

SPECIES

Feline

Free Abdomen

BREED

DSH

Intermittent, jejunocolic lymph nodes were present. The lymph nodes were essentially isoechoic to adjacent omentum without evidence of peripheral inflammation and maintaining a normal width: length ratio (<0.5). An example lymph node measured 0.44 cm width. No omental masses or peritoneal effusion was present.

SEX

MN

ULTRASONOGRAPHIC FINDINGS

Primary Findings

AGE

15 years

- Overtly normal cardiac structure and function with mild LV myocardial remodeling
- Mild TR with trace AV Insufficiency - not considered clinically significant
- Mild chronic renal changes
- Benign splenic nodules - suggestive of probable benign myelolipomas
- Mild hepatic parenchymal remodeling with solitary nonspecific intraparenchymal nodule
- Intermittent, subjectively benign / reactive jejunocolic lymph nodes - not consistent with inflammatory or neoplastic criteria
- Heterogeneous pancreas - suspect age-related pancreatic changes, likely incidental

WEIGHT

10 lbs.

INTERPRETED BY

R. McKenzie Daniel,
DVM, DABVP
(Canine and Feline)

INTERPRETATION OF THE FINDINGS & FURTHER RECOMMENDATIONS

No indication for cardiac medications was evident.

The hepatic nodule, although nonspecific, may indicate a focal area of hematopoiesis or nodular to regenerative hyperplasia and not overtly suggestive of neoplastic criteria. Sonographic monitoring of the hepatic nodule for evidence of progression +/- ultrasound-guided FNA, if hepatic enzyme elevations are noted, would be appropriate.

IMAGING PERFORMED BY

Kim Liedberg

HOSPITAL NAME

SVS Imaging WI

REFERRING VET

Dr Klein, Pet Care in Motion

The potential for low-grade structurally insignificant inflammatory enteropathy or low-grade to chronic pancreatitis could be considered if previous or future history of gastrointestinal signs or weight loss is noted.

INVOICE

13097

DATE

1/18/22



PATIENT

Fritz Dostoevsky

SPECIES

Feline

BREED

DSH

SEX

MN

AGE

15 years

WEIGHT

10 lbs.

INTERPRETED BY

R. McKenzie Daniel,
DVM, DABVP
(Canine and Feline)

IMAGING PERFORMED BY

Kim Liedberg

HOSPITAL NAME

SVS Imaging WI

REFERRING VET

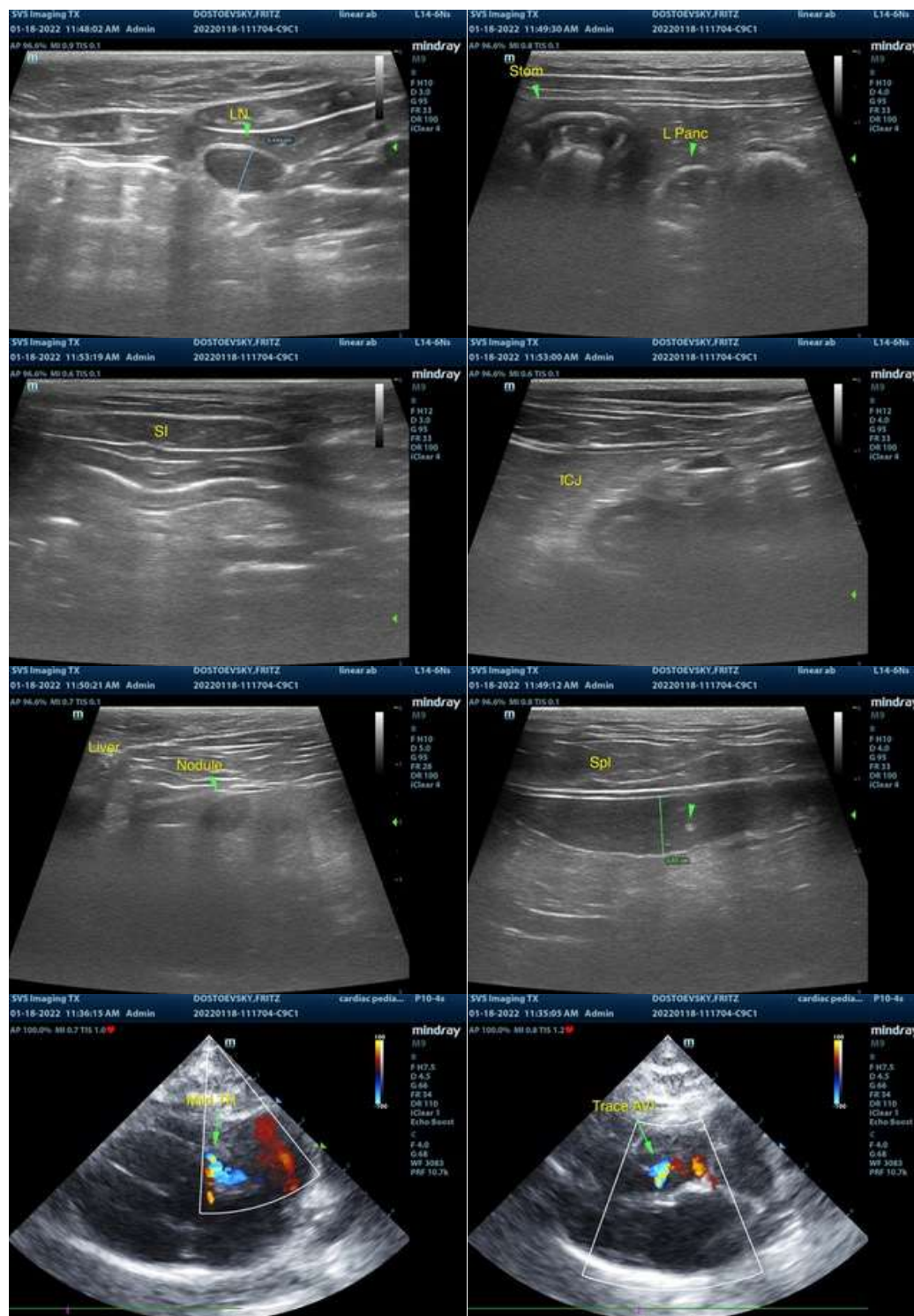Dr Klein, Pet Care in Motion

INVOICE

13097

DATE

1/18/22





PATIENT

Fritz Dostoevsky

SPECIES

Feline

BREED

DSH

SEX

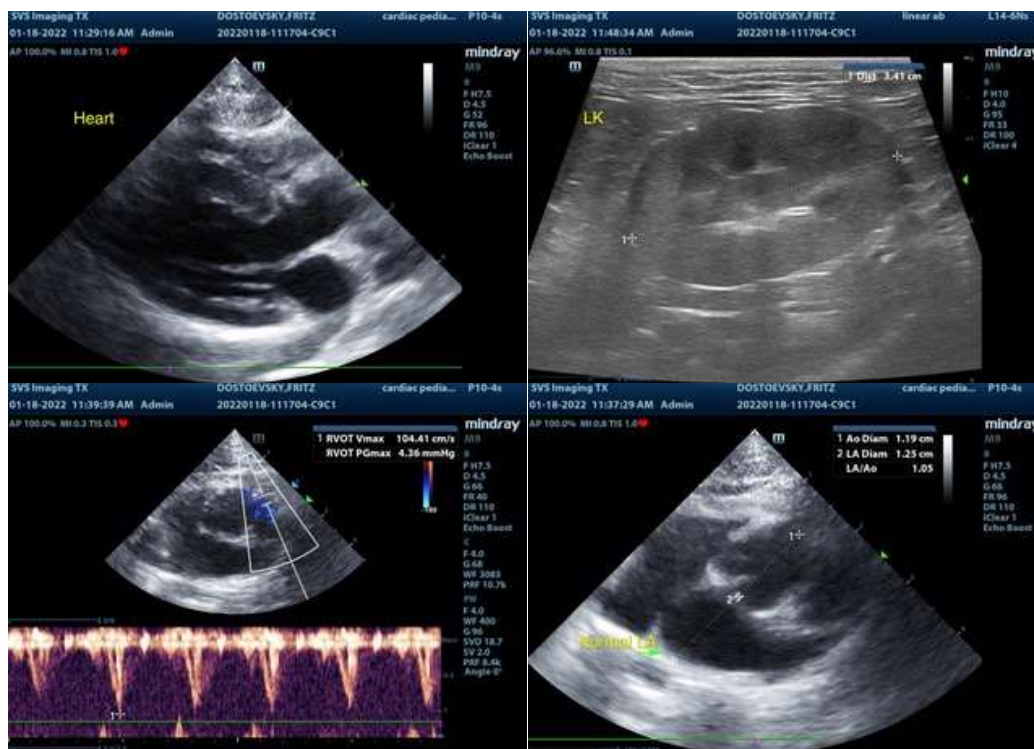
MN

AGE

15 years

WEIGHT

10 lbs.



INTERPRETED BY

R. McKenzie Daniel,
DVM, DABVP
(Canine and Feline)

IMAGING PERFORMED BY

Kim Liedberg

HOSPITAL NAME

SVS Imaging WI

REFERRING VET

Dr Klein, Pet Care in
Motion

INVOICE

13097

DATE

1/18/22

The information and recommendations provided are based on the images presented by the referring veterinarian. No evaluation can be communicated regarding pathology that was not visible in the image/video clips provided.

Thank you for this referral. If the clinical or image interpretation does not parallel your findings or if I can be of any further assistance please contact me.

R. McKenzie Daniel, DVM, DABVP (Canine / Feline Practice)

info@SonoPath.com