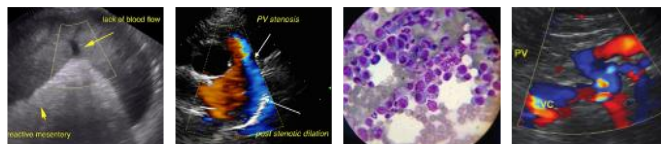




PATIENT	PRESENTING CLINICAL SIGNS
Alvin Riley	Anal gland mass bilaterally. PU/PD, Hx of splenectomy and cystotomy
SPECIES	Abnormal PE/Chem/CBC/UA Results: USG:1.011, urine protein 3+, UPC ratio: 3.3, ALT: 153, alk: 475, GGT: 37, Ca: 12.1
Canine	ULTRASONOGRAPHIC EXAMINATION OF THE ABDOMEN
BREED	Urinary System
Corgi	The urinary bladder, trigone, cystourethral junction, and visible pelvic urethra to a depth of 3 cm exhibited normal thickness and tone. Possible discrete cystitis pattern present in the ventroapical bladder. Anechoic urine was present in the lumen with a solitary dependent calculus measuring 0.9 cm in diameter along with minor non-dependent particulate sediment. The ureteral papillae were normal. The ureters were not visible which is normal. No evidence of inflammatory or neoplastic changes were noted.
SEX	
MN	
AGE	Normal size and margination were present in the kidneys. A normal 1:3 cortex / medulla ratio was maintained. The medulla and cortices were uniform in texture with some increased echogenicity and mild loss of corticomedullary symmetry and definition expected for the age of the patient. No evidence of pelvic dilation was present. Pinpoint areas of medullary mineral and small cortical cysts were present. The left kidney measured 5.5 cm in length. The right kidney measured 5.8 cm in length.
13yr	
WEIGHT	The area of the aortic trifurcation was free of pathology.
31lb	The area of the iliac trifurcation was free of pathology including no evidence of medial, iliac or sublumbar lymphadenopathy.
INTERPRETED BY	The area of the residual prostate appeared normal and free of pathology measuring 1.0 cm in diameter.
R. McKenzie Daniel, DVM, DABVP (Canine and Feline)	Adrenal Glands
IMAGING PERFORMED BY	The bilateral adrenal glands exhibited borderline prominent size. Mild non-homogenous to indistinct nodule parenchyma and mild capsule asymmetry was present without suspicion for overt neoplasia. The left adrenal gland measured 2.1 cm length and 0.93 cm width in the caudal pole. The right adrenal gland measured 2.2 cm length and 0.74 cm width in the caudal pole.
Dr. Rodriguez	Spleen
HOSPITAL NAME	The spleen was not visualized secondary to previous splenectomy.
Foxfield Veterinary Services	Liver/Gallbladder
REFERRING VET	The liver exhibited generalized enlargement with mild non-uniform to non-homogenous parenchyma. A moderately sized to expansive symmetrical non-homogenous echogenic to cystic mass appearing to occupy the caudal aspect of the mid liver was present measuring ~ 6.3 cm in diameter. The hepatic and portal vasculature were normal in appearance without signs of congestion. The gallbladder was non-distended in size with thin walls and primarily anechoic luminal content with mild echogenic luminal debris. The cystic and common bile ducts were normal.
Dr. Rodriguez	Gastrointestinal
INVOICE	The stomach presented intact wall layering with a normal wall layer ratio. The lumen of the stomach contained mild focally shadowing ingesta/chyme with no signs of ileus, obstruction or foreign material.
12699ag	
DATE	
01/16/2023	



PATIENT

Alvin Riley

The small intestine presented intact wall layering with 1:3 muscularis/mucosa ratio. The lumen of the small intestine was empty with no signs of ileus, obstruction or foreign material.

Normal visible colon wall layers were present with apparent formed feces in lumen.

SPECIES

Canine

Pancreas

The pancreas was normal in size and contour with isoechoic to heterogeneous parenchyma compared to adjacent omentum, likely consistent with age related changes and considered incidental. No signs of active inflammation or neoplasia.

BREED

Corgi

Free Abdomen

No omental masses, overt lymphadenopathy or peritoneal effusion was present.

SEX

MN

ULTRASONOGRAPHIC FINDINGS

- Small dependent cystic calculus with non-dependent particulate sediment
- Bilateral non-specific chronic renal changes with pinpoint medullary mineral and cortical cysts
- Hepatomegaly with parenchymal remodeling, moderately sized expansive non-homogenous to cystic caudal liver mass
- Minor gallbladder debris (non-mucocele)
- Bilateral mild irregular to nodular adrenal glands

AGE

13yr

WEIGHT

31lb

INTERPRETATION OF THE FINDINGS & FURTHER RECOMMENDATIONS

No evidence of medial iliac or sublumbar lymphatic metastasis was present. A urine C/S suggested to assess for underlying UTI.

Assuming normal clotting status and using a 25g needle, a liver mass and hepatic parenchyma FNA for screening cytology is warranted for further assessment. Benign vs metastatic etiologies for the liver mass possible.

The adrenal glands may indicate functional vs non-functional adenomatous changes or benign hyperplasia although technically the possibility of emerging primary vs metastatic neoplasia cannot be excluded. A full adrenal work up and a screening BP is advised to assess for evidence of hypertension which may allude to emerging adrenal neoplastic criteria i.e. pheochromocytoma.

INTERPRETED BY

R. McKenzie Daniel,
DVM, DABVP
(Canine and Feline)

IMAGING

PERFORMED BY

Dr. Rodriguez

HOSPITAL NAME

Foxfield Veterinary
Services

REFERRING VET

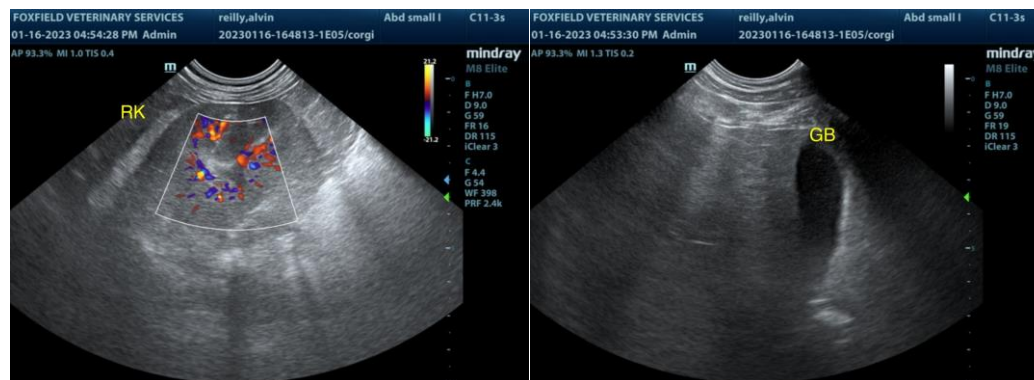Dr. Rodriguez

INVOICE

12699ag

DATE

01/16/2023





PATIENT

Alvin Riley

SPECIES

Canine

BREED

Corgi

SEX

MN

AGE

13yr

WEIGHT

31lb

INTERPRETED BY

R. McKenzie Daniel,
DVM, DABVP
(Canine and Feline)

IMAGING PERFORMED BY

Dr. Rodriguez

HOSPITAL NAME

Foxfield Veterinary
Services

REFERRING VET

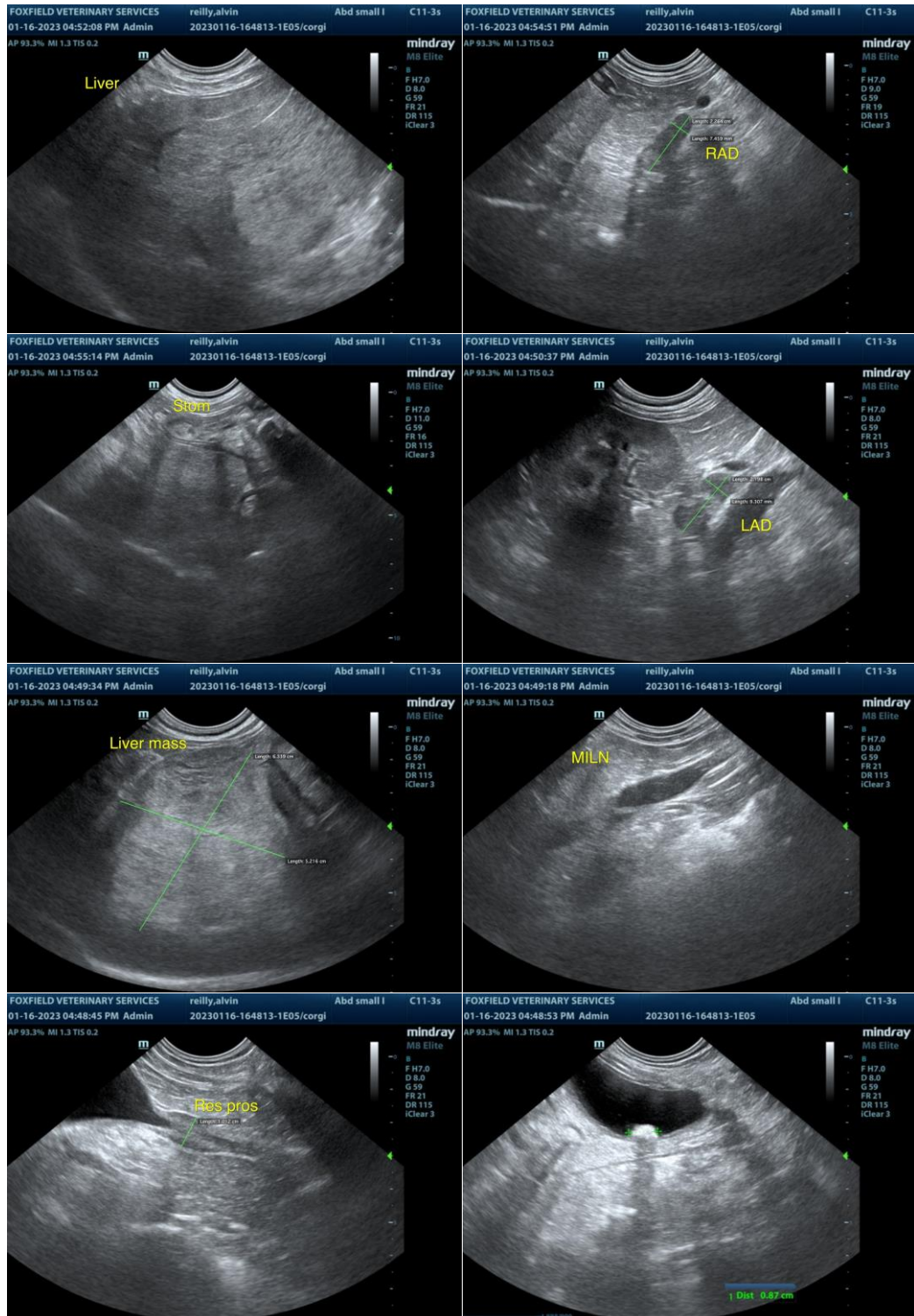
Dr. Rodriguez

INVOICE

12699ag

DATE

01/16/2023



The information and recommendations provided are based on the images presented by the referring veterinarian/sonographer. No evaluation can be communicated regarding pathology that was not visible in the image/video clips provided.

Thank you for this referral. If the clinical or image interpretation does not parallel your findings or if I can be of any further assistance, please contact me.



PATIENT

Alvin Riley

R. McKenzie Daniel, DVM, DABVP (Canine/Feline Practice)
mac.daniel@sonopath.com

SPECIES

Canine

BREED

Corgi

SEX

MN

AGE

13yr

WEIGHT

31lb

INTERPRETED BY

R. McKenzie Daniel,
DVM, DABVP
(Canine and Feline)

**IMAGING
PERFORMED BY**

Dr. Rodriguez

HOSPITAL NAME

Foxfield Veterinary
Services

REFERRING VET

Dr. Rodriguez

INVOICE

12699ag

DATE

01/16/2023