



PATIENT

Laila Vincent

SPECIES

Canine

BREED

Boxer

SEX

Female Spayed

AGE

8y

WEIGHT

77 lbs

INTERPRETED BY

R. McKenzie Daniel,
DVM, DABVP
(Canine and Feline)

IMAGING PERFORMED BY

Amanda Hockenbrock

HOSPITAL NAME

Lewisburg VH

REFERRING VET

Dr. Jamie Vincent

INVOICE

13080

DATE

1/14/26

PRESENTING CLINICAL SIGNS

History: Doctor (Staff) Pet for routine abdominal scan

Abnormal PE/Chem/CBC/UA Results: Borderline Thyroid on Mich T4, borderline Cushing's Ultrasound in April 2025 was WNL

ULTRASONOGRAPHIC EXAMINATION OF THE ABDOMEN

Urinary System

The urinary bladder, trigone, cystourethral junction, and visible pelvic urethra to a depth of 4.0 cm exhibited normal thickness and tone. Anechoic urine was present in the lumen with no uroliths or sediment. The ureteral papillae were normal. The ureters were not visible which is normal. No evidence of inflammatory or neoplastic changes were noted.

The area of the aortic trifurcation was free of pathology.

Normal size and margination was present in the kidneys. A normal 1:3 cortex / medulla ratio and normal corticomedullary definition were maintained. The echogenicity of the cortex was similar to or slightly less than normal liver parenchyma while the medulla echogenicity was hypoechoic to the cortex with no evidence of pelvic dilation. The left kidney measured 6.4 cm in length. The right kidney measured 7.1 cm in length.

Adrenal Glands

The left and right adrenal glands were not definitively visualized.

Spleen

The spleen exhibited a finely textured and homogenous parenchyma which was hyperechoic to the liver and renal cortical parenchyma. The capsule was smooth and regular without apparent expansion. The splenic vasculature at the hilus was normal in volume with no evidence of congestion or thrombosis. Acute to chronic inflammatory, neoplastic, or benign parenchyma changes were not noted.

Liver

The liver was subjectively normal in size, structure, and contour. The liver parenchyma was uniform and hypoechoic to the spleen with a mild coarse echotexture. The hepatic and portal vasculature were normal in appearance without signs of congestion. The gallbladder was non-distended in size with thin walls and primarily anechoic luminal content. The cystic and common bile ducts were normal.

Gastrointestinal

The visible gastric walls exhibited intact wall layering without mural pathology or hypertrophy. The stomach contained mild, progressively shadowing ingesta without overt evidence of obstruction to pyloric outflow.

The small intestine presented intact wall layering with 1:3 muscularis/mucosa ratio. Segmental, generally mild, non-shadowing ingesta to the level of the colon.

Normal visible colon wall layers were present with apparent formed feces in lumen.



PATIENT

Laila Vincent

SPECIES

Canine

BREED

Boxer

SEX

Female Spayed

AGE

8y

WEIGHT

77 lbs

INTERPRETED BY

R. McKenzie Daniel,
DVM, DABVP
(Canine and Feline)

IMAGING PERFORMED BY

Amanda Hockenbrock

HOSPITAL NAME

Lewisburg VH

REFERRING VET

Dr. Jamie Vincent

INVOICE

13080

DATE

1/14/26

Pancreas

The parenchyma of the left limb, body and right limb of the pancreas presented isoechoic to the adjacent omental fat. A normal curvilinear capsule contour of the pancreas was present. The visible pancreatic duct was normal. No signs of active inflammation or neoplastic disease was evident.

Free Abdomen

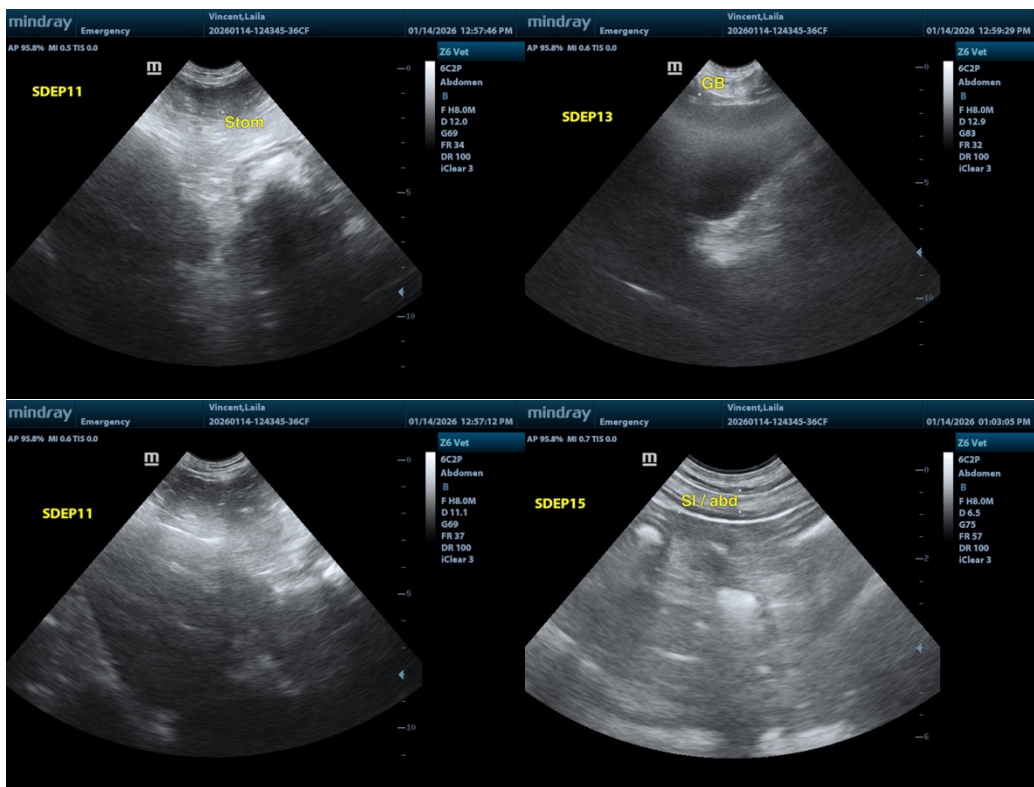
No overt lymphadenopathy or peritoneal effusion was present.

ULTRASONOGRAPHIC FINDINGS

- Sonographically unremarkable abdomen with gastrointestinal ingesta

INTERPRETATION OF THE FINDINGS & FURTHER RECOMMENDATIONS

No evidence of visceral pathology present. Correlation with most recent meal ingestion is recommended as the gastrointestinal ingesta is most consistent with food echogenicity.





PATIENT

Laila Vincent

SPECIES

Canine

BREED

Boxer

SEX

Female Spayed

AGE

8y

WEIGHT

77 lbs

INTERPRETED BY

R. McKenzie Daniel,
DVM, DABVP
(Canine and Feline)

IMAGING PERFORMED BY

Amanda Hockenbrock

HOSPITAL NAME

Lewisburg VH

REFERRING VET

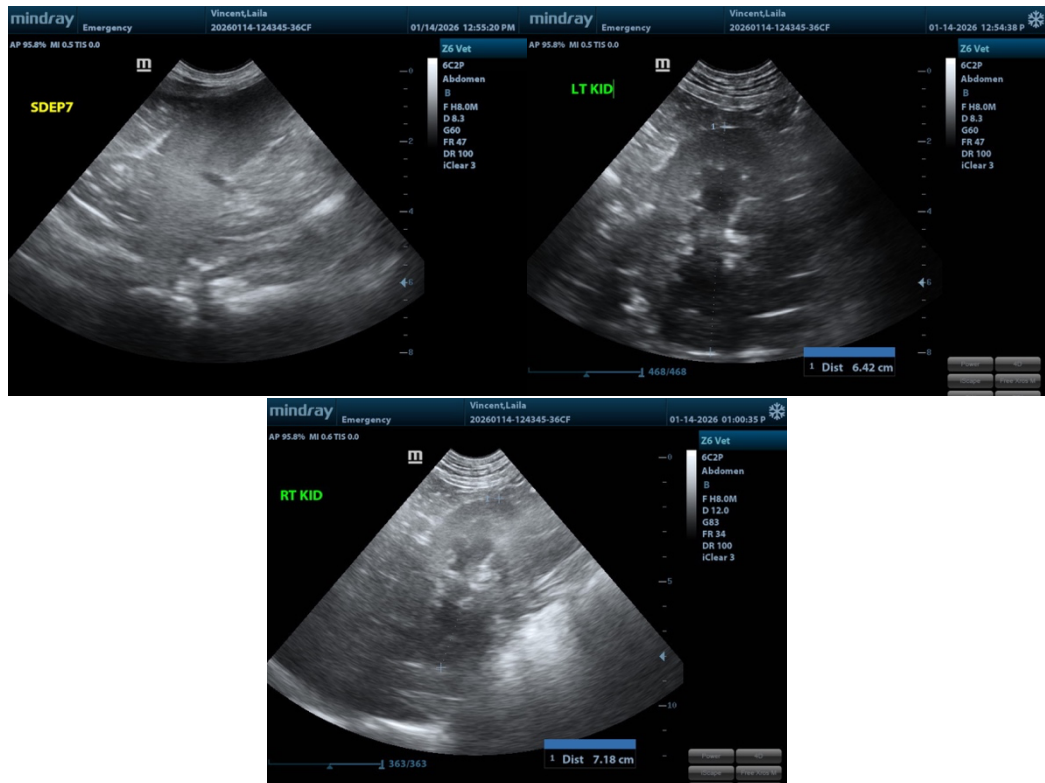
Dr. Jamie Vincent

INVOICE

13080

DATE

1/14/26



The information and recommendations provided are based on the images presented by the referring veterinarian/sonographer. No evaluation can be communicated regarding pathology that was not visible in the image/video clips provided.

Thank you for this referral. If the clinical or image interpretation does not parallel your findings or if I can be of any further assistance, please contact me.

R. McKenzie Daniel, DVM, DABVP (Canine / Feline Practice)

info@sonopath.com