



## PATIENT

Limited study of the urinary system only.

Jade Welsh

## PRESENTING CLINICAL SIGNS

Pet is having a history of straining while urinating, accidents in the house and blood in urine going on for a few days.

## SPECIES

Feline

## LIMITED ULTRASONOGRAPHIC EXAMINATION OF THE ABDOMEN

## BREED

### Urinary System

DSH

The urinary bladder was normal in size and tone. The trigone, cystourethral junction, and visible pelvic urethra exhibited normal tone to a depth of 3 cm. Mild primarily uniform thickened ventral and ventroapical urinary bladder wall exhibiting symmetrical luminal surface contour was present.

## SEX

FS

Ventroapical urinary bladder wall measured 0.40 cm in width. Within the ventroapical urinary bladder wall a small anechoic to hypoechoic structure was present measuring ~ 0.67 cm diameter which may indicate ventroapical mural cyst or nodule. A solitary dependent lumen calculus was present measuring 0.66 cm in diameter.

## AGE

10yr

Normal size and margination were present in the kidneys. A normal 1:3 cortex / medulla ratio and normal corticomedullary definition were maintained. The echogenicity of the cortex was similar to or slightly less than normal liver parenchyma while the medulla echogenicity was hypoechoic to the cortex with no evidence of pelvic dilation. The left kidney measured 4.1 cm in length. The right kidney measured 4.1 cm in length.

## WEIGHT

9.6

## ULTRASONOGRAPHIC FINDINGS

### Primary

- Cystic calculus with cystitis pattern
- Unspecified ventroapical mural cyst vs nodule
- Normal bilateral kidneys

## INTERPRETED BY

R. McKenzie Daniel,  
DVM, DABVP  
(Canine and Feline)

## INTERPRETATION OF THE FINDINGS & FURTHER RECOMMENDATIONS

## IMAGING PERFORMED BY

Marco Lichfield

Cystotomy with calculus analysis and biopsy of the urinary bladder wall in the area of the ventroapical mural cyst vs nodule with concurrent urine C/S on sterile urine sample is warranted. Empirical therapy for cystitis including urinary diet with clinical and sonographic monitoring would be more conservative.

## HOSPITAL NAME

Sova Animal Hospital

## REFERRING VET

Dr Sova

## INVOICE

23561

## DATE

01/14/2026



**PATIENT**

Jade Welsh

**SPECIES**

Feline

**BREED**

DSH

**SEX**

FS

**AGE**

10yr

**WEIGHT**

9.6

**INTERPRETED BY**

R. McKenzie Daniel,  
DVM, DABVP  
(Canine and Feline)

**IMAGING PERFORMED BY**

Marco Lichfield

**HOSPITAL NAME**

Sova Animal Hospital

**REFERRING VET**

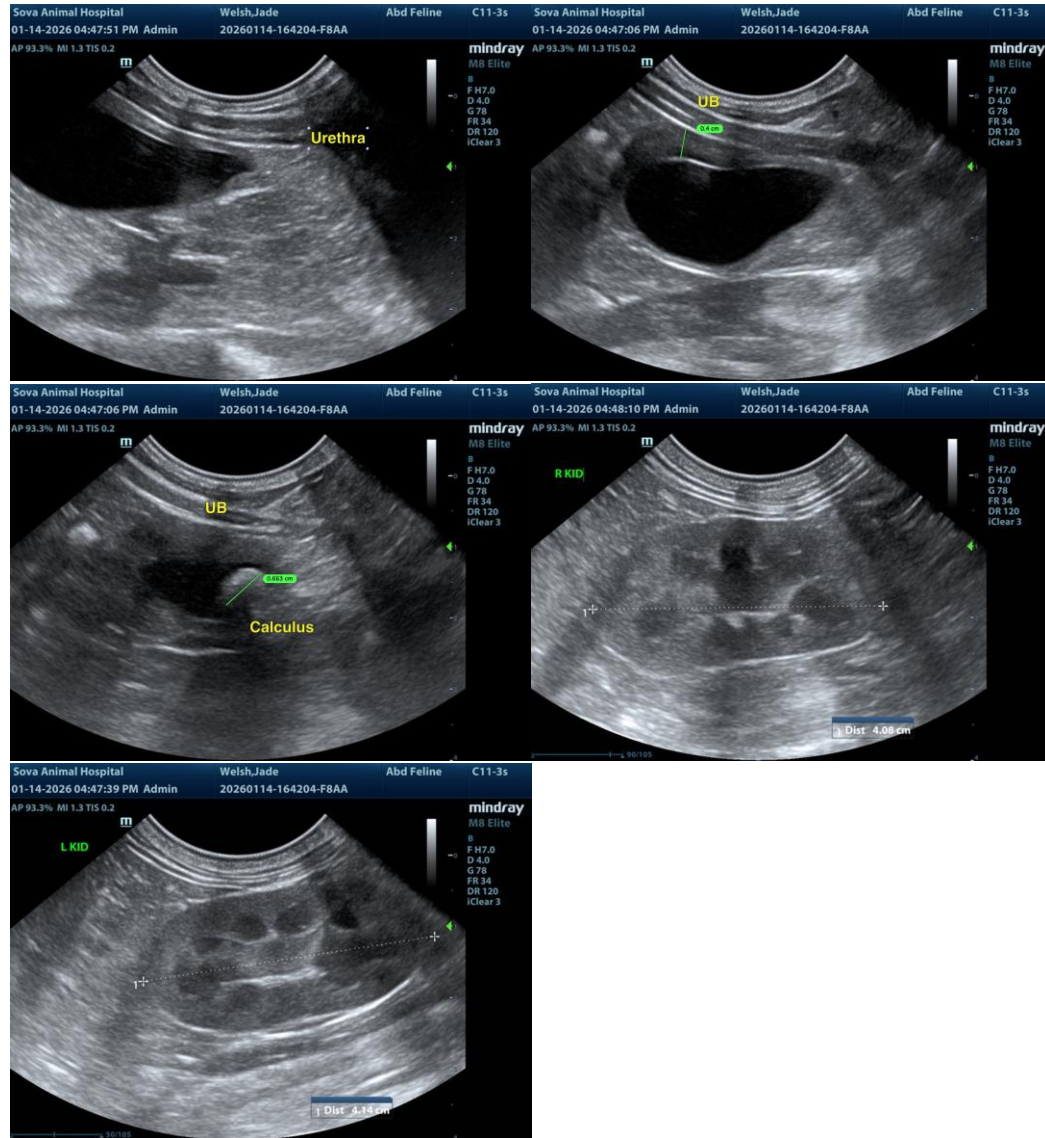
Dr Sova

**INVOICE**

23561

**DATE**

01/14/2026



The information and recommendations provided are based on the images presented by the referring veterinarian/sonographer. No evaluation can be communicated regarding pathology that was not visible in the image/video clips provided.

Thank you for this referral. If the clinical or image interpretation does not parallel your findings or if I can be of any further assistance, please contact me.

R. McKenzie Daniel, DVM, DABVP (Canine/Feline Practice)  
[info@sonopath.com](mailto:info@sonopath.com)