



PATIENT

Choco Yi

PRESENTING CLINICAL SIGNS

Follow up from ER- P was diagnosed with CHF Meds- furo and clopidogrel

SPECIES

Feline

BREED

Persian

SEX

Spayed Female

AGE

6 Years 9 Months

WEIGHT

8.6 pounds

ULTRASONOGRAPHIC EXAMINATION OF THE HEART

FELINE CARDIAC PARAMETERS	BODY WEIGHT (lbs)	HR (BPM)	IVSd (cm)	LVIDd (cm)	LVWd (cm)	FS (%)	EF (%)
NORMAL PARAMETER	-----	150-240	0.3-0.6	1.0-2.1	0.25-0.6	35-67	80-100
PATIENT	8.6	NM	0.45	1.3	0.46	48	82
FELINE CARDIAC PARAMETERS	LA/AO (M-mode)	LA/AO HEART BASE (Sisson)	LAD LA MAX 4 Chamber		LVOT VEL. (m/s)	RVOT VEL. (m/s)	IVRT (m/)
NORMAL PARAMETER	<1.5	1.6	0.7-1.7		<1.6	<1.3	40-60
PATIENT	--	1.27	1.3		1.0	0.7	NM
Adapted from June Boon, Veterinary Echocardiography, 1998 Sisson D et al. JVIM 1991; 5: 232, Jacobs et al. Am J Vet Res 1985; 46:1705							

INTERPRETED BY

R. McKenzie Daniel,
DVM, DABVP (Canine / Feline Practice)

IMAGING PERFORMED BY

Kerri Becker

HOSPITAL NAME

Animal Paradise Hospital

REFERRING VET

Dr. Elshafie

INVOICE

13158

DATE

1/14/26

Cardiac Presentation

The echocardiogram in this patient demonstrated normal **left atrial** dimension based on 2 separate LA measurements. The cranial and caudal **mitral** valve leaflets presented normal linear structure and kinetics. The **left ventricle** presented normal thicknesses with linear contour and was not dilated nor restricted. The **myocardium** presented normal echogenicity without subjective evidence of significant fibrotic or ischemic disease. **Contractility** of the ventricular walls was adequate and in normal range for this patient evidenced by the fractional shortening measurement and subjective evaluation of the different regions and angles of the myocardium. The **left ventricular outflow** tract demonstrated normal laminar flow and subjective structural integrity. The **right atrium** and auricle revealed normal size, structure and content. No evidence of masses was noted or chamber overload. **Tricuspid** valvular assessment demonstrated adequate linear morphology and kinetics. The **right ventricle** was of normal size (1/3 diameter of LV), chordae structure, myocardial echogenicity and thickness. **Pulmonic** tract assessment revealed normal valve structure, laminar flow, and diameter (approx. 1:1 pa/ao ratio). No visible **pericardial** or free pleura fluid was noted or extra cardiac pathology in the visible planes. The cranial **mediastinum** and **pericardial** regions were free of masses in the visible window.

ULTRASONOGRAPHIC FINDINGS

- Normal cardiac structure/function.

INTERPRETATION OF THE FINDINGS & FURTHER RECOMMENDATIONS

No evidence of clinical issues such as left or right heart chamber enlargement, LV systolic dysfunction, HCM criteria or other structural cardiomyopathy without evidence of congestive heart failure. No



PATIENT

Choco Yi

indication for cardiac medications. Correlation with three view chest radiographs for evidence of pulmonary disease if clinical or respiratory signs are present in this patient.

SPECIES

Feline

BREED

Persian

SEX

Spayed Female

AGE

6 Years 9 Months

WEIGHT

8.6 pounds

INTERPRETED BY

R. McKenzie Daniel,
 DVM, DABVP (Canine
 / Feline Practice)

IMAGING PERFORMED BY

Kerri Becker

HOSPITAL NAME

Animal Paradise
 Hospital

REFERRING VET

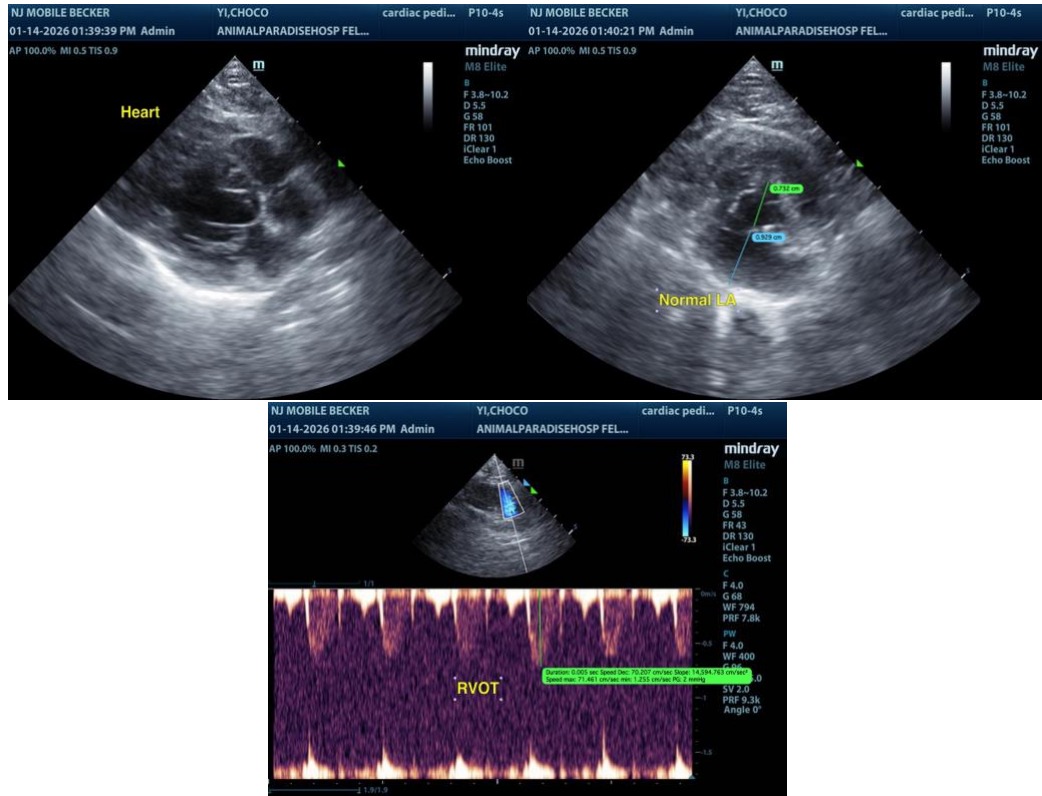
Dr. Elshafie

INVOICE

13158

DATE

1/14/26



The information and recommendations provided are based on the images presented by the referring veterinarian/sonographer. No evaluation can be communicated regarding pathology that was not visible in the image/video clips provided.

Thank you for this referral. If the clinical or image interpretation does not parallel your findings or if I can be of any further assistance, please contact me.

R. McKenzie Daniel, DVM, DABVP (Canine / Feline Practice)

info@SonoPath.com