

**PATIENT**

Abbey Lemon

**SPECIES**

Canine

**BREED**

Lab Mix

**SEX**

FS

**AGE**

13 years

**WEIGHT**

83 lbs.

**INTERPRETED BY**R. McKenzie Daniel,  
DVM, DABVP (Canine  
and Feline)**IMAGING  
PERFORMED BY**

Amy Mayhew LVT

**HOSPITAL NAME**

SVS Imaging MI

**REFERRING VET**

Family Pet Practice

**INVOICE**

13074

**DATE**

1/14/22

**PRESENTING CLINICAL SIGNS**

Recently exhibited vestibular signs, ataxia, weakness. Decreased appetite. No GI signs.

Abnormal PE/Chem/CBC/UA Results: Low T4 otherwise NSF Previous abdominal ultrasound mildly hyperechoic/coarse liver. Mildly hyper echoic right limb pancreas. Otherwise NSF.

**ULTRASONOGRAPHIC EXAMINATION OF THE ABDOMEN****Urinary System**

The urinary bladder, trigone, cystourethral junction, and visible pelvic urethra to a depth of 3 cm exhibited normal thickness and tone. Anechoic urine was present in the lumen with no uroliths or sediment. The ureteral papillae were normal. The ureters were not visible which is normal. No evidence of inflammatory or neoplastic changes was noted.

The area of the aortic trifurcation was free of pathology.

Normal size and margination were present in the kidneys. A normal 1:3 cortex / medulla ratio was maintained. The medulla and cortices were uniform in texture with some increased echogenicity and mild loss of corticomedullary symmetry and definition expected for the age of the patient. No evidence of pelvic dilation was present. The left kidney measured 6.6 cm in length. The right kidney measured 7.0 cm in length.

**Adrenal Glands**

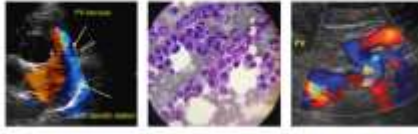
The left adrenal gland was uniform in size and contour with a uniformly hypoechoic parenchyma. The left adrenal gland measured 0.66 cm width at the caudal pole and 0.68 cm width at the cranial pole. The right adrenal gland was uniform in size and contour with a uniformly hypoechoic parenchyma. The right adrenal gland measured 0.60 cm width at the caudal pole and 0.83 cm width at the cranial pole.

**Spleen**

The spleen exhibited primarily finely textured parenchyma which was hyperechoic to the liver and renal cortical parenchyma. Mild generalized parenchyma heterogeneity was present without evidence of nodular changes. The capsule was smooth and regular without apparent expansion. The splenic vasculature at the hilus was normal in volume with no evidence of congestion or thrombosis. The parenchymal heterogeneity is likely consistent with benign changes such as extramedullary hematopoiesis or age-related remodeling with minor potential for inflammatory or neoplastic disease.

**Liver/ Gallbladder**

The liver was subjectively normal in size, structure, and contour. The liver parenchyma was mildly nonuniform and hypoechoic to the spleen with a moderate coarse echotexture and subjective mild to benign parenchymal remodeling. The hepatic and portal vasculature were normal in appearance without signs of congestion. The gallbladder was non-distended in size with mild gallbladder debris. The cystic and common bile ducts were normal.

**PATIENT**

Abbey Lemon

**SPECIES**

Canine

**BREED**

Lab Mix

**SEX**

FS

**AGE**

13 years

**WEIGHT**

83 lbs.

**INTERPRETED BY**R. McKenzie Daniel,  
DVM, DABVP (Canine  
and Feline)**IMAGING  
PERFORMED BY**

Amy Mayhew LVT

**HOSPITAL NAME**

SVS Imaging MI

**REFERRING VET**

Family Pet Practice

**INVOICE**

13074

**DATE**

1/14/22

***Gastrointestinal***

The stomach presented intact wall layering with a normal wall layer ratio. The lumen of the stomach was empty with no signs of ileus, obstruction, or foreign material.

The small intestine presented intact wall layering with 1:3 muscularis/mucosa ratio. The lumen of the small intestine was empty with no signs of ileus, obstruction, or foreign material.

Normal visible colon wall layers were present with apparent formed feces in lumen.

***Pancreas***

The pancreas was normal in size and contour with isoechoic to heterogeneous parenchyma compared to adjacent omentum. No signs of active inflammation or neoplasia.

***Free Abdomen***

No omental masses, lymphadenopathy or peritoneal effusion were present.

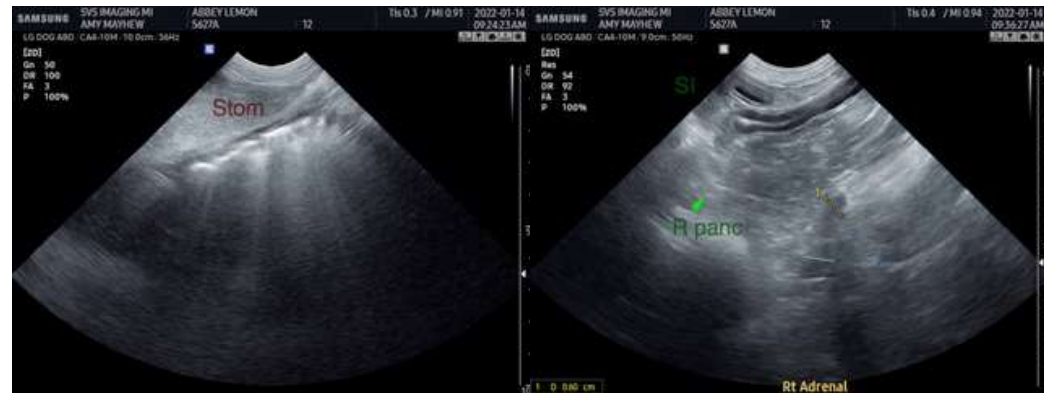**ULTRASONOGRAPHIC FINDINGS*****Primary Findings***

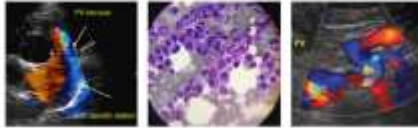
- Mild age-related kidneys
- Minor hepatic parenchymal remodeling - subjectively benign
- Mild gallbladder debris - non-mucocele, incidental
- Heterogeneous pancreas - probable age-related pancreatic changes and considered incidental, minor potential for remodeling owing to previous Inflammatory episode or low-grade to chronic pancreatitis

**INTERPRETATION OF THE FINDINGS & FURTHER RECOMMENDATIONS**

Largely geriatric abdomen was noted without evidence of significant visceral pathology as an obvious cause of the patient's clinical signs.

Spec cPL could be considered to assess for potential concurrent evidence of low-grade to chronic pancreatitis. As-needed gastrointestinal support is recommended.





**PATIENT**

Abbey Lemon

**SPECIES**

Canine

**BREED**

Lab Mix

**SEX**

FS

**AGE**

13 years

**WEIGHT**

83 lbs.

**INTERPRETED BY**

R. McKenzie Daniel,  
DVM, DABVP (Canine  
and Feline)

**IMAGING  
PERFORMED BY**

Amy Mayhew LVT

**HOSPITAL NAME**

SVS Imaging MI

**REFERRING VET**

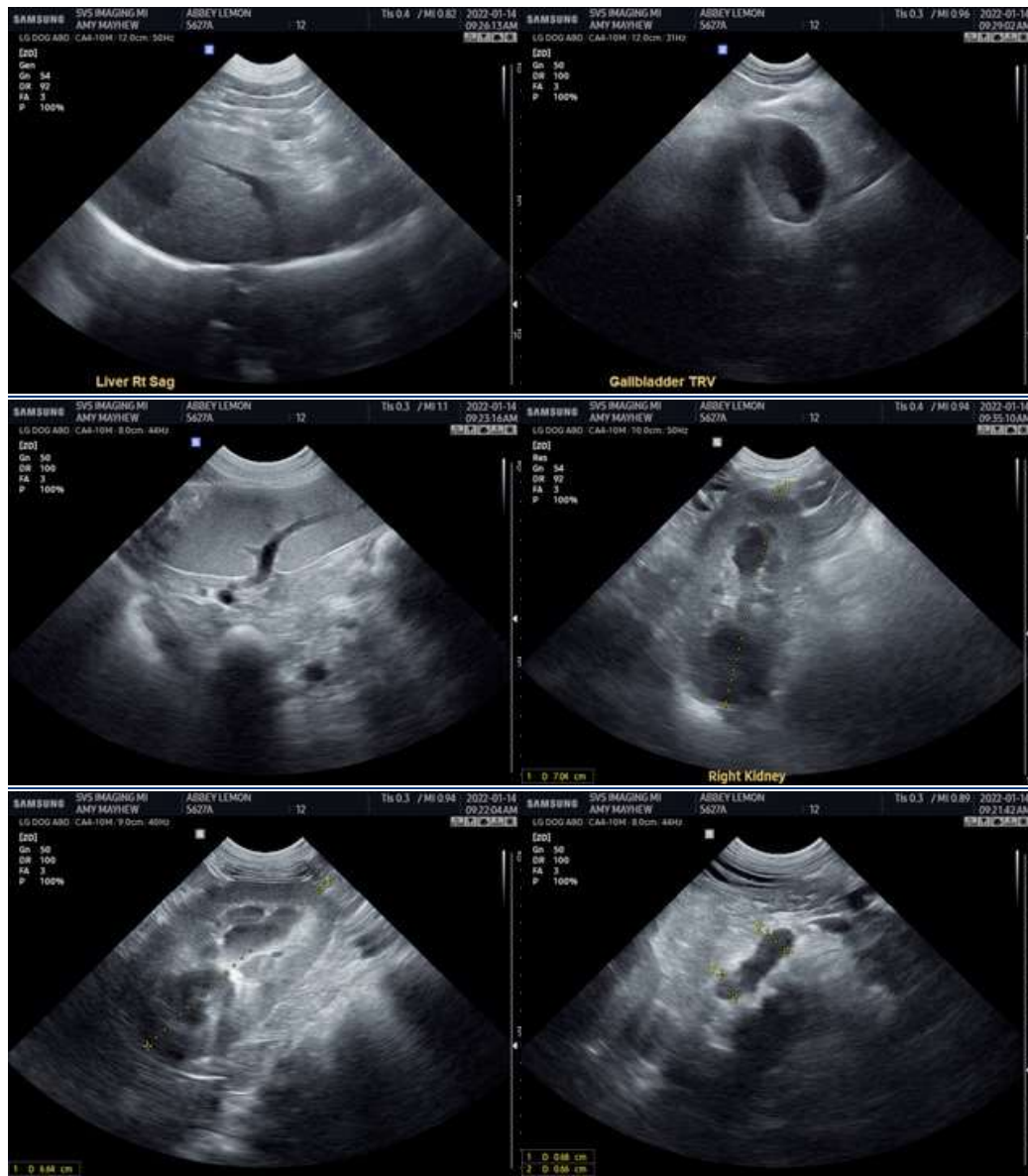
Family Pet Practice

**INVOICE**

13074

**DATE**

1/14/22



The information and recommendations provided are based on the images presented by the referring veterinarian. No evaluation can be communicated regarding pathology that was not visible in the image/video clips provided.

Thank you for this referral. If the clinical or image interpretation does not parallel your findings or if I can be of any further assistance please contact me.

**R. McKenzie Daniel, DVM, DABVP (Canine / Feline Practice)**  
info@SonoPath.com