



PATIENT

Elly Powell

SPECIES

Canine

BREED

Bulldog X

SEX

Female Spayed

AGE

11y

WEIGHT

47 lbs

INTERPRETED BY

R. McKenzie Daniel,
DVM, DABVP
(Canine and Feline)

IMAGING PERFORMED BY

Kelly Reschny

HOSPITAL NAME

Hillview VC

REFERRING VET

E Stevenson

INVOICE

13065

DATE

1/13/26

PRESENTING CLINICAL SIGNS

Limited study confined to the area of the right prescapular lymph node.

History: Lump on neck, dime sized, swelling went down, would bleed, then 1 month later would come back up the size of the dime, currently small. Scratching at it. Right neck: lump, about 1cm in diameter, under the skin, alopecic, pink and dried scab where the lump is. Right draining prescapular lymph node is swollen, rest of peripheral lymph nodes wnl (lymph node and MCT removal site were not swollen today) FNA performed on L/N today.

Abnormal PE/Chem/CBC/UA Results: cytology results attached

ULTRASONOGRAPHIC EXAMINATION OF THE PRESCAPULAR LYMPH NODE

Free Abdomen

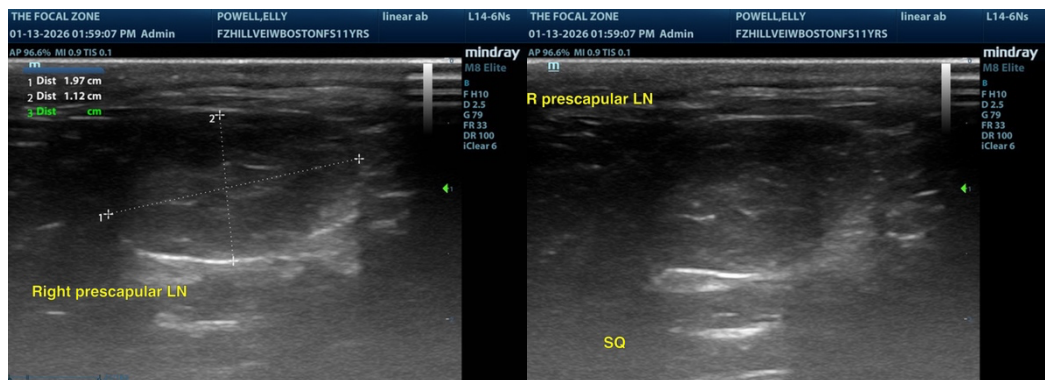
The right prescapular lymph node exhibited symmetrical contour and homogeneous non-mineralized parenchyma with mildly swollen appearing measuring 2.0 cm x 1.1 cm. No evidence of perilymphatic or regional subcutaneous inflammation or cellulitis.

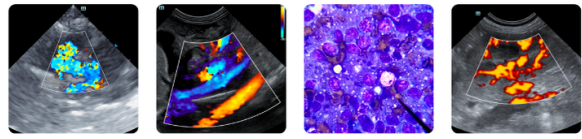
ULTRASONOGRAPHIC FINDINGS

- Mildly swollen yet symmetrical homogeneous right prescapular lymph node, no evidence of regional subcutaneous inflammation or cellulitis

INTERPRETATION OF THE FINDINGS & FURTHER RECOMMENDATIONS

The right prescapular lymph node is nonspecific with potential mild lymphatic hyperplasia, mild inflammation without evidence of associated regional cellulitis and sonographically without definitive evidence of neoplastic or metastatic criteria yet not definitively excluded given patient history. Correlation with pending lymph node cytology is recommended for further clarification with continued as needed gross and sonographic monitoring.





PATIENT

Elly Powell

The information and recommendations provided are based on the images presented by the referring veterinarian/sonographer. No evaluation can be communicated regarding pathology that was not visible in the image/video clips provided.

SPECIES

Canine

Thank you for this referral. If the clinical or image interpretation does not parallel your findings or if I can be of any further assistance, please contact me.

R. McKenzie Daniel, DVM, DABVP (Canine / Feline Practice)

BREED

Bulldog X

info@SonoPath.com

SEX

Female Spayed

AGE

11y

WEIGHT

47 lbs

INTERPRETED BY

R. McKenzie Daniel,
DVM, DABVP
(Canine and Feline)

IMAGING PERFORMED BY

Kelly Reschny

HOSPITAL NAME

Hillview VC

REFERRING VET

E Stevenson

INVOICE

13065

DATE

1/13/26