



PATIENT

Mia Villafane

SPECIES

Canine

BREED

Rottweiler

SEX

FS

AGE

8yr

WEIGHT

110lb

INTERPRETED BY

R. McKenzie Daniel,
DVM, DABVP
(Canine and Feline)

IMAGING PERFORMED BY

Julissa Diaz

HOSPITAL NAME

Centro Veterinario del Norte

REFERRING VET

Dr. Rivera

INVOICE

12666ag

DATE

01/11/2023

PRESENTING CLINICAL SIGNS

Patient had an abdominal u/s on last week of December and radiologist recommended treat with Clavamox high dose for 5 days, collect urine and submit to culture in addition of repeating u/s of bladder with doppler. Dog still urinating with clots, but the color of urine has improved significantly. Now owner described that pet has incontinence.

LIMITED RECHECK ULTRASONOGRAPHIC EXAMINATION OF THE URINARY SYSTEM

Urinary System

The urinary bladder was mildly distended in size with normal tone. Previously noted mild polyploid lesions along the apical urinary bladder, an example measuring 0.88 cm in diameter were present. Persistent mildly non-homogenous non-mineralized soft tissue echo in the dependent urinary bladder lumen potentially adhered to the dorsoapical urinary bladder wall measuring ~3.7 cm in diameter was present. Power Doppler assessment of the dependent soft tissue echo did not overtly indicate vascularity with peripheral blood flow within the adjacent urinary bladder wall visualized. No evidence of mineralization associated with the soft tissue echo. Anechoic urine was present in the lumen with mild to moderate non-dependent sediment. The sediment may indicate cellular debris / protein, crystalline debris, lipid, or mucus. No overt pathology in the area of the trigone or urinary bladder neck.

ULTRASONOGRAPHIC FINDINGS

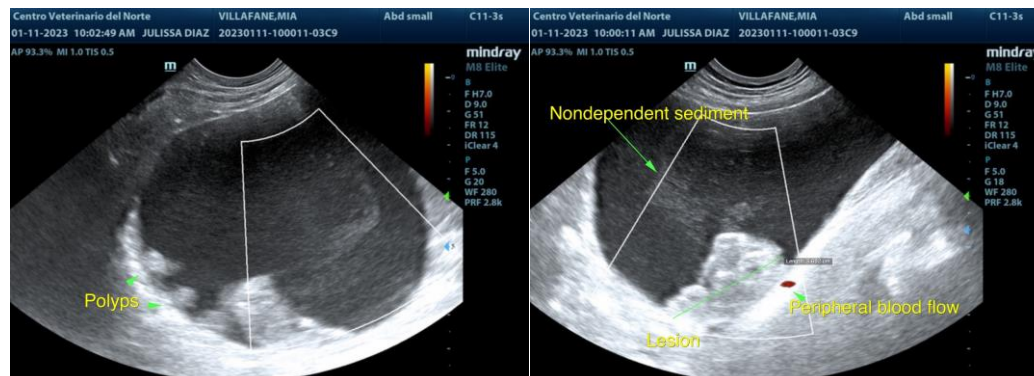
- Polyploid cystitis pattern with persistent dependent luminal soft tissue echo
- Moderate concurrent non-dependent particulate urinary bladder sediment

INTERPRETATION OF THE FINDINGS & FURTHER RECOMMENDATIONS

The soft tissue echo persistent in the bladder lumen potentially adhered to the adjacent bladder wall may indicate accumulated sediment, persistent blood clot, focal moderate cystitis while the possibility of urinary bladder tumor cannot be excluded. Subjectively the soft tissue echo appeared static in appearance without evidence of progression. The lack of definitive vascularity within the tissue may suggest a higher likelihood of accumulated sediment or persistent blood clot.

Screening BRAF assay recommended. Cystoscopy if available is likely ideal. Sonographic monitoring pending additional diagnostics would be reasonable. Recheck urine C/S 7 days post completion of antibiotics suggested.

Proin or phenylpropanolamine trial given the development of incontinence may be considered.





PATIENT

Mia Villafane

Begin forwarded message:

SPECIES

Canine

The information and recommendations provided are based on the images presented by the referring veterinarian/sonographer. No evaluation can be communicated regarding pathology that was not visible in the image/video clips provided.

BREED

Rottweiler

Thank you for this referral. If the clinical or image interpretation does not parallel your findings or if I can be of any further assistance, please contact me.

R. McKenzie Daniel, DVM, DABVP (Canine/Feline Practice)

mac.daniel@sonopath.com

SEX

FS

AGE

8yr

WEIGHT

110lb

INTERPRETED BY

R. McKenzie Daniel,
DVM, DABVP
(Canine and Feline)

**IMAGING
PERFORMED BY**

Julissa Diaz

HOSPITAL NAME

Centro Veterinario
del Norte

REFERRING VET

Dr. Rivera

INVOICE

12666ag

DATE

01/11/2023