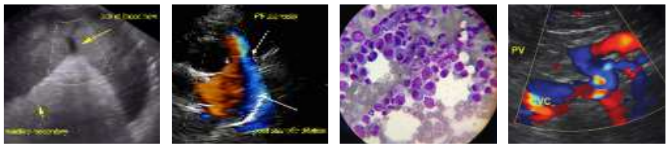

SonoPath.com™
1-800-838-4268 info@sonopath.com

PATIENT

Jessie Vaillant

SPECIES

Canine

BREED

Boston Terrier

SEX

Spayed Female

AGE

8 years

WEIGHT

26 lbs.

INTERPRETED BY

R. McKenzie Daniel, DVM, DABVP (Canine and Feline)

IMAGING PERFORMED BY

Dr. Eddleman

HOSPITAL NAME

Mt. Yonah AH

REFERRING VET

Rachel Eddleman

INVOICE

13043

DATE

1/12/22

PRESENTING CLINICAL SIGNS

mild elevations of liver values: GGT and tBili with normal ALT and ALP.

ULTRASONOGRAPHIC EXAMINATION OF THE ABDOMEN

Urinary System

The urinary bladder, trigone, cystourethral junction, and visible pelvic urethra to a depth of 3.0 cm exhibited normal thickness and tone. Anechoic urine was present in the lumen with no uroliths or sediment. The ureteral papillae were normal. The ureters were not visible which is normal. No evidence of inflammatory or neoplastic changes was noted.

The area of the aortic trifurcation was free of pathology.

Normal size and margination were present in the kidneys. A normal 1:3 cortex / medulla ratio and normal corticomedullary definition were maintained. The echogenicity of the cortex was similar to or slightly less than normal liver parenchyma while the medulla echogenicity was hypoechoic to the cortex with no evidence of pelvic dilation. Intermittent small cortical cysts were present in the right kidney.

Adrenal Glands

The bilateral adrenal glands were uniform in size and contour with a uniformly hypoechoic parenchyma. No evidence of adrenal hyperplasia or tumors was noted.

Spleen

The spleen was normal in size and contour exhibiting generalized mild splenic parenchyma heterogeneity with Intermittent, non-expansive, discreet, hypoechoic nodules.

Liver/ Gallbladder

The liver was subjectively normal in size, structure, and contour. The liver parenchyma was uniform and hypoechoic to the spleen with a mild coarse echotexture. The hepatic and portal vasculature were normal in appearance without signs of congestion. The gallbladder was non-distended in size with minor particulate gallbladder debris. The gallbladder walls were sonographically unremarkable without evidence of inflammatory changes. No evidence of peripheral gallbladder inflammation was noted. The cystic and common bile ducts were normal.

Gastrointestinal

The stomach presented intact wall layering with a normal wall layer ratio. The lumen of the stomach contained mild ingesta exhibiting mild distal acoustic shadowing.

The small intestine presented intact wall layering with 1:3 muscularis/mucosa ratio. The lumen of the small intestine was empty with no signs of ileus, obstruction, or foreign material.

Normal visible colon wall layers were present with apparent formed feces in lumen.

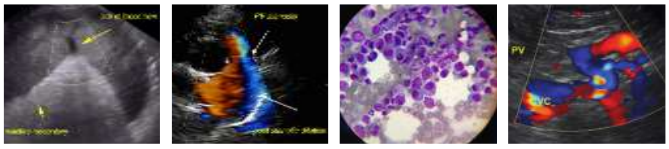

SonoPath.com™
1-800-838-4268 info@sonopath.com

PATIENT

Jessie Vaillant

SPECIES

Canine

BREED

Boston Terrier

SEX

Spayed Female

AGE

8 years

WEIGHT

26 lbs.

INTERPRETED BY

R. McKenzie Daniel, DVM, DABVP (Canine and Feline)

IMAGING PERFORMED BY

Dr. Eddleman

HOSPITAL NAME

Mt. Yonah AH

REFERRING VET

Rachel Eddleman

INVOICE

13043

DATE

1/12/22

Pancreas

The parenchyma of the left limb, body, and right limb of the pancreas presented isoechoic to the adjacent omental fat. A normal curvilinear capsule contour of the pancreas was present. The visible pancreatic duct was normal. No signs of active inflammation or neoplastic disease were evident.

Free Abdomen

No overt lymphadenopathy or peritoneal effusion was present.

ULTRASONOGRAPHIC FINDINGS

Primary Findings

- Mild splenic parenchyma heterogeneity with intermittent discreet hypoechoic nodules
- Sonographically unremarkable liver
- Minor gallbladder debris - non-mucocele
- Right kidney cortical cysts - incidental

INTERPRETATION OF THE FINDINGS & FURTHER RECOMMENDATIONS

The splenic parenchyma heterogeneity with discreet nodules, although nonspecific, are suggestive of probable hematopoiesis or areas of lymphoid hyperplasia. The potential for neoplastic criteria in the spleen Is considered unlikely. However, assuming normal clotting status, ultrasound-guided FNA of the spleen using a 25-gauge needle could be considered for screening cytology primarily to ensure only benign changes are present. Sonographic monitoring of the spleen for evidence of progressive parenchymal or nodular change would be a more conservative approach.

No evidence of hepatic or hepatobiliary pathology was noted. Continued monitoring of GGT and Total Bilirubin levels with potential for hepatosupportive medications including Ursodiol may be considered.

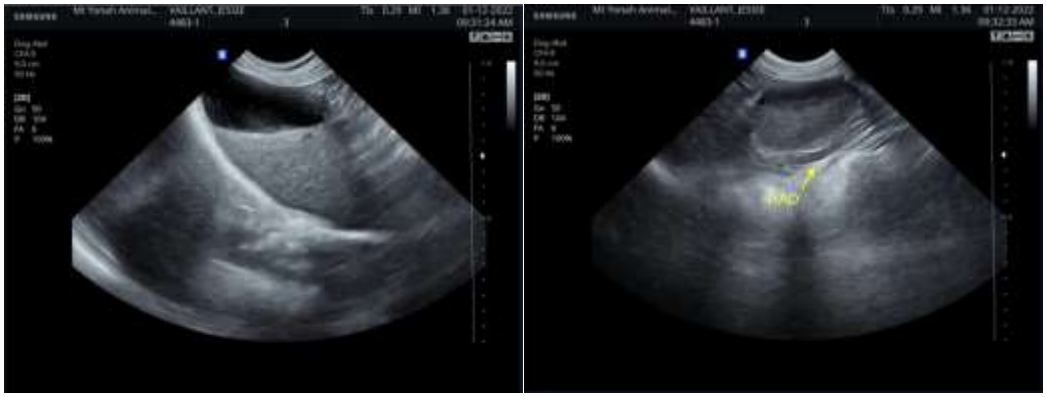

SonoPath

Clinical Sonography & Telecytology

EDUCATIONAL TELECONSULTATION SERVICES™

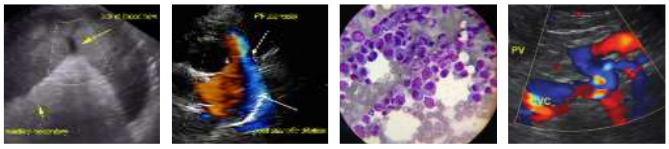

SonoPath.com™

1-800-838-4268 info@sonopath.com

PATIENT

Jessie Vaillant

SPECIES

Canine

BREED

Boston Terrier

SEX

Spayed Female

AGE

8 years

WEIGHT

26 lbs.

INTERPRETED BY

R. McKenzie Daniel, DVM, DABVP (Canine and Feline)

IMAGING PERFORMED BY

Dr. Eddleman

HOSPITAL NAME

Mt. Yonah AH

REFERRING VET

Rachel Eddleman

INVOICE

13043

DATE

1/12/22

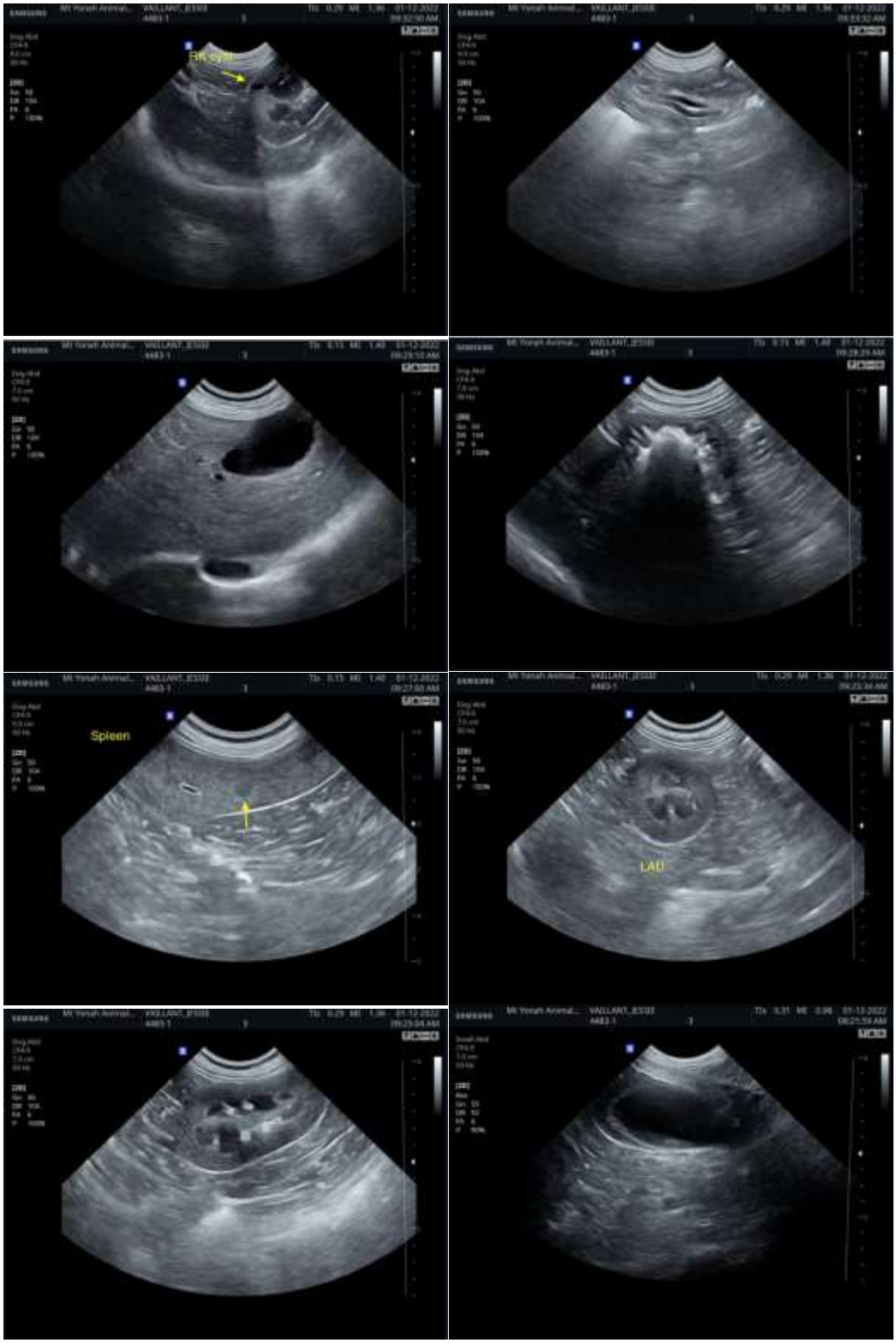

The information and recommendations provided are based on the images presented by the referring veterinarian. No evaluation can be communicated regarding pathology that was not

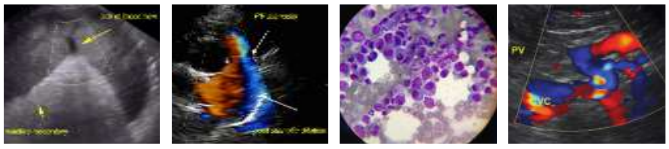

SonoPath.com™
1-800-838-4268 info@sonopath.com

PATIENT

Jessie Vaillant

SPECIES

Canine

BREED

Boston Terrier

SEX

Spayed Female

AGE

8 years

WEIGHT

26 lbs.

INTERPRETED BY

R. McKenzie Daniel, DVM, DABVP (Canine and Feline)

IMAGING PERFORMED BY

Dr. Eddleman

HOSPITAL NAME

Mt. Yonah AH

REFERRING VET

Rachel Eddleman

INVOICE

13043

DATE

1/12/22

visible in the image/video clips provided.

Thank you for this referral. If the clinical or image interpretation does not parallel your findings or if I can be of any further assistance please contact me.

R. McKenzie Daniel, DVM, DABVP (Canine / Feline Practice)
info@SonoPath.com