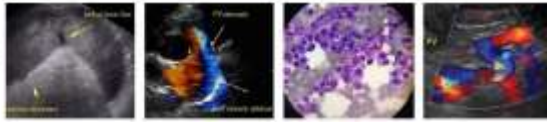




PATIENT	PRESENTING CLINICAL SIGNS
Max Johnston	Diabetic cat admitted for lethargy and acting very painful. Has been on Fentanyl CRI and was given Dexdomitor for scan today. Suspected free fluid and concerned re: a mass in the abdomen. Abnormal PE/Chem/CBC/UA Results: n/a
SPECIES	ULTRASONOGRAPHIC EXAMINATION OF THE ABDOMEN
Feline	<i>Urinary System</i>
BREED	The urinary bladder, trigone, cystourethral junction, and visible pelvic urethra to a depth of 2.0 cm exhibited normal thickness and tone. Primarily anechoic urine was present in the lumen. Echogenic to particulate sediment was present with probable focal dependent mineral and without evidence of calculus formation. The ureteral papillae were normal. The ureters were not visible which is normal. No evidence of inflammatory or neoplastic mural changes were noted.
DSH	
SEX	The area of the residual prostate appeared normal and free of pathology.
MN	No evidence of pathology in the area of the aortic trifurcation.
AGE	Normal size and margination was present in the kidneys. A normal 1:3 cortex / medulla ratio was maintained. The medulla and cortices were uniform in texture with some increased echogenicity and mild loss of corticomedullary symmetry and definition expected for the age of the patient. No evidence of pyelectasia or pyelonephritis was present. The left kidney measured 4.2 cm in length. The right kidney measured 4.5 cm in length.
14 Years	
WEIGHT	<i>Adrenal Glands</i>
6.15 kg	The left and right adrenal glands were not definitively visualized given the presence of peritoneal free fluid and periadrenal nonuniform to nodular mesentery.
INTERPRETED BY	<i>Spleen</i>
R. McKenzie Daniel, DVM, DABVP	The spleen was mildly subnormal in size suspected to be secondary to volume contraction. Subtle generalized splenic parenchyma heterogeneity was noted. No distinct masses or nodules. The splenic vasculature at the hilus was normal in volume with no evidence of congestion or thrombosis. The spleen measured 0.52 cm width at the level of the hilus.
IMAGING PERFORMED BY	<i>Liver</i>
Crystal Hill	The liver was subjectively normal in size, structure, and contour. The discernible hepatic parenchyma exhibited subtly nonuniform increased parenchyma echogenicity in the mid to right liver. Ill-defined expansive nonhomogeneous to hypoechoic mass appearing to originate from the caudal mid to right liver extending caudally passed the level of the gastric axis and into the area of the pancreas was present. The mass measured at least 8.0 cm in diameter but potentially larger as the entire mass would not fit into a single viewing window and was noted in both the right and left mid to cranial abdominal windows. Generalized nonuniform mesentery exhibiting multiple omental nodular lesions as well as similar appearing lesions along the ventral body wall surface.
HOSPITAL NAME	INVOICE
Hamilton Region Emergency Clinic	The gallbladder was non-distended in size with thin walls and primarily anechoic luminal content. The cystic and common bile ducts were normal.
REFERRING VET	<i>Gastrointestinal</i>
Rubino	The stomach presented intact wall layering with a normal wall layer ratio. The lumen of the stomach was empty with no signs of ileus, obstruction or foreign material.
INVOICE	
49426	
DATE	
1-10-22	



PATIENT

Max Johnston

The small intestine presented intact wall layering with primarily maintained 1:3 muscularis/mucosa ratio with subjective propensity for segmental mildly prominent muscularis layer. No overt evidence of loss of intestinal wall layering or distinct intestinal masses. The lumen of the small intestine was empty with no signs of ileus, obstruction or foreign material.

SPECIES

Feline

Normal visible colon wall layers were present with semi-formed feces in lumen.

Pancreas

BREED

DSH

The parenchyma of the left limb, body and right limb of the pancreas presented isoechoic to the adjacent omental fat. A normal curvilinear capsule contour of the pancreas was present. The visible pancreatic duct was normal. No signs of active inflammation or neoplastic disease was evident.

Free Abdomen

SEX

MN

Moderate volume cellular peritoneal free fluid was present.

No overt lymphadenopathy was present.

ULTRASONOGRAPHIC FINDINGS

AGE

14 Years

- Urinary bladder sediment with focal dependent mineral.
- Unspecified mass in the area of the caudal liver and pancreas.
- Associated generalized nonhomogeneous mesentery exhibiting primarily uniform nodular lesions, concurrent similar appearing body wall lesions.
- Suspect segmental enteropathy.
- Moderate volume cellular peritoneal free fluid.

WEIGHT

6.15 kg

INTERPRETED BY

R. McKenzie Daniel,
DVM, DABVP

INTERPRETATION OF THE FINDINGS & FURTHER RECOMMENDATIONS

Unfortunately, sonographic abnormalities are consistent with diffuse neoplastic process suspected to be involving the liver, pancreas, as well as generalized omentum, and likely body wall as with the carcinomatosis or similar.

IMAGING PERFORMED BY

Crystal Hill

Further assessment may include effusion analysis, cytology, +/- culture and sensitivity, if evidence of inflammatory cells, as well as ultrasound guided FNA of the unspecified mass and/or omental nodular lesion. However, unfortunately, unfavorable prognosis is indicated.

HOSPITAL NAME

Hamilton Region
Emergency Clinic

REFERRING VET

Rubino

INVOICE

49426

DATE

1-10-22



PATIENT

Max Johnston

SPECIES

Feline

BREED

DSH

SEX

MN

AGE

14 Years

WEIGHT

6.15 kg

INTERPRETED BY

R. McKenzie Daniel,
DVM, DABVP

**IMAGING
PERFORMED BY**

Crystal Hill

HOSPITAL NAME

Hamilton Region
Emergency Clinic

REFERRING VET

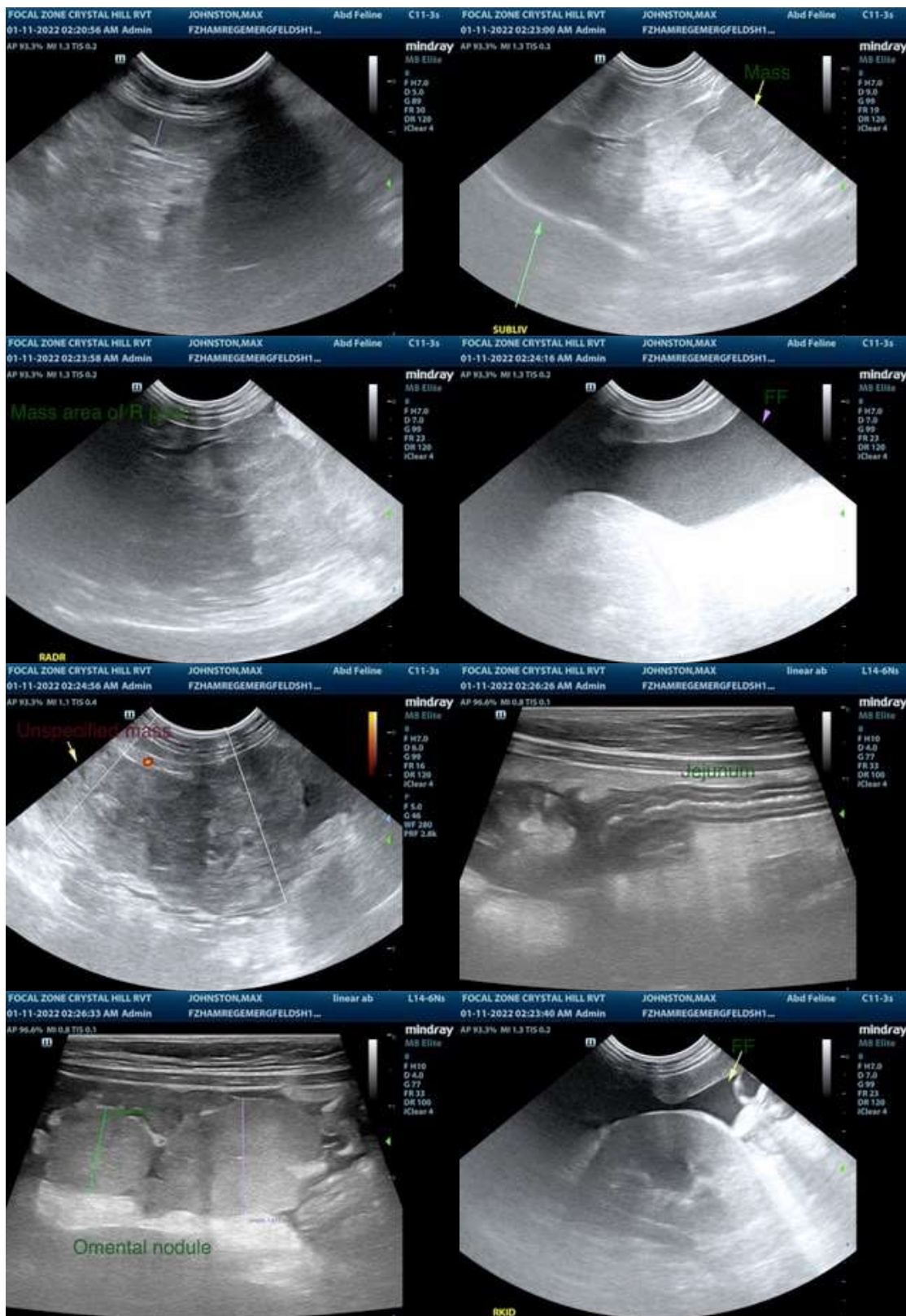
Rubino

INVOICE

49426

DATE

1-10-22





PATIENT

Max Johnston

SPECIES

Feline

BREED

DSH

SEX

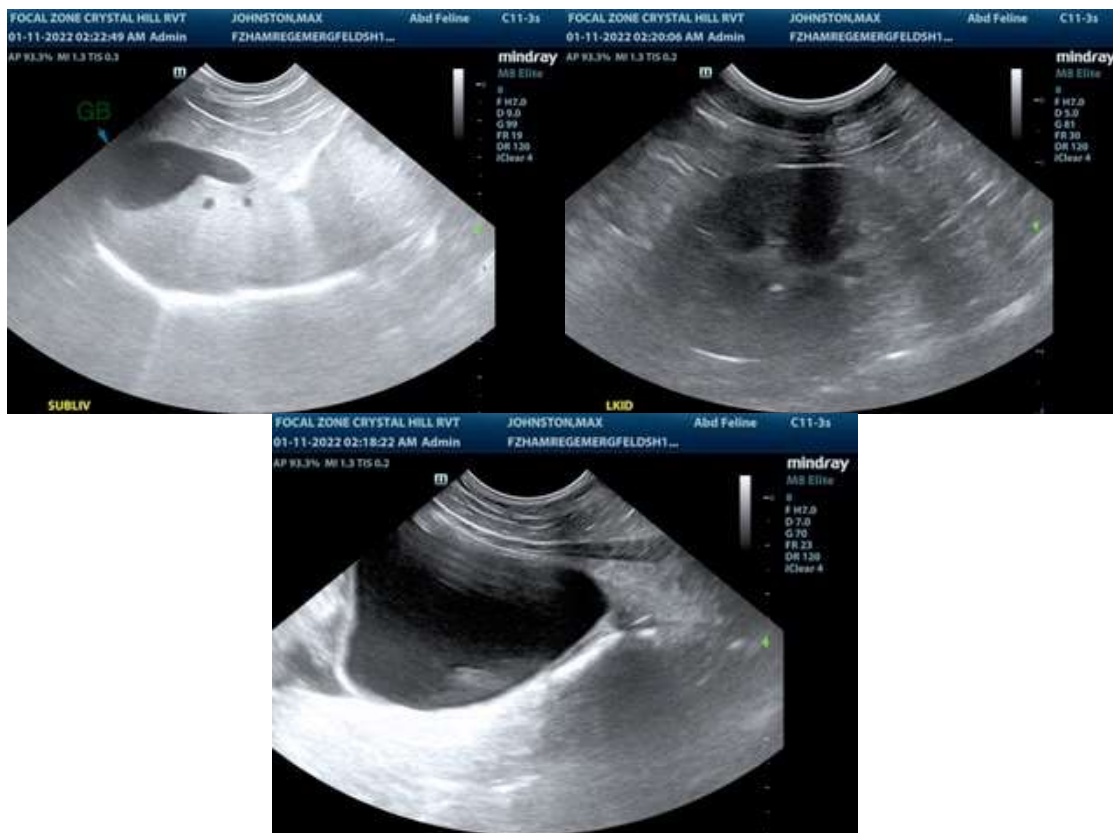
MN

AGE

14 Years

WEIGHT

6.15 kg



INTERPRETED BY

R. McKenzie Daniel,
DVM, DABVP

IMAGING PERFORMED BY

Crystal Hill

HOSPITAL NAME

Hamilton Region
Emergency Clinic

REFERRING VET

Rubino

INVOICE

49426

DATE

1-10-22

The information and recommendations provided are based on the images presented by the referring veterinarian. No evaluation can be communicated regarding pathology that was not visible in the image/video clips provided.

Thank you for this referral. If the clinical or image interpretation does not parallel your findings or if I can be of any further assistance please contact me.

R. McKenzie Daniel, DVM, DABVP (Canine / Feline Practice)

info@SonoPath.com