

**PATIENT**

Itsy Nagle

SPECIES

Feline

BREED

DLH

SEX

SF

AGE

13 years

WEIGHT

13.2 lbs.

INTERPRETED BYR. McKenzie Daniel,
DVM, DABVP
(Canine and Feline)**IMAGING
PERFORMED BY**

Sarah Pender, CVT

HOSPITAL NAME

SVS Imaging QC

REFERRING VET

Dr. Narske

INVOICE

13016

DATE

1/10/22

PRESENTING CLINICAL SIGNS

Soft, loose stools, diarrhea, drinking excessively with frequent urination.

Abnormal PE/Chem/CBC/UA Results: Polyuria, Polydipsia, Diarrhea. Bloodwork shows elevated SDMA and Creatinine levels on 1/7/22

ULTRASONOGRAPHIC EXAMINATION OF THE ABDOMEN**Urinary System**

The urinary bladder, trigone, cystourethral junction, and visible pelvic urethra to a depth of 2.0 cm exhibited normal thickness and tone. Anechoic urine was present in the lumen with no uroliths or sediment. The ureteral papillae were normal. The ureters were not visible which is normal. No evidence of inflammatory or neoplastic changes was noted.

The area of the aortic trifurcation was free of pathology.

Normal size and margination were present in the kidneys. A normal 1:3 cortex / medulla ratio was maintained. The medulla and cortices were uniform in texture with some increased echogenicity and mild loss of corticomedullary symmetry and definition expected for the age of the patient. Mild pyelectasia was present in the right kidney. The left kidney measured 3.9 cm in length. The right kidney measured 3.7 cm in length.

Adrenal Glands

The left adrenal gland was uniform in size and contour with a uniformly hypoechoic parenchyma, measuring 0.46 cm width. No overt pathology was noted in the area of the right adrenal gland.

Spleen

The spleen exhibited a finely textured and homogenous parenchyma which was hyperechoic to the liver and renal cortical parenchyma. The capsule was smooth and regular without apparent expansion. The splenic vasculature at the hilus was normal in volume with no evidence of congestion or thrombosis. Acute to chronic inflammatory, neoplastic, or benign parenchyma changes were not noted.

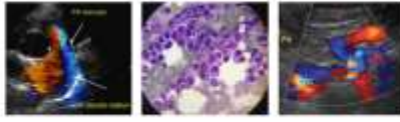Liver/ Gallbladder

The liver was subjectively normal in size, structure, and contour. The liver parenchyma was uniform and hypoechoic to the spleen with a mild coarse echotexture. The hepatic and portal vasculature were normal in appearance without signs of congestion. The gallbladder was non-distended in size with thin walls and primarily anechoic luminal content. The cystic and common bile ducts were normal.

Gastrointestinal

The stomach presented intact wall layering with a normal wall layer ratio. The lumen of the stomach was empty with no signs of ileus, obstruction, or foreign material. The gastric body wall width measured 0.25 cm.

The small intestine presented intact wall layering with subjective propensity for segmental to generalized mildly prominent muscularis layer, yet without evidence of mural hypertrophy, loss of

**PATIENT**

Itsy Nagle

intestinal wall layering, or intestinal masses. The jejunum wall width measured 0.24 cm. The ileocolic wall width measured 0.38 cm.

SPECIES

Feline

Minor colic lymphadenopathy adjacent to the ileocolic junction was present. An example of a colic lymph node measured 0.28 cm. These lymph nodes were not overtly consistent with inflammatory or neoplastic criteria.

Pancreas**BREED**

DLH

The parenchyma of the left limb, body, and right limb of the pancreas presented isoechoic to the adjacent omental fat. A normal curvilinear capsule contour of the pancreas was present. The visible pancreatic duct was normal. No signs of active inflammation or neoplastic disease were evident.

SEX

SF

Free Abdomen

No effusion was present.

ULTRASONOGRAPHIC FINDINGS**AGE**

13 years

Primary Findings

- Mild chronic renal changes with minor right kidney pyelectasia
- Potential inflammatory enteropathy
- Focal, subjectively benign / reactive colic lymph node

WEIGHT

13.2 lbs.

INTERPRETATION OF THE FINDINGS & FURTHER RECOMMENDATIONS**INTERPRETED BY**

R. McKenzie Daniel,
DVM, DABVP
(Canine and Feline)

The pyelectasia in the right kidney may be owing to chronic renal changes, potential pelvic scarring possibly owing to previous calculi passage, IV fluid therapy (if applicable). Urine C/S and protein:creatinine ratio on sterile urine sample is recommended.

IMAGING PERFORMED BY

Sarah Pender, CVT

Although not definitive, the small intestine exhibited subtle mural changes which may suggest underlying inflammatory enteropathy or IBD. However, this finding is nonspecific given the lack of reported weight loss or other gastrointestinal signs aside from diarrhea. Potential for structurally insignificant colitis may be possible. Further assessment may include fresh fecal analysis to assess for parasitic ova / Giardia, as well as a GI panel to include PLI/TLI/Cobalamin/Folate.

HOSPITAL NAME

SVS Imaging QC

Empirically, prophylactic deworming if the patient if Indoor/outdoor, hydrolyzed diet trial, cobalamin supplementation +/- Prednisolone trial at the lowest effective dose to control clinical signs and assessment of clinical response may be considered.

REFERRING VET

Dr. Narske

INVOICE

13016

DATE

1/10/22



PATIENT

Itsy Nagle

SPECIES

Feline

BREED

DLH

SEX

SF

AGE

13 years

WEIGHT

13.2 lbs.

INTERPRETED BY

R. McKenzie Daniel,
DVM, DABVP
(Canine and Feline)

IMAGING PERFORMED BY

Sarah Pender, CVT

HOSPITAL NAME

SVS Imaging QC

REFERRING VET

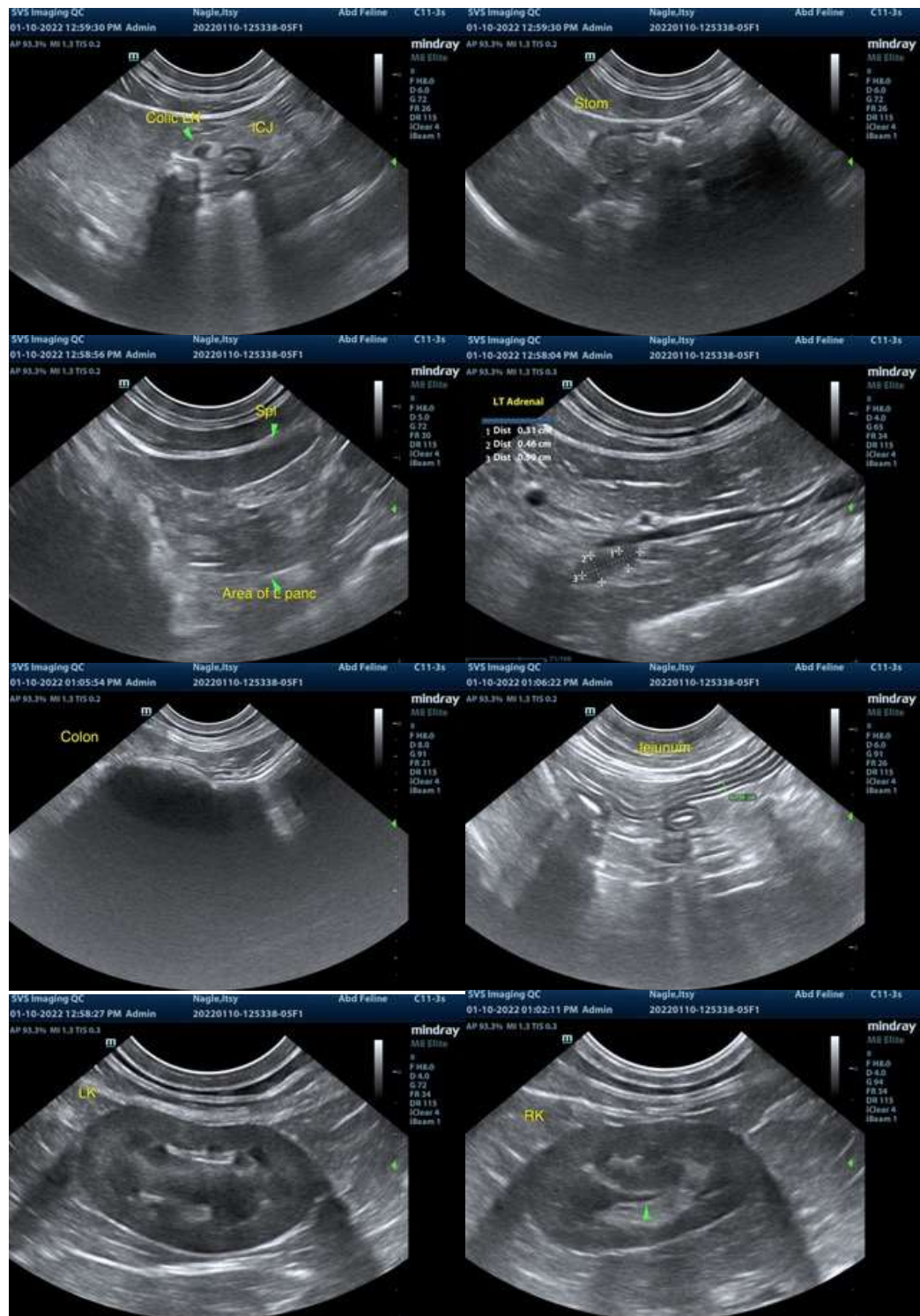
Dr. Narske

INVOICE

13016

DATE

1/10/22





PATIENT

Itsy Nagle

SPECIES

Feline

BREED

DLH

SEX

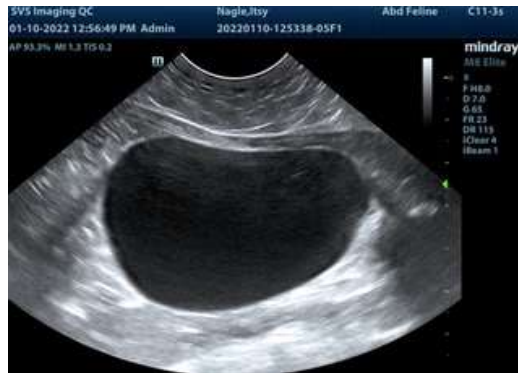SF

AGE

13 years

WEIGHT

13.2 lbs.



The information and recommendations provided are based on the images presented by the referring veterinarian. No evaluation can be communicated regarding pathology that was not visible in the image/video clips provided.

Thank you for this referral. If the clinical or image interpretation does not parallel your findings or if I can be of any further assistance please contact me.

R. McKenzie Daniel, DVM, DABVP (Canine / Feline Practice)
info@SonoPath.com

INTERPRETED BY

R. McKenzie Daniel,
DVM, DABVP
(Canine and Feline)

IMAGING PERFORMED BY

Sarah Pender, CVT

HOSPITAL NAME

SVS Imaging QC

REFERRING VET

Dr. Narske

INVOICE

13016

DATE

1/10/22