



PATIENT

Angus Shelby

SPECIES

Canine

BREED

Australian Shepherd

SEX

MN

AGE

13 years

WEIGHT

46.8 lbs.

INTERPRETED BY

R. McKenzie Daniel,
DVM, DABVP
(Canine and Feline)

IMAGING PERFORMED BY

Jasmine Palacios
SDEP Attendee

HOSPITAL NAME

Rivers Edge PMC

REFERRING VET

Dr. Jason
Christensen

INVOICE

13005

DATE

1/10/22

PRESENTING CLINICAL SIGNS

P is having smaller stools and is possibly straining to defecate. P resists palpation of the rectum, suspect swelling of the Left anal gland and possibly the colon. Very hard, small stool is present. P is losing weight consistently. On previous exams the swelling near the left anal gland was more focalized to the gland. On rectal palpation today it felt more diffuse, P is more painful than previous visit. O feels that p is overall less painful after being on daily Carprofen. No Rads done at this point.

Abnormal PE/Chem/CBC/UA Results: Lab abnormalities: Mild ALT elevations previously

ULTRASONOGRAPHIC EXAMINATION OF THE ABDOMEN

Urinary System

The urinary bladder, trigone, cystourethral junction, and visible pelvic urethra to a depth of 3.0 cm exhibited normal thickness and tone. Anechoic urine was present in the lumen with no uroliths or sediment. The ureteral papillae were normal. The ureters were not visible which is normal. No evidence of inflammatory or neoplastic changes was noted.

The residual prostate was normal in size and contour with subtle parenchymal heterogeneity with evidence of focal parenchymal mineralization. The prostate measured 1.0 cm in diameter.

The area of the aortic trifurcation was free of pathology.

Normal size and margination were present in the kidneys. A normal 1:3 cortex / medulla ratio was maintained. The medulla and cortices were uniform in texture with some increased echogenicity and mild loss of corticomedullary symmetry and definition expected for the age of the patient. No evidence of pelvic dilation was present. The left kidney measured 5.9 cm in length. The right kidney measured 5.7 cm in length.

Adrenal Glands

The left adrenal gland was uniform in size and contour with a uniformly hypoechoic parenchyma. The left adrenal gland measured 2.9 cm length x 0.43 cm width at the caudal pole. The right adrenal gland was uniform in size and contour with a uniformly hypoechoic parenchyma. The right adrenal gland measured 2.6 cm length x 0.57 cm width at the caudal pole.

Spleen

The spleen exhibited size and overall contour with generalized mild splenic heterogeneity. Discreet, non-expansive, subtly hypoechoic nodule was noted in the medial parenchyma measuring 1.0 cm in diameter.

Liver/ Gallbladder

The liver exhibited mild generalized enlargement with normal structure and contour. The liver parenchyma was mildly nonuniform and hypoechoic to the spleen with a moderate coarse echotexture and subjective mild to benign parenchymal remodeling. The hepatic and portal vasculature were normal in appearance without signs of congestion. The gallbladder contained nondependent yet nonorganized debris primarily in the caudal lumen and gallbladder neck. No evidence of gallbladder or peripheral gallbladder inflammation was noted. The cystic and common bile ducts were normal.



PATIENT

Gastrointestinal

Angus Shelby

The stomach presented intact wall layering with mild retained ingesta / chyme with luminal gas present. No overt evidence of foreign material or mechanical pyloric outflow obstruction was noted. The gastric body wall width measured 0.45 cm.

SPECIES

Canine

The small intestine presented intact wall layering with 1:3 muscularis/mucosa ratio. The lumen of the small intestine was empty with no signs of ileus, obstruction, or foreign material. The jejunum wall width measured 0.38 cm.

BREED

Australian Shepherd

The colon exhibited intact yet subjective mild prominent wall layering. The distal colon to colorectal wall measured 0.33 cm. Sonographic evidence of the rectum revealed potential for focal colon wall abnormality, measuring approximately 2.0 cm in length. Potential focal wall abnormality was noted subjectively between the left and right anal sacs.

SEX

MN

AGE

13 years

Pancreas

The parenchyma of the left limb, body, and right limb of the pancreas presented isoechoic to the adjacent omental fat. A normal curvilinear capsule contour of the pancreas was present. The visible pancreatic duct was normal. No signs of active inflammation or neoplastic disease were evident.

WEIGHT

46.8 lbs.

Free Abdomen

INTERPRETED BY

R. McKenzie Daniel,
DVM, DABVP
(Canine and Feline)

Subjectively, the anal sacs appeared to be overtly normal containing mildly nonhomogeneous fluid. The right anal sac measured approximately 1.8 cm. The left anal sac measured approximately 1.4 cm in diameter respectively.

No overt lymphadenopathy or effusion was noted.

IMAGING PERFORMED BY

Jasmine Palacios
SDEP Attendee

ULTRASONOGRAPHIC FINDINGS

Primary Findings

- Hepatomegaly exhibiting parenchymal remodeling - subjectively benign
- Nonorganized gallbladder debris (non-mucocele)
- Nonspecific discreet splenic nodule - suspect benign, focal hematopoiesis, hyperplasia, lipogranuloma, or splenitis possible, potential for neoplastic criteria is considered unlikely yet cannot be definitively excluded
- Normal residual prostate size with evidence of parenchymal mineralization
- Suspect mild colitis, potential nonspecific colorectal wall abnormality
- Overtly normal bilateral anal sacs

HOSPITAL NAME

Rivers Edge PMC

REFERRING VET

Dr. Jason
Christensen

INVOICE

13005

DATE

1/10/22

INTERPRETATION OF THE FINDINGS & FURTHER RECOMMENDATIONS

Sonographic monitoring of the splenic nodule for evidence of progression is recommended.

The normal prostatic size was not consistent with prostatic etiology as a cause of the patient's clinical signs. However, mineralization has at times been associated with emerging prostatic neoplasia.



PATIENT

Angus Shelby

Prostatic sampling would be required for further clarification. Sonographic monitoring would be a more conservative approach.

SPECIES

Canine

If possible, colonic endoscopy would be ideal for further assessment. Continued monitoring of the bilateral anal sacs for evidence of progressive enlargement is recommended. Empirically, colitis protocol is recommended.

BREED

Australian Shepherd

SEX

MN

AGE

13 years

WEIGHT

46.8 lbs.

INTERPRETED BY

R. McKenzie Daniel,
DVM, DABVP
(Canine and Feline)

IMAGING PERFORMED BY

Jasmine Palacios
SDEP Attendee

HOSPITAL NAME

Rivers Edge PMC

REFERRING VET

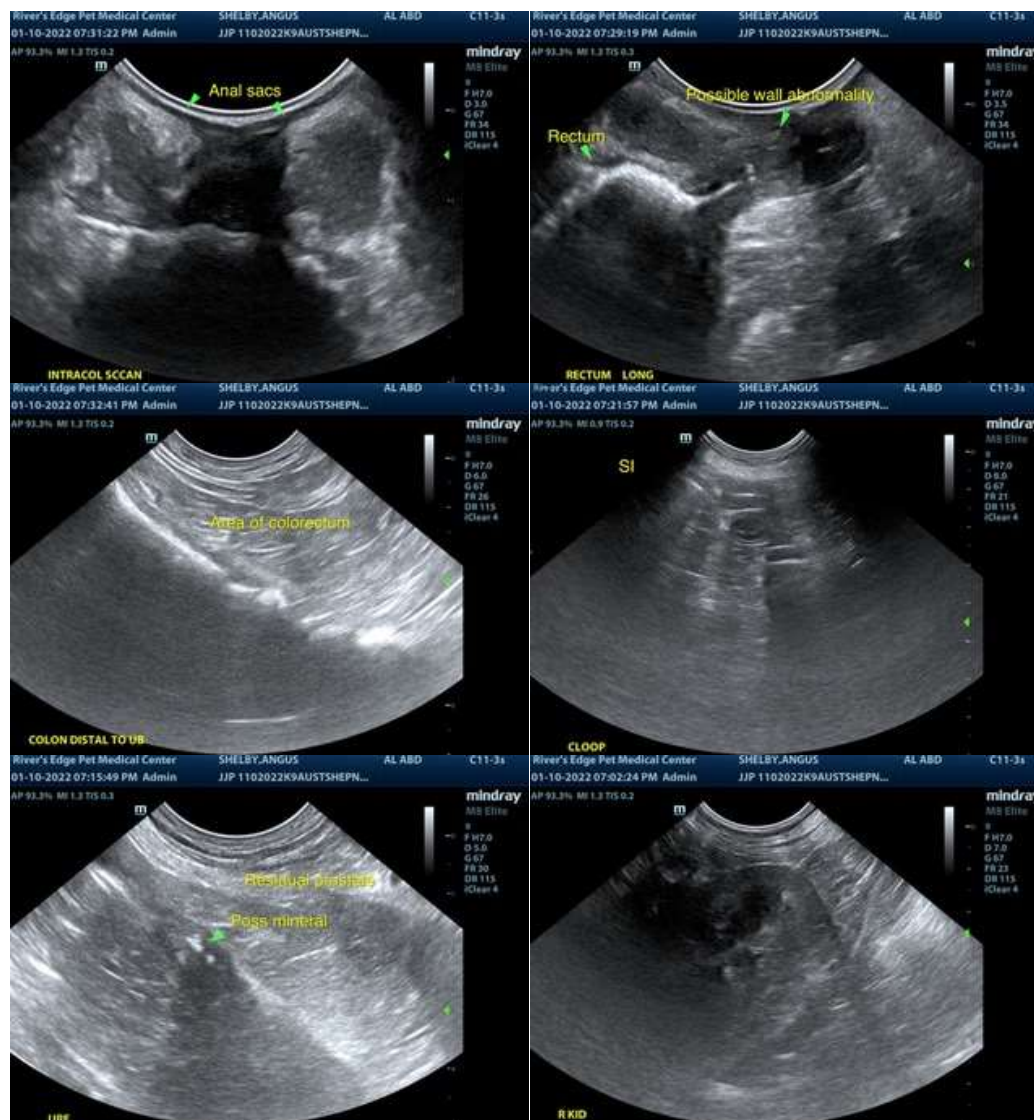
Dr. Jason
Christensen

INVOICE

13005

DATE

1/10/22





PATIENT

Angus Shelby

SPECIES

Canine

BREED

Australian Shepherd

SEX

MN

AGE

13 years

WEIGHT

46.8 lbs.

INTERPRETED BY

R. McKenzie Daniel,
DVM, DABVP
(Canine and Feline)

IMAGING PERFORMED BY

Jasmine Palacios
SDEP Attendee

HOSPITAL NAME

Rivers Edge PMC

REFERRING VET

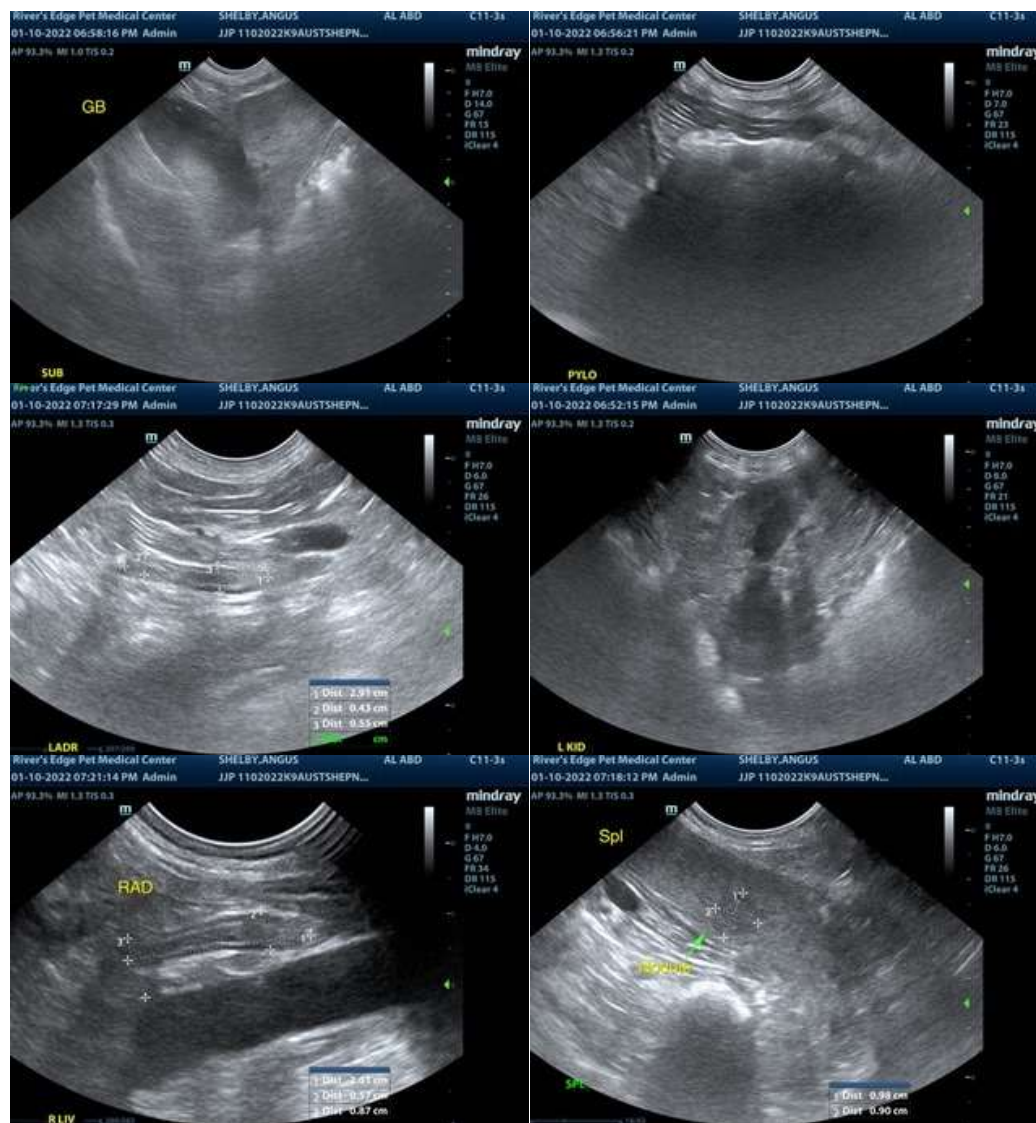
Dr. Jason
Christensen

INVOICE

13005

DATE

1/10/22



The information and recommendations provided are based on the images presented by the referring veterinarian. No evaluation can be communicated regarding pathology that was not visible in the image/video clips provided.

Thank you for this referral. If the clinical or image interpretation does not parallel your findings or if I can be of any further assistance please contact me.

R. McKenzie Daniel, DVM, DABVP (Canine / Feline Practice)
info@SonoPath.com