

PATIENT

Noodle Crone

SPECIES

Feline

BREED

DLH

SEX

Neutered Male

AGE

5 Years 1 Month

WEIGHT

20 lbs

INTERPRETED BY

Dr. Mauro Caldas MV,
CBRV

IMAGING PERFORMED BY

Pete Bashara, DVM

HOSPITAL NAME

Gentle Doctor Animal
Hospital

REFERRING VET

Pete Bashara, DVM

INVOICE

16410

DATE

06/05/26

PRESENTING CLINICAL SIGNS

Chronic sneezing and nasal congestion present for at least a year. Right-sided disease has been repeatedly noted: Crusty/swollen right nostril (July 2025). Yellow-green discharge recovered from the right side during nasal flush. Episode of bloody nasal discharge on 5/4/26. Persistent sneezing despite doxycycline therapy and intranasal FVRC vaccination trial.

COMPUTED TOMOGRAPHIC STUDY OF THE HEAD

Plain and post contrast images provided for review.

COMPUTED TOMOGRAPHIC FINDINGS

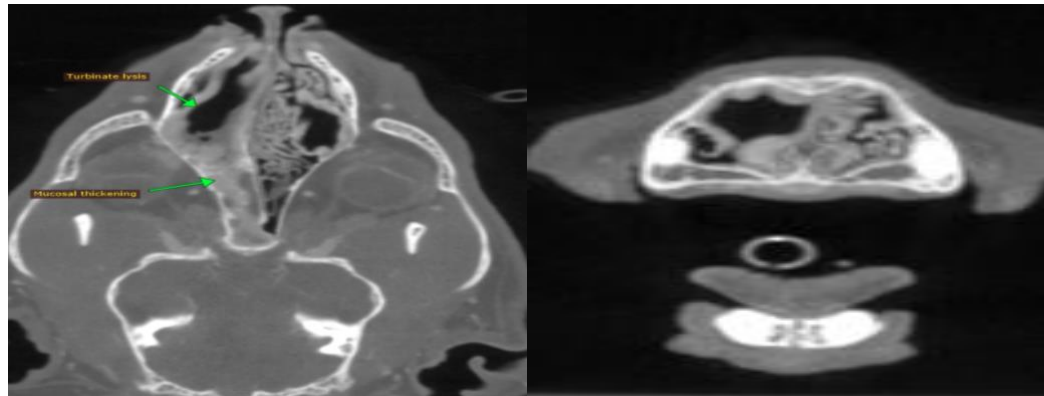
Nasal cavity with bilateral fluid attenuated content, turbinate lysis and mucosal thickening on both sides, worst on the right side. No obvious mass or foreign body is seen. Frontal sinus air filled on both sides. Nasopharynx with mild fluid content. The brain is unremarkable with no evidence of mass effect, hemorrhage, or abnormal contrast enhancement. Tympanic bullae are normal. Mandibular and retropharyngeal lymph nodes appear symmetrical with normal size and shape.

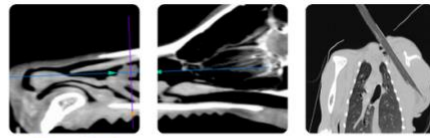
COMPUTED TOMOGRAPHIC DIAGNOSIS

- Bilateral aggressive rhinopathy, worst on the right side. Chronic rhinitis most likely.

INTERPRETATION OF FINDINGS & FURTHER RECOMMENDATIONS

Possible chronic primary lymphoplasmacytic rhinitis with secondary bacterial rhinitis. Fungal rhinitis cannot be ruled out. A small lucent foreign body cannot be ruled out. Rhinoscopy with biopsies and fungal tests is indicated.





PATIENT

Noodle Crone

SPECIES

Feline

BREED

DLH

SEX

Neutered Male

AGE

5 Years 1 Month

WEIGHT

20 lbs

INTERPRETED BY

Dr. Mauro Caldas MV,
CBRV

IMAGING PERFORMED BY

Pete Bashara, DVM

HOSPITAL NAME

Gentle Doctor Animal
Hospital

REFERRING VET

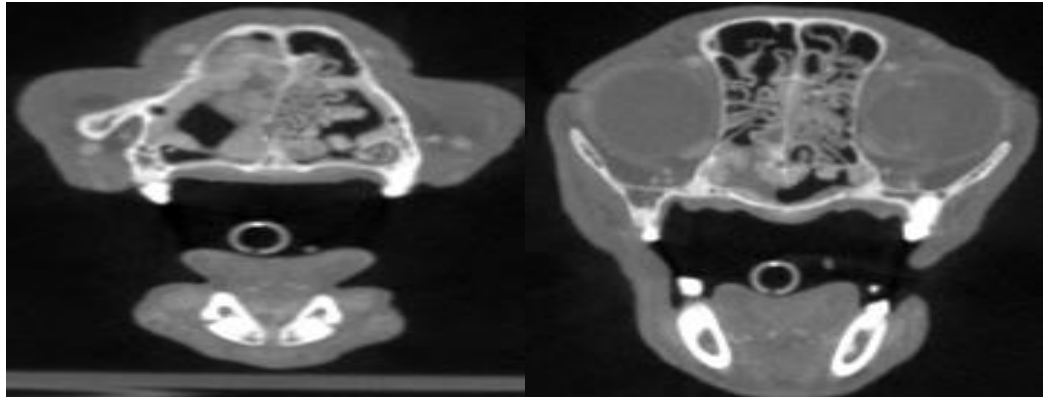
Pete Bashara, DVM

INVOICE

16410

DATE

06/05/26



The information and recommendations provided are based on the images presented by the referring veterinarian. No evaluation can be communicated regarding pathology that was not visible in the image/video clips provided.

Thank you for this referral. If the clinical or image interpretation does not parallel your findings or if I can be of any further assistance please contact me.

Dr. Mauro Caldas MV, CBRV

info@sonopath.com