



PATIENT

Ozzie Mendenhall

SPECIES

Canine

BREED

Golden Retriever

SEX

M

AGE

1Y, 6M

WEIGHT

79lbs

INTERPRETED BY

Dr. Mauro Caldas MV,
CBRV

IMAGING PERFORMED BY

Tina Lynn, CVT/George
Eales, DVM

HOSPITAL NAME

Green Prairie Animal
Hospital

REFERRING VET

The Pet Doctor-Dr. Jewell

INVOICE

75298

DATE

6-3-26

PRESENTING CLINICAL SIGNS

Presented to ER clinic on Saturday for acute onset sneezing, unremarkable exam, suspect F.B. inhalation in nose. Sneezing has slowed down but persists when dog gets excited

COMPUTED TOMOGRAPHIC STUDY OF THE HEAD

Survey and post contrast CT images provided for review.

COMPUTED TOMOGRAPHIC FINDINGS

Conchae and turbinates present with normal air pattern. No fluid or mass seen and no turbinate lysis or nasal septum deviation. No obvious foreign body seen.

The dentition appears normal.

Temporomandibular joints are aligned and appear normal.

The brain and pituitary gland are unremarkable with no evidence of intracranial nodules, mass, or abnormal contrast enhancement.

The mandibular and medial retropharyngeal lymph nodes are within normal size and shape.

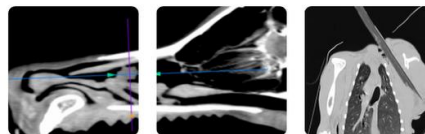
The salivary glands present within normal limits.

COMPUTED TOMOGRAPHIC DIAGNOSIS

- Normal airway. No foreign body seen.

INTERPRETATION OF FINDINGS & FURTHER RECOMMENDATIONS

Lymphoplasmacytic rhinitis cannot be ruled out as well as small lucent foreign bodies. If clinical signs persist, rhinoscopy may be considered.



PATIENT

Ozzie Mendenhall

SPECIES

Canine

BREED

Golden Retriever

SEX

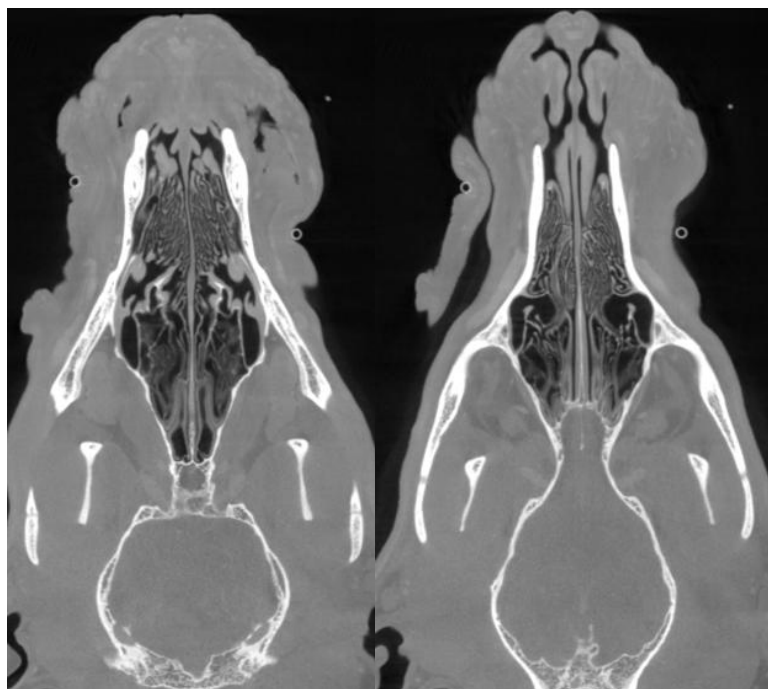
M

AGE

1Y, 6M

WEIGHT

79lbs



INTERPRETED BY

Dr. Mauro Caldas MV,
CBRV

IMAGING PERFORMED BY

Tina Lynn, CVT/George
Eales, DVM

HOSPITAL NAME

Green Prairie Animal
Hospital

REFERRING VET

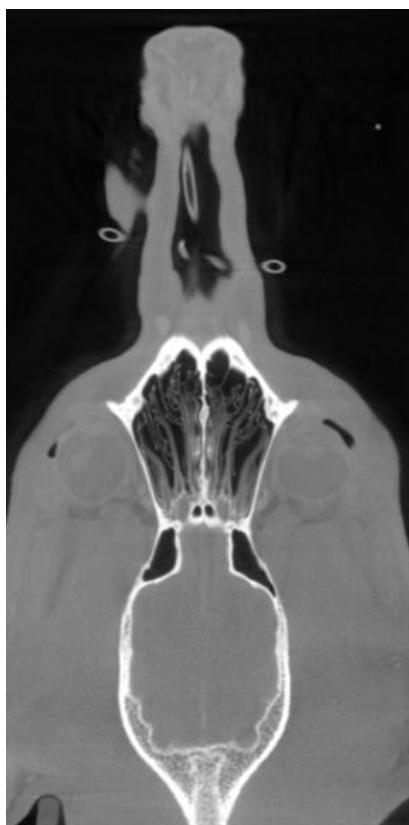
The Pet Doctor-Dr. Jewell

INVOICE

75298

DATE

6-3-26





PATIENT

Ozzie Mendenhall

SPECIES

Canine

BREED

Golden Retriever

SEX

M

AGE

1Y, 6M

WEIGHT

79lbs

INTERPRETED BY

Dr. Mauro Caldas MV,
CBRV

IMAGING PERFORMED BY

Tina Lynn, CVT/George
Eales, DVM

HOSPITAL NAME

Green Prairie Animal
Hospital

REFERRING VET

The Pet Doctor-Dr. Jewell

INVOICE

75298

DATE

6-3-26

The information and recommendations provided are based on the images presented by the referring veterinarian. No evaluation can be communicated regarding pathology that was not visible in the image/video clips provided.

Thank you for this referral. If the clinical or image interpretation does not parallel your findings or if I can be of any further assistance please contact me.

Dr. Mauro Caldas MV, CBRV

info@sonopath.com