



PATIENT

Jackson Wood

SPECIES

Canine

BREED

Terrier Mix

SEX

MN

AGE

14Y

WEIGHT

46lbs

INTERPRETED BY

Dr. Mauro Caldas MV,
CBRV

IMAGING PERFORMED BY

Tina Lynn, CVT/George
Eales, DVM

HOSPITAL NAME

Green Prairie Animal
Hospital

REFERRING VET

Dr. Mickna-Gibson Vet
Clinic

INVOICE

75197

DATE

5-28-26

PRESENTING CLINICAL SIGNS

Elevated liver values, Gallbladder mucocele w/possible biliary obstruction on ultrasound
Abnormal PE/Chem/CBC/UA Results: Sept 2024-removed large mass from left side histopath
results returned as Soft tissue sarcoma, Grade 2, left epaxial region Heart murmur present 5/6.

COMPUTED TOMOGRAPHIC STUDY OF ABDOMEN

Survey and post contrast CT images provided for review.

COMPUTED TOMOGRAPHIC FINDINGS

Liver presents normal in size. No mass or nodules seen.

The gallbladder is full and enlarged in size with dense content (sludge) occupying almost all of the cavity. External biliary ducts are diffusely enlarged measuring 1,6 cm wide in the choledochus. No mass or stones seen.

The stomach and small intestines appear normal.

Feces with normal density and volume are present in the colon and rectum.

The spleen is mildly enlarged in size. No mass or nodules seen.

The adrenal glands appear normal.

Both kidneys present with normal size and mild irregular shape. Normal contrast excretion is noted on both sides.

There is no evidence of peritoneal effusion or peritonitis.

Medial iliac lymph nodes are symmetrical, with normal size and shape.

Urinary bladder presents with thin walls and no stones seen.

COMPUTED TOMOGRAPHIC DIAGNOSIS

- Dense sludge occupying a dilated gallbladder with enlarged biliary ducts.
- No obvious mass seen.

INTERPRETATION OF FINDINGS & FURTHER RECOMMENDATIONS

Cholestasis and possible mucocele are likely. Metabolic causes should be ruled out. Cholecystectomy may be considered.



PATIENT

Jackson Wood

SPECIES

Canine

BREED

Terrier Mix

SEX

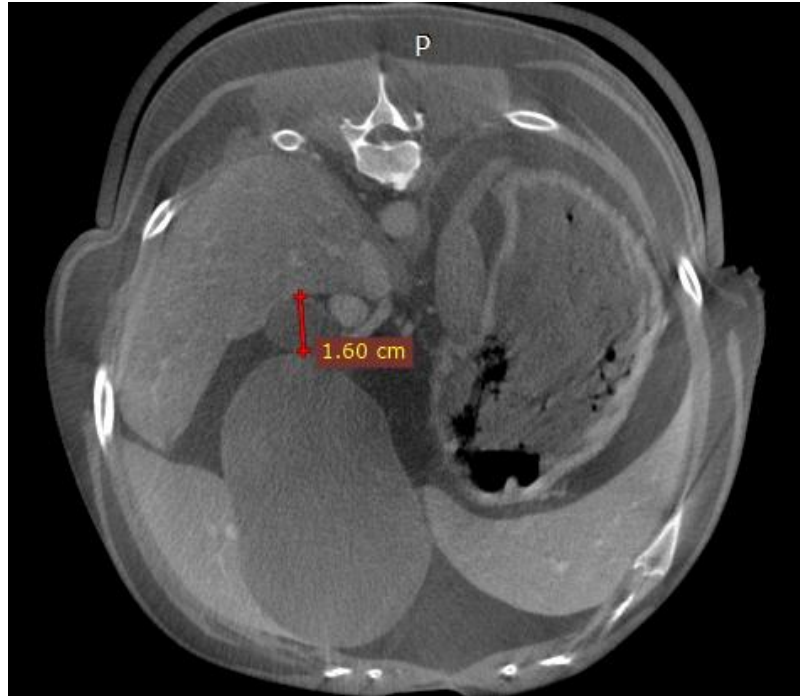
MN

AGE

14Y

WEIGHT

46lbs



INTERPRETED BY

Dr. Mauro Caldas MV,
CBRV

IMAGING PERFORMED BY

Tina Lynn, CVT/George
Eales, DVM

HOSPITAL NAME

Green Prairie Animal
Hospital

REFERRING VET

Dr. Mickna-Gibson Vet
Clinic

INVOICE

75197

DATE

5-28-26

The information and recommendations provided are based on the images presented by the referring veterinarian. No evaluation can be communicated regarding pathology that was not visible in the image/video clips provided.

Thank you for this referral. If the clinical or image interpretation does not parallel your findings or if I can be of any further assistance please contact me.

Dr. Mauro Caldas MV, CBRV

info@sonopath.com