



PATIENT

Brew Ballard

SPECIES

Canine

BREED

Labrador Retriever

SEX

MN

AGE

6Y, 10M

WEIGHT

70.8lbs

INTERPRETED BY

Dr. Mauro Caldas
MV, CBRV

IMAGING PERFORMED BY

Dr Jessie Evoniuk

HOSPITAL NAME

State Avenue Vet
Clinic

REFERRING VET

Dr Jessie Evoniuk

INVOICE

75201

DATE

05/28/2026

PRESENTING CLINICAL SIGNS

-Presents for right-sided facial discomfort, droopy right eye, firm muscle enlargement, and watering right eye. Duration: persistent signs for approximately 1 month without improvement. Previous oral exam: performed, no abnormalities detected.

- Client observations: Hesitant to take bones. Cries when handed bowl. Eating normally otherwise.
- No vomiting, diarrhea, coughing, or sneezing reported. Previous swelling in right temporal region, now resolved.

CT of head with IV contrast: to evaluate for foreign body, abscess, neoplasia, draining tract, dental pathology. Stoic, facial discomfort evident, OD- droopy eyelid, Right side of face: firm muscle enlargement, discomfort on palpation

COMPUTED TOMOGRAPHIC STUDY OF THE HEAD

Plain and post contrast images provided for review.

COMPUTED TOMOGRAPHIC FINDINGS

Presence of lysis is noted on the coronoid process of the ramus of the right mandible along with a mineralized well delimited mass measuring 5,3 x 2,7 x 4,0 cm size (long x wide x tall).

The brain is unremarkable with no evidence of mass effect or hemorrhage.

The nasal cavities present without fluid or mass. No turbinate lysis seen. Frontal sinuses present with air content on the both sides.

The dentition appears normal. No periodontal lysis seen.

The mandibular and retropharyngeal lymph nodes are symmetric with normal size and shape.

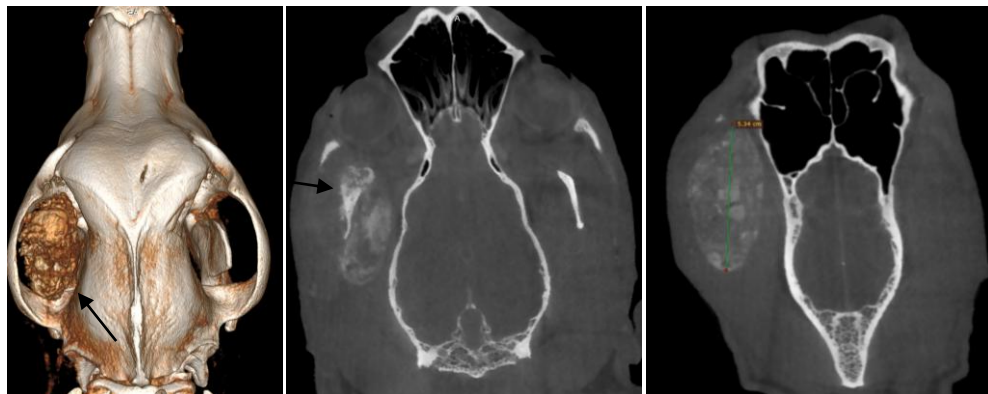
The salivary glands appear normal.

COMPUTED TOMOGRAPHIC DIAGNOSIS

- Bone mass from the coronoid process of the ramus of the right mandible.

INTERPRETATION OF FINDINGS & FURTHER RECOMMENDATIONS

Primary bone neoplasm is most likely such as chondroma, chondrosarcoma, or osteosarcoma. A biopsy is indicated as well as surgical evaluation.





PATIENT

Brew Ballard

SPECIES

Canine

BREED

Labrador Retriever

SEX

MN

AGE

6Y, 10M

WEIGHT

70.8lbs

INTERPRETED BY

Dr. Mauro Caldas
MV, CBRV

IMAGING PERFORMED BY

Dr Jessie Evoniuk

HOSPITAL NAME

State Avenue Vet
Clinic

REFERRING VET

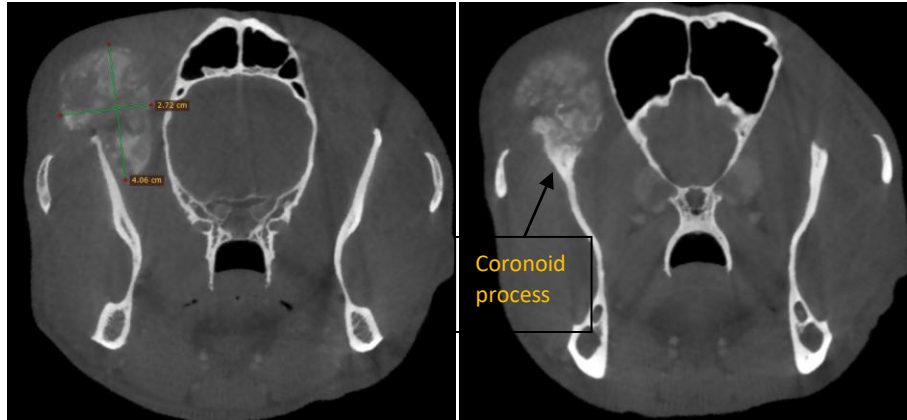
Dr Jessie Evoniuk

INVOICE

75201

DATE

05/28/2026



The information and recommendations provided are based on the images presented by the referring veterinarian. No evaluation can be communicated regarding pathology that was not visible in the image/video clips provided.

Thank you for this referral. If the clinical or image interpretation does not parallel your findings or if I can be of any further assistance please contact me.

Dr. Mauro Caldas MV, CBRV

info@sonopath.com