



PATIENT

Argus Klinger

SPECIES

Canine

BREED

German Shepherd

SEX

MN

AGE

11Y

WEIGHT

Approx 160lbs

INTERPRETED BY

Dr. Mauro Caldas
MV, CBRV

IMAGING PERFORMED BY

Tina Lynn, CVT/George
Eales, DVM

HOSPITAL NAME

Green Prairie Animal
Hospital

REFERRING VET

Dr. Sheri Williams-Animal
Hosp of Springfield

INVOICE

75200

DATE

05/28/2026

PRESENTING CLINICAL SIGNS

Chronic left nasal discharge for approx 4 months, Left ear otitis, minimal response to multiple antibiotics. Inner left ear appears hemorrhagic, ulcerated. Removed irregular mass from ear canal post CT scan

COMPUTED TOMOGRAPHIC STUDY OF THE HEAD

Plain and post-contrast images provided for review.

COMPUTED TOMOGRAPHIC FINDINGS

Fluid attenuating content and bulla bone lysis are noted within the left tympanic cavity with remodeling and expansion measuring 2,8 x 3,1 x 2,8 cm size (long x wide x tall). The right tympanic cavity is air filled, and no wall lysis is seen.

The left external ear canal presents diffuse wall thickening.

The brain is unremarkable with no evidence of mass effect, hemorrhage, or abnormal contrast enhancement. There is lysis on the left temporal bone but no obvious meningeal enhancement. Pituitary gland is 5,1 mm tall.

The nasal cavities present without fluid or mass. No turbinate lysis seen. Frontal sinuses present with air content on the both sides.

The dentition appears normal. No periodontal lysis seen.

The mandibular and retropharyngeal lymph nodes are symmetric with normal size and shape.

The salivary glands appear normal.

COMPUTED TOMOGRAPHIC DIAGNOSIS

- Left sided otitis media with lysis and expansion.
- Left external ear canal diffuse wall thickening.

INTERPRETATION OF FINDINGS & FURTHER RECOMMENDATIONS

Left sided cholesteatoma is most likely with external otitis. Bulla osteotomy with biopsies and culture is indicated.



PATIENT

Argus Klinger

SPECIES

Canine

BREED

German Shepherd

SEX

MN

AGE

11Y

WEIGHT

Approx 160lbs

INTERPRETED BY

Dr. Mauro Caldas
MV, CBRV

IMAGING PERFORMED BY

Tina Lynn, CVT/George
Eales, DVM

HOSPITAL NAME

Green Prairie Animal
Hospital

REFERRING VET

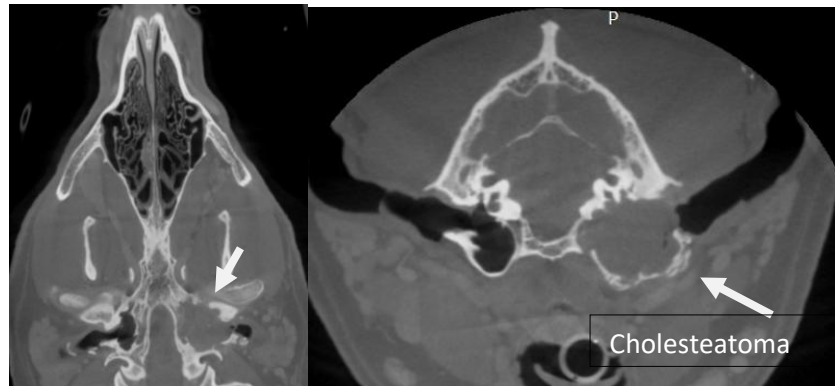
Dr. Sheri Williams-Animal
Hosp of Springfield

INVOICE

75200

DATE

05/28/2026



The information and recommendations provided are based on the images presented by the referring veterinarian. No evaluation can be communicated regarding pathology that was not visible in the image/video clips provided.

Thank you for this referral. If the clinical or image interpretation does not parallel your findings or if I can be of any further assistance please contact me.

Dr. Mauro Caldas MV, CBRV
info@sonopath.com