



PATIENT

Luffy Melendez

SPECIES

Canine

BREED

Golden Retriever Mix

SEX

SF

AGE

6Y

WEIGHT

46.5lbs

INTERPRETED BY

Dr. Mauro Caldas MV,
CBRV

IMAGING PERFORMED BY

José L. Alvarado Bruno,
CVT - CT Scan Technician

HOSPITAL NAME

Veterinary Image Center

REFERRING VET

Mariela Calderon, DVM

INVOICE

75190

DATE

5-27-26

PRESENTING CLINICAL SIGNS

Luffy is a 5 YO FS Golden retriever mix presenting for history of neurological symptoms. O mentions that P on May 10th, 2026 P started with what was described as bilateral nystagmus and noted a "drop" on left side of face. O mentions that P started with behavioral changes. When I asked owner what changes, she mentions that P became more "anxious " than before and right now doesn't even play with other dogs at home. Owner's mother has cows and owner thinks it could have been a traumatic event, however, there is no evidence physically today that P had any sort of trauma. During examination, we only appreciated ABSCENT PLR's OU. Owner mentions that sclera is also more observable than before patient started with neurological symptoms. Owner does mention that P is eating, defecating, urinating normal and no symptoms of ataxia or incoordination have been noted. 4dx today was negative and T4 was also negative. O has previous blood work from unknown veterinary clinic where all values were WNL.

Abnormal PE/Chem/CBC/UA Results: CBC --- unremarkable CHEM --- unremarkable CSF Tap was performed --- RESULTS PENDING.

COMPUTED TOMOGRAPHIC STUDY OF THE HEAD

Plain and post-contrast studies provided for review.

COMPUTED TOMOGRAPHIC FINDINGS

The brain and pituitary gland are unremarkable with no evidence of intracranial mass, hemorrhage, or abnormal contrast enhancement.

Tympanic bullae are air filled. A small otolith is noted on the right side.

Orbits are symmetric. Eye globes are symmetric with normal size and shape. No retrobulbar masses seen.

Thin and smoothly folded conchae and turbinates are air filled.

Both temporomandibular joints present congruent joint spaces.

No evidence of dental or periodontal disease.

The submandibular and medial retropharyngeal lymph nodes present with normal size and shape.

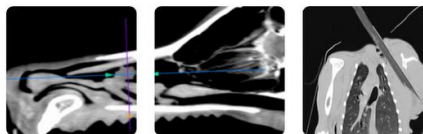
The salivary glands present within normal limits.

COMPUTED TOMOGRAPHIC DIAGNOSIS

- Normal skull

INTERPRETATION OF FINDINGS & FURTHER RECOMMENDATIONS

No lesion is identified that explains the clinical signs. A skull MRI and CSF tap could be recommended for better assessment of inflammatory neuritis.



PATIENT

Luffy Melendez

SPECIES

Canine

BREED

Golden Retriever Mix

SEX

SF

AGE

6Y

WEIGHT

46.5lbs

INTERPRETED BY

Dr. Mauro Caldas MV,
CBRV

IMAGING PERFORMED BY

José L. Alvarado Bruno,
CVT - CT Scan Technician

HOSPITAL NAME

Veterinary Image Center

REFERRING VET

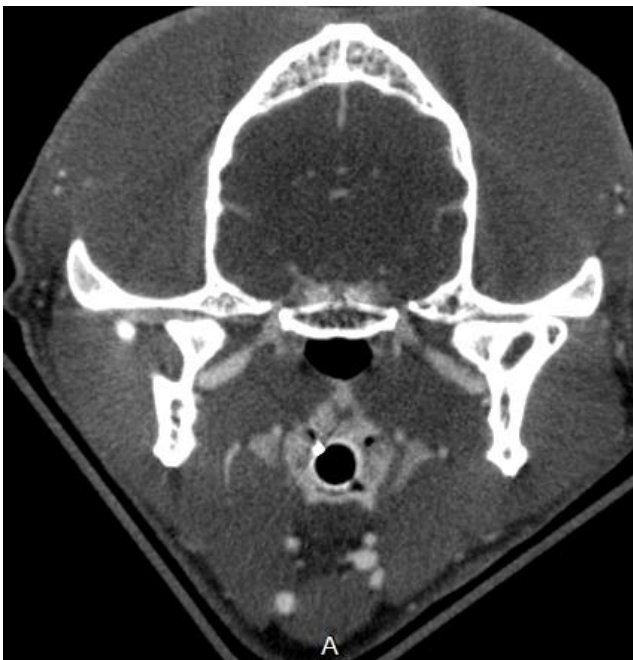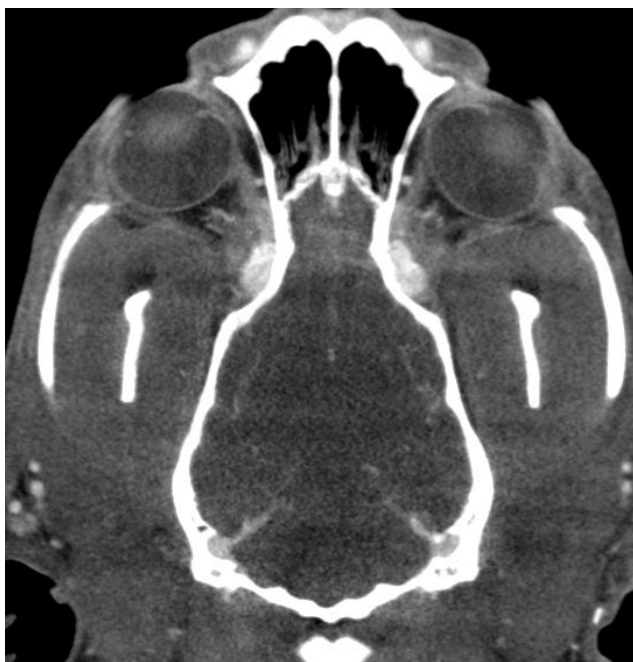
Mariela Calderon, DVM

INVOICE

75190

DATE

5-27-26





PATIENT

Luffy Melendez

SPECIES

Canine

BREED

Golden Retriever Mix

SEX

SF

AGE

6Y

WEIGHT

46.5lbs

INTERPRETED BY

Dr. Mauro Caldas MV,
CBRV

IMAGING PERFORMED BY

José L. Alvarado Bruno,
CVT - CT Scan Technician

HOSPITAL NAME

Veterinary Image Center

REFERRING VET

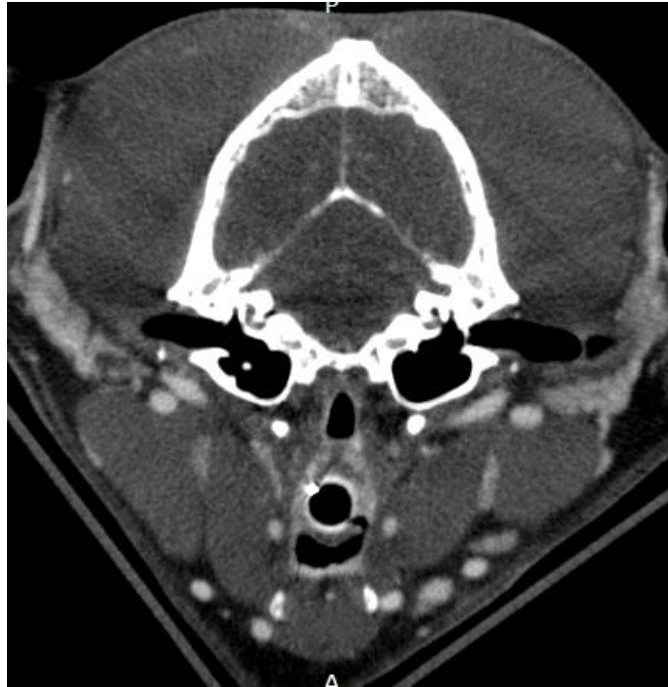Mariela Calderon, DVM

INVOICE

75190

DATE

5-27-26



The information and recommendations provided are based on the images presented by the referring veterinarian. No evaluation can be communicated regarding pathology that was not visible in the image/video clips provided.

Thank you for this referral. If the clinical or image interpretation does not parallel your findings or if I can be of any further assistance please contact me.

Dr. Mauro Caldas MV, CBRV
info@sonopath.com