PATIENT
Lily Unterspan

SPECIES
Feline

BREED
DSH

SEX
FS

AGE
13Y

WEIGHT
4kg

INTERPRETED BY
Dr. Mauro Caldas MV, CBRV

IMAGING PERFORMED BY
Vet Assistant

HOSPITAL NAME
Oregon Veterinary Dental Specialists

REFERRING VET
Dr. Donald Otten

INVOICE
75189

DATE
5-27-26

PRESENTING CLINICAL SIGNS

Invasive mass - Swelling under left eye noted in April. No previous treatment performed. Biopsy excisional performed today.

COMPUTED TOMOGRAPHIC STUDY OF THE HEAD

Plain images provided for review.

COMPUTED TOMOGRAPHIC FINDINGS

A poorly delimited soft tissue attenuated mass is noted on the face rostral to the left orbital space with lysis on the zygomatic bone measuring 2,3 x 1,6 x 1,6 cm size (long x wide x tall). The mass dislocates the left eye caudally and dorsally.

The brain is unremarkable with no evidence of mass effect or hemorrhage.

The nasal cavities present without fluid or mass. No turbinate lysis seen. Frontal sinuses contain air content on the both sides.

The dentition presents with multiple missing teeth. No periodontal lysis seen.

The mandibular and retropharyngeal lymph nodes are symmetric and with normal size and shape.

The salivary glands appear normal.

COMPUTED TOMOGRAPHIC DIAGNOSIS

- Aggressive mass on the left side of the face.

INTERPRETATION OF FINDINGS & FURTHER RECOMMENDATIONS

Primary bone neoplasm such as osteosarcoma is likely with osteomyelitis being less likely. The use of venous contrast is indicated for better evaluation of the mass limits. Pulmonary staging may be considered according to the histological finds and oncological evaluation.

SonoPath
FOSTERING THE ART OF VETERINARY MEDICINE™

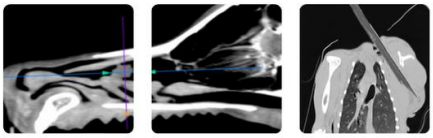

Teleradiology
Educational Teleconsultation Services™

SonoPath.com info@sonopath.com 1.800.838.4268

PATIENT

Lily Unterspan

SPECIES

Feline

BREED

DSH

SEX

FS

AGE

13Y

WEIGHT

4kg

INTERPRETED BY

Dr. Mauro Caldas MV, CBRV

IMAGING PERFORMED BY

Vet Assistant

HOSPITAL NAME

Oregon Veterinary Dental Specialists

REFERRING VET

Dr. Donald Otten

INVOICE

75189

DATE

5-27-26

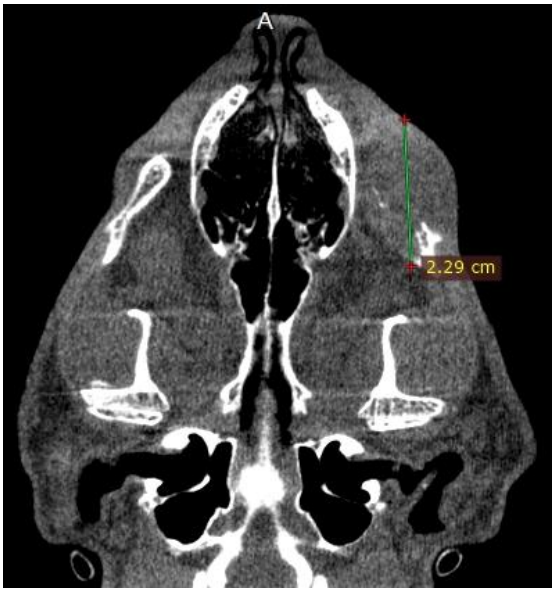

The information and recommendations provided are based on the images presented by the referring veterinarian. No evaluation can be communicated regarding pathology that was not visible in the image/video clips provided.

Thank you for this referral. If the clinical or image interpretation does not parallel your findings or if I can be of any further assistance please contact me.

Dr. Mauro Caldas MV, CBRV
info@sonopath.com