



PATIENT

Rigby Nguyen

SPECIES

Canine

BREED

Dachshund

SEX

Male Neutered

AGE

10Y

WEIGHT

7.3kg

INTERPRETED BY

Dr. Mauro Caldas MV,
CBRV

IMAGING PERFORMED BY

Mountain West
Veterinary Specialists

HOSPITAL NAME

Mountain West
Veterinary Specialists

REFERRING VET

Melanie Thompson

INVOICE

75151

DATE

5-26-26

PRESENTING CLINICAL SIGNS

Started having chronic nasal issues around march. Discharge - green and blood tinged. Decreased airflow - Owner states primarily right sided. Very congested sounding.

COMPUTED TOMOGRAPHIC STUDY OF THE HEAD

Plain and post-contrast images provided for review.

COMPUTED TOMOGRAPHIC FINDINGS

An aggressive soft tissue mass is noted within the right nasal cavity with invasion into the left nasal cavity, nasal choana, and rostral nasopharynx, with lysis on the hard palate, right maxilla, right nasal, right orbit and right sided cribriform plate measuring 5,9 x 2,0 x 2,9 cm size (long x wide x tall). Partial airway obstruction and mild rostral brain invasion on the right side is noted. Early right orbital involvement is seen with mild dorsal exophthalmos.

The tympanic bullae are normal.

Mandibular lymph nodes are asymmetrical with right sided enlargement (R=7,7 mm wide and L=4,0 mm). The retropharyngeal lymph nodes appear normal.

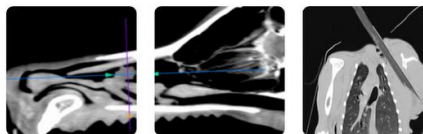
COMPUTED TOMOGRAPHIC DIAGNOSIS

- Large aggressive mass on the right nasal cavity with nasopharynx, right orbital and brain invasion.
- Right mandibular lymph node enlargement.

INTERPRETATION OF FINDINGS & FURTHER RECOMMENDATIONS

Primary neoplasm (nasal carcinoma) most likely. Fungal rhinitis cannot be ruled out but appears unlikely.

Secondary mandibular lymph node enlargement is likely metastasis. Biopsies and thoracic image staging are recommended with oncological follow up based on histological finds.



PATIENT

Rigby Nguyen

SPECIES

Canine

BREED

Dachshund

SEX

Male Neutered

AGE

10Y

WEIGHT

7.3kg

INTERPRETED BY

Dr. Mauro Caldas MV,
CBRV

IMAGING PERFORMED BY

Mountain West
Veterinary Specialists

HOSPITAL NAME

Mountain West
Veterinary Specialists

REFERRING VET

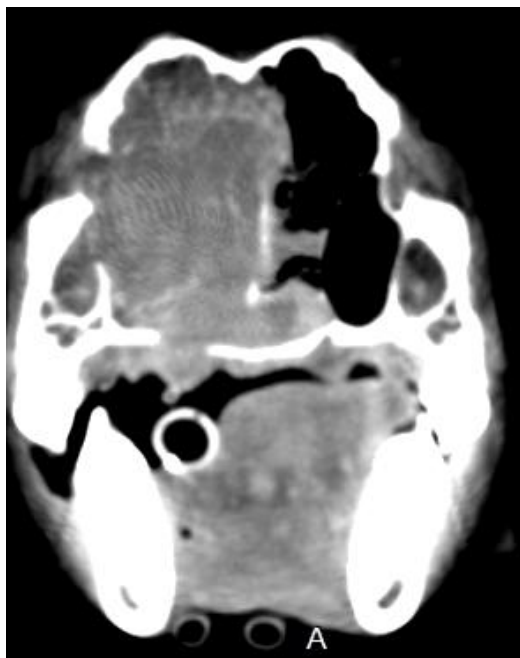
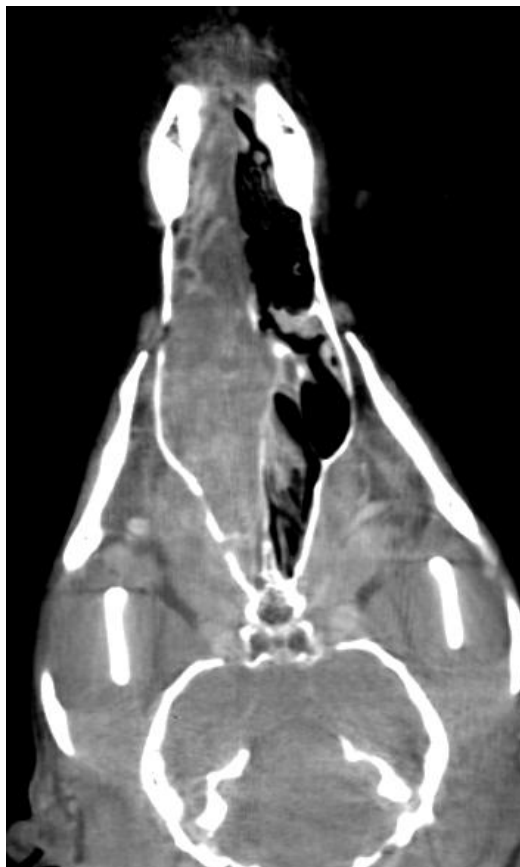Melanie Thompson

INVOICE

75151

DATE

5-26-26





PATIENT

Rigby Nguyen

SPECIES

Canine

BREED

Dachshund

SEX

Male Neutered

AGE

10Y

WEIGHT

7.3kg

INTERPRETED BY

Dr. Mauro Caldas MV,
CBRV

IMAGING PERFORMED BY

Mountain West
Veterinary Specialists

HOSPITAL NAME

Mountain West
Veterinary Specialists

REFERRING VET

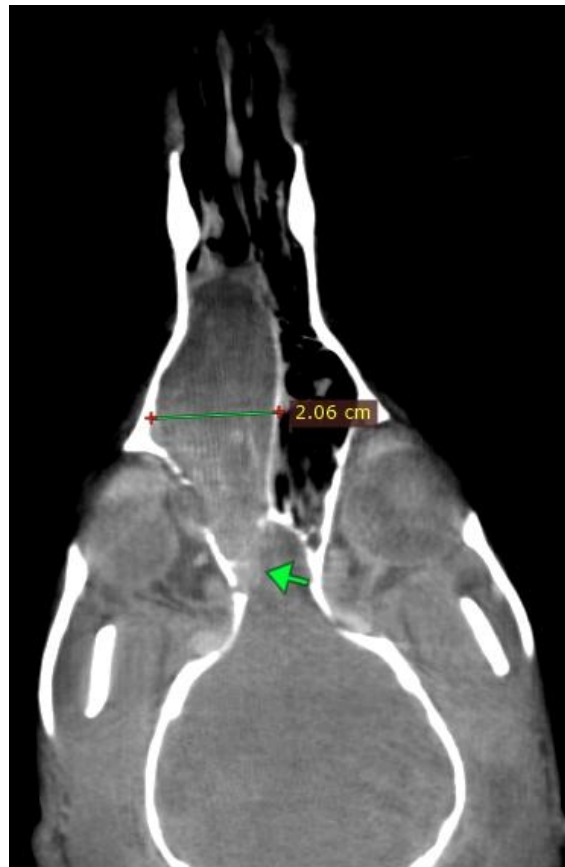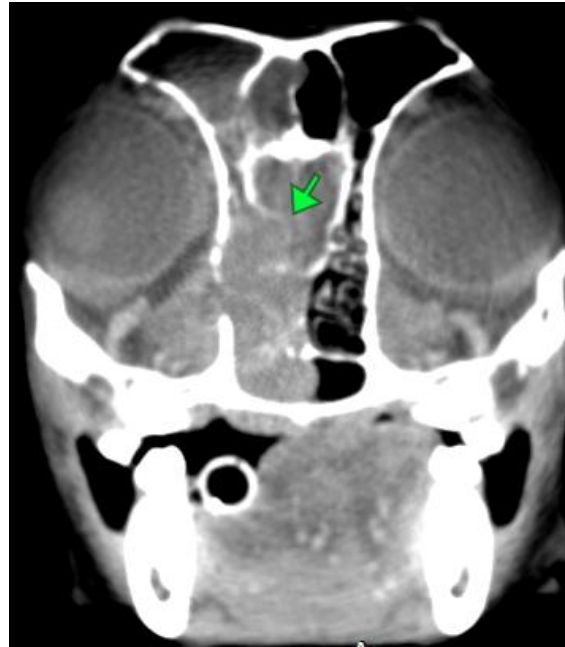
Melanie Thompson

INVOICE

75151

DATE

5-26-26





PATIENT

Rigby Nguyen

SPECIES

Canine

BREED

Dachshund

SEX

Male Neutered

AGE

10Y

WEIGHT

7.3kg

INTERPRETED BY

Dr. Mauro Caldas MV,
CBRV

IMAGING PERFORMED BY

Mountain West
Veterinary Specialists

HOSPITAL NAME

Mountain West
Veterinary Specialists

REFERRING VET

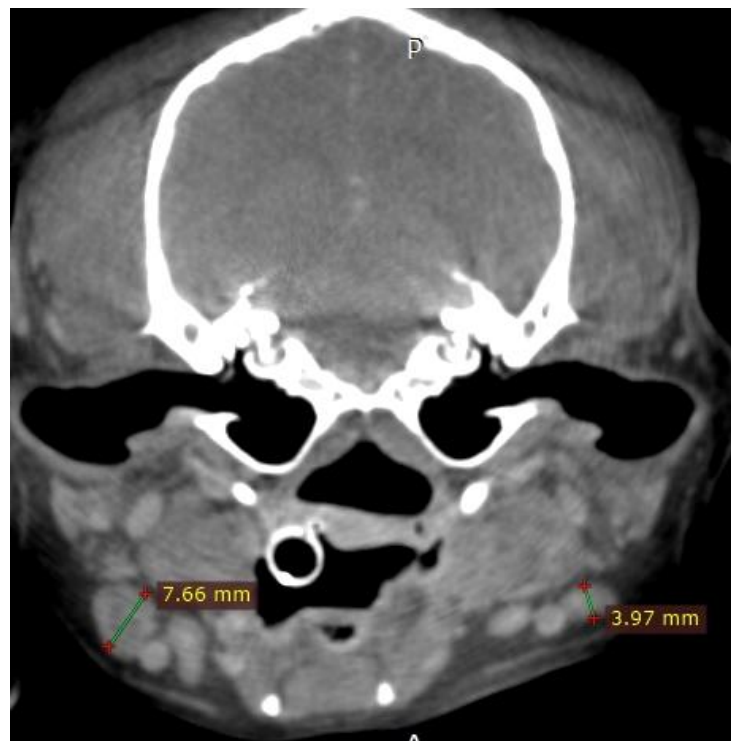
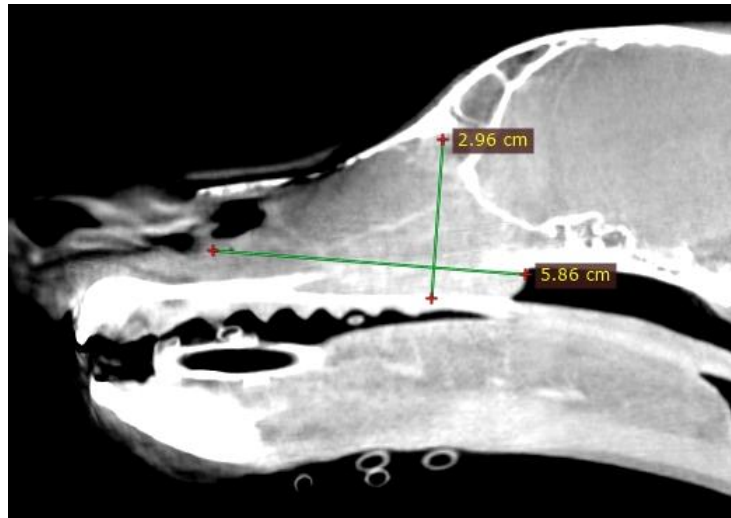
Melanie Thompson

INVOICE

75151

DATE

5-26-26



The information and recommendations provided are based on the images presented by the referring veterinarian. No evaluation can be communicated regarding pathology that was not visible in the image/video clips provided.

Thank you for this referral. If the clinical or image interpretation does not parallel your findings or if I can be of any further assistance please contact me.

Dr. Mauro Caldas MV, CBRV

info@sonopath.com