



PATIENT

Dale Levin

SPECIES

Canine

BREED

Boston Terrier

SEX

Neutered Male

AGE

9Y, 9M

WEIGHT

23lbs

INTERPRETED BY

Dr. Mauro Caldas MV,
CBRV

IMAGING PERFORMED BY

Sidney

HOSPITAL NAME

East Hill Animal
Hospital

REFERRING VET

Laura Hall

INVOICE

75154

DATE

5-26-26

PRESENTING CLINICAL SIGNS

Broken 204 is extraction needed? non painful.

COMPUTED TOMOGRAPHIC STUDY OF THE HEAD

Survey CT images provided for review.

COMPUTED TOMOGRAPHIC FINDINGS

The brain and pituitary gland are unremarkable with no evidence of intracranial mass effect.

Conchae and turbinate present with normal air pattern. No turbinate lysis seen. No nasal septum deviation seen.

Crown fractures are seen at 104 and 404. Periodontal lysis seen on 405.

Temporomandibular joints are aligned and appear normal.

The mandibular and medial retropharyngeal lymph nodes are symmetrical with a normal size and shape.

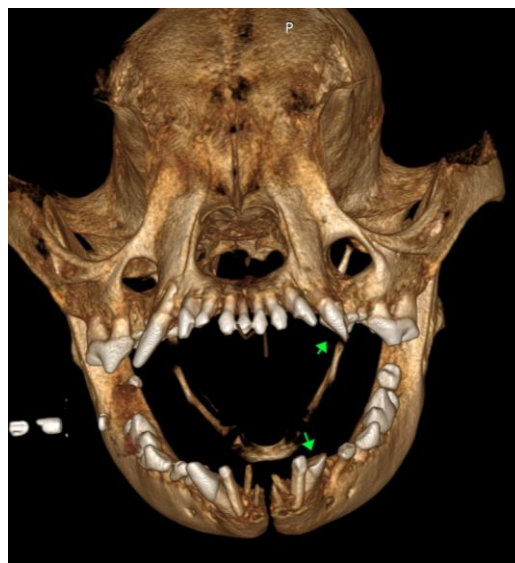The salivary glands present within normal limits.

COMPUTED TOMOGRAPHIC DIAGNOSIS

- Periosteal lysis on 405.
- Dental crown fracture on 104 and 404.

INTERPRETATION OF FINDINGS & FURTHER RECOMMENDATIONS

The dental finds with periodontal abscesses suggest extraction of 405, as clinically indicated. No obvious root or alveolar lesions seen at 104 and 404, but a dental consultation may be indicated.





PATIENT

Dale Levin

SPECIES

Canine

BREED

Boston Terrier

SEX

Neutered Male

AGE

9Y, 9M

WEIGHT

23lbs

INTERPRETED BY

Dr. Mauro Caldas MV,
CBRV

IMAGING PERFORMED BY

Sidney

HOSPITAL NAME

East Hill Animal
Hospital

REFERRING VET

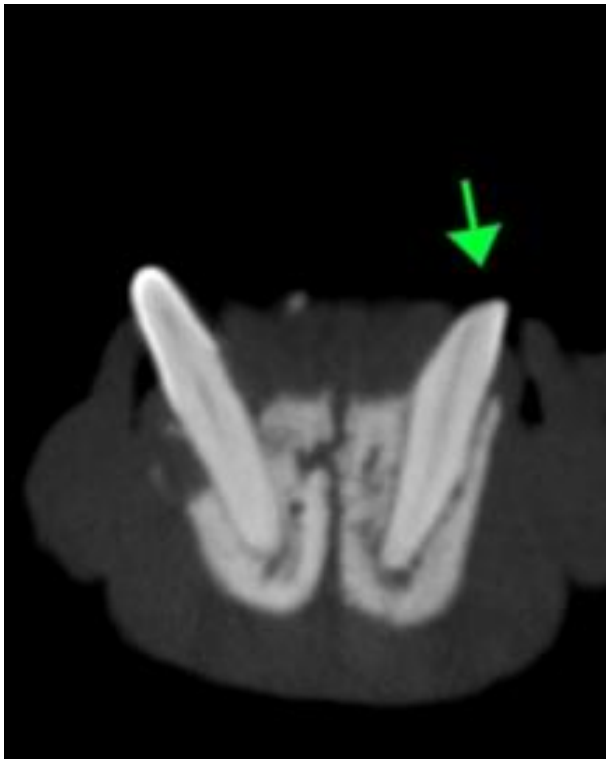
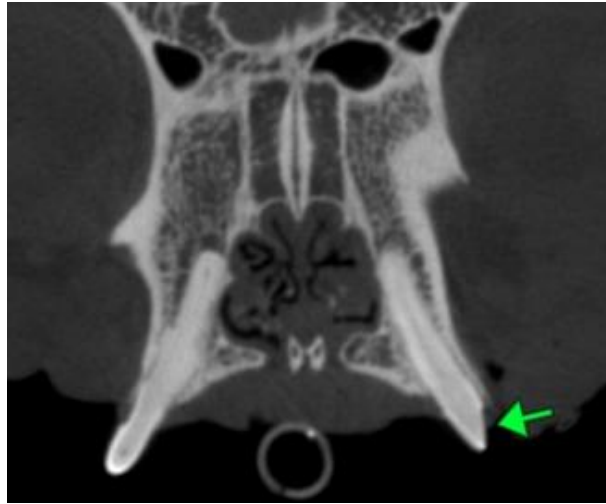
Laura Hall

INVOICE

75154

DATE

5-26-26





PATIENT

Dale Levin

SPECIES

Canine

BREED

Boston Terrier

SEX

Neutered Male

AGE

9Y, 9M

WEIGHT

23lbs

INTERPRETED BY

Dr. Mauro Caldas MV,
CBRV

IMAGING PERFORMED BY

Sidney

HOSPITAL NAME

East Hill Animal
Hospital

REFERRING VET

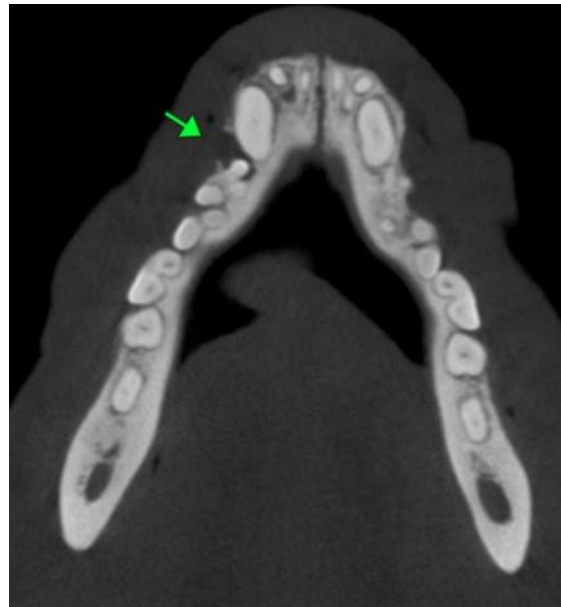
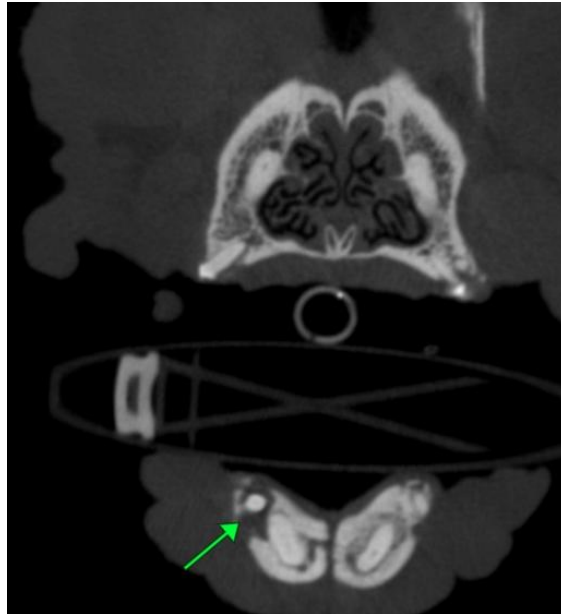
Laura Hall

INVOICE

75154

DATE

5-26-26



The information and recommendations provided are based on the images presented by the referring veterinarian. No evaluation can be communicated regarding pathology that was not visible in the image/video clips provided.

Thank you for this referral. If the clinical or image interpretation does not parallel your findings or if I can be of any further assistance please contact me.

Dr. Mauro Caldas MV, CBRV
info@sonopath.com