



PATIENT

Baxter Butts

SPECIES

Canine

BREED

Beagle

SEX

MN

AGE

10Y

WEIGHT

22lbs

INTERPRETED BY

Dr. Mauro Caldas MV,
CBRV

IMAGING PERFORMED BY

Mobile Pet Imaging

HOSPITAL NAME

Mobile Pet Imaging

REFERRING VET

Armstrong

INVOICE

75155

DATE

5-26-26

PRESENTING CLINICAL SIGNS

Pet has liver enzyme elevations ALP > ALT and liver mass noted on ultrasound.

COMPUTED TOMOGRAPHIC STUDY OF THE ABDOMEN

Survey and post contrast CT images provided for review.

COMPUTED TOMOGRAPHIC FINDINGS

The liver presents normal size and mild heterogeneous enhancement with presence of at least three hypovascular nodules; one on the left medial lobe measuring 1,6 cm wide, the second on the left lateral lobe measuring 0,9cm, and the third on the quadrate lobe measuring 3,2 cm. The gallbladder presents full and contains low density sludge.

The stomach and small intestines appear normal.

Feces with normal density and volume is present in the colon and rectum.

The spleen presents with mild enlargement. No mass or nodules seen.

The adrenal glands appear with normal size and shape.

Both kidneys present with normal size and shape. Normal contrast excretion on the both sides. There is no evidence of peritoneal effusion or peritonitis.

Medial iliac lymph nodes are symmetrical, with normal size and shape.

Urinary bladder presents with thin walls and no stones seen.

COMPUTED TOMOGRAPHIC DIAGNOSIS

- Hepatic nodules on the medial left lobe, lateral left lobe and quadrate lobe.

INTERPRETATION OF FINDINGS & FURTHER RECOMMENDATIONS

The hepatic nodules are unspecific, but the hypovascular aspect on the portal phase may suggest primary neoplasm or metastasis. US guided FNA or biopsies are indicated.



PATIENT

Baxter Butts

SPECIES

Canine

BREED

Beagle

SEX

MN

AGE

10Y

WEIGHT

22lbs

INTERPRETED BY

Dr. Mauro Caldas MV,
CBRV

**IMAGING
PERFORMED BY**

Mobile Pet Imaging

HOSPITAL NAME

Mobile Pet Imaging

REFERRING VET

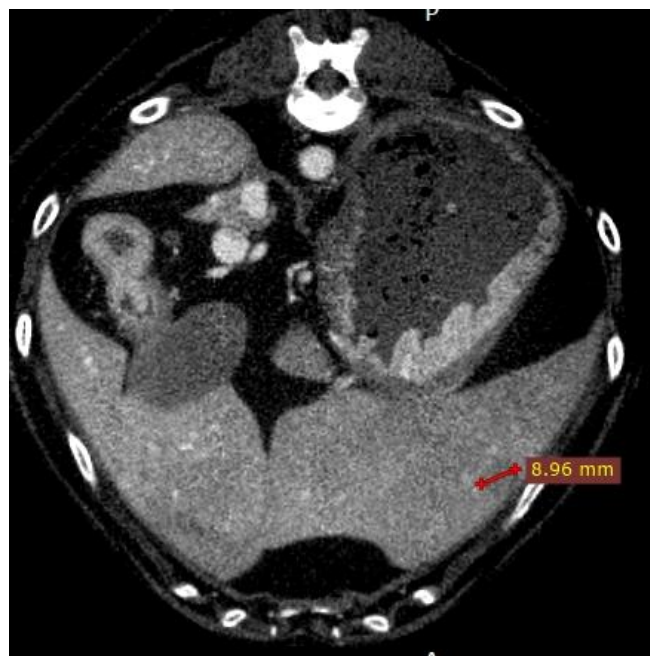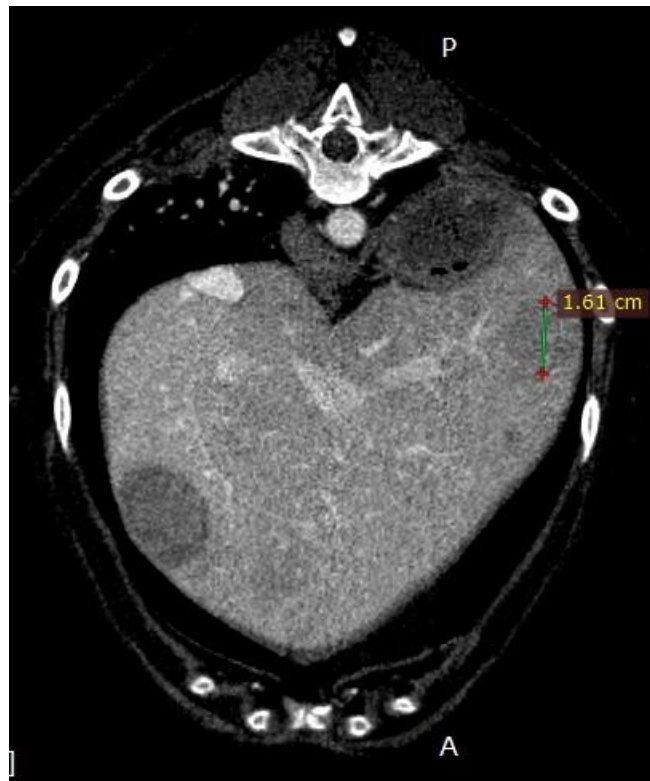Armstrong

INVOICE

75155

DATE

5-26-26





PATIENT

Baxter Butts

SPECIES

Canine

BREED

Beagle

SEX

MN

AGE

10Y

WEIGHT

22lbs

INTERPRETED BY

Dr. Mauro Caldas MV,
CBRV

**IMAGING
PERFORMED BY**

Mobile Pet Imaging

HOSPITAL NAME

Mobile Pet Imaging

REFERRING VET

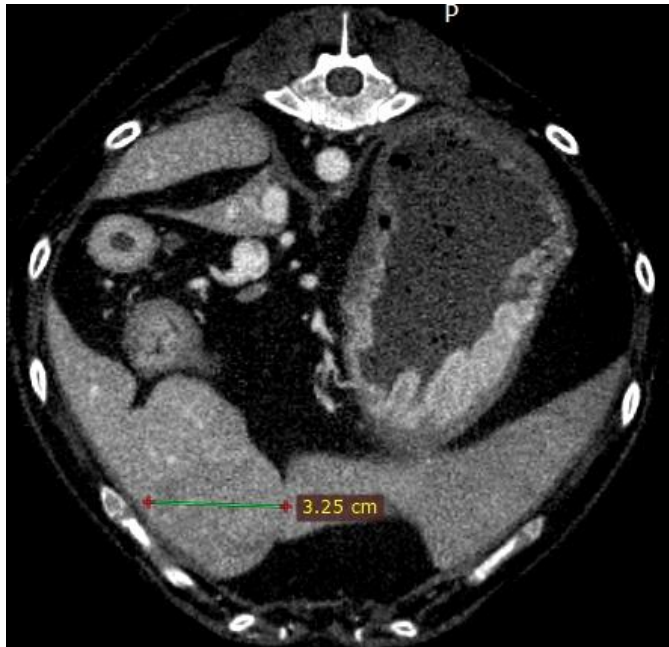
Armstrong

INVOICE

75155

DATE

5-26-26



The information and recommendations provided are based on the images presented by the referring veterinarian. No evaluation can be communicated regarding pathology that was not visible in the image/video clips provided.

Thank you for this referral. If the clinical or image interpretation does not parallel your findings or if I can be of any further assistance please contact me.

Dr. Mauro Caldas MV, CBRV

info@sonopath.com