



PATIENT

Creamy Acosta

SPECIES

Feline

BREED

Mixed

SEX

Spayed Female

AGE

17 Years

WEIGHT

10.4 lbs

INTERPRETED BY

Dr. Mauro Caldas MV,
CBRV

IMAGING PERFORMED BY

Alondra Aviles Lopez
VT

HOSPITAL NAME

Veterinary Imaging
Center

REFERRING VET

Dr. Mongil DVM

INVOICE

16304

DATE

05/15/26

PRESENTING CLINICAL SIGNS

Patient is obtunded, severely depressed and recumbent, unable to support her own weight. The neurologic examination reveals flaccid paresis with lower motor neuron disease. more severe on the right. There are conscious proprioceptive deficits in all four limbs. The deficit is asymmetrical, with hemiparesis that is more severe on the right side. There is motor activity on the left side, but no motor activity on the right. Segmental reflexes are hyporeflexic. particularly on the right side. The patient curls her head towards the left. Cranial nerve examination shows anisocoria, with the left pupil being larger than the right; both pupils are responsive to light. Other cranial nerve appears intact. Cardiovascular auscultation is normal, with no murmurs, gallops or arrhythmias detected. The suspicion for an intracranial process such as spontaneous vascular accident, trauma or meningitis. Abnormal PE/Chem/CBC/UA Results: CBC: EOS: 0.07 K/uL (0.17-1.57) CHEM: GLU 209 mg/dL (71-159) BUN 46 mg/dL (16-36) ALT 191 U/L (12-130)

COMPUTED TOMOGRAPHIC STUDY OF HEAD AND NECK

Survey and post contrast CT images provided for review

COMPUTED TOMOGRAPHIC FINDINGS

Head

The brain and pituitary gland are unremarkable with no evidence of intracranial nodules, mass, or abnormal contrast enhancement. Tympanic bullae with air filled on the both sides. No bone lysis seen. Conchae and turbinate with mild fluid attenuated content. No turbinate lysis or nasal septum deviation seen. Dentition appears normal. Temporo mandibular joints aligned and appears normal. The mandibular and medial retropharyngeal lymph are of normal size and shape. The salivary glands present within normal limits.

Neck

Thyroid glands are asymmetrical, with normal size and shape on the left side, 0,3 cm wide and oval shape mass on the right side, 2,7 x 1,6 x 1,2 cm size (long x wide x tall). Hyoid apparatus appears normal. Cervical spine misaligned on C6-7, with dorsal deviated cranial portion of C7, and mild to moderate medullary compression. Presence of two small bone fragments beside the left articular space on C6-7, 0,1 and 0,2 cm wide without luxation. No vertebral lysis seen. Spondylarthrosis seen on C3-4, C5-6 and C7-T1 Cervical muscles are symmetrical. Presence of osteophytus on the shoulders of both sides, worst on the right side

COMPUTED TOMOGRAPHIC DIAGNOSIS

- Normal brain
- C6-7 listhesis with mild medullary compression and small fractures on the left articular process
- Mass on the right thyroid lobe.
- Degenerative joint disease on both shoulders, worst on the right.

INTERPRETATION OF FINDINGS & FURTHER RECOMMENDATIONS

The C6-7 listhesis appears to be traumatic but not explain all clinical signs related. A normal brain on CT does not exclude vascular, inflammatory diseases or low-grade gliomas. A brain MRI with CSF analysis is indicated to exclude differential diagnosis and a mieloCT or MR of the cervical spine can better show the grade of medullary compressions and edema. The thyroid mass appears to be an adenoma and must be correlated with the TSH/T4 tests and an US guided FNA.



PATIENT

Creamy Acosta

SPECIES

Feline

BREED

Mixed

SEX

Spayed Female

AGE

17 Years

WEIGHT

10.4 lbs

INTERPRETED BY

Dr. Mauro Caldas MV,
CBRV

IMAGING PERFORMED BY

Alondra Aviles Lopez
VT

HOSPITAL NAME

Veterinary Imaging
Center

REFERRING VET

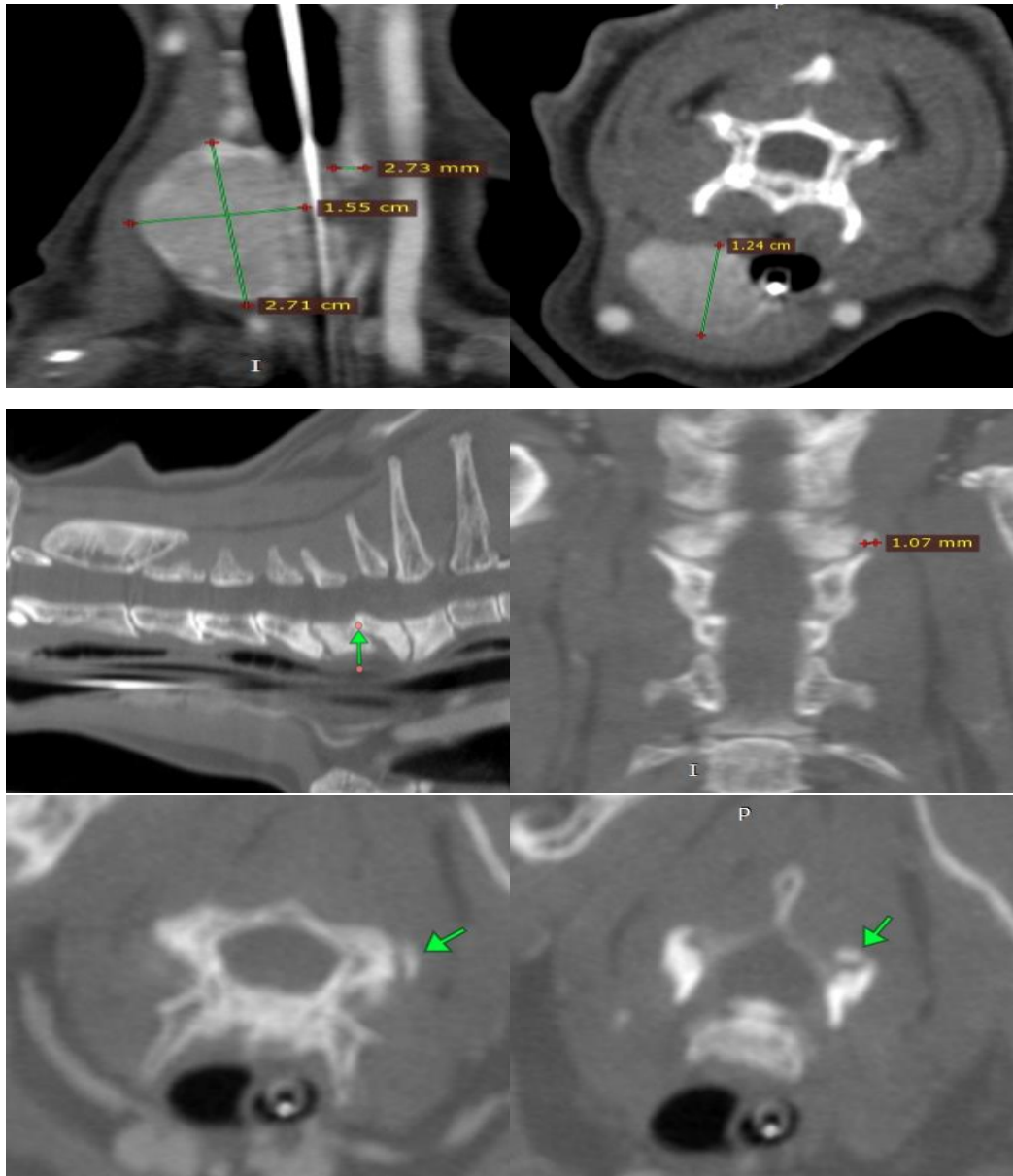
Dr. Mongil DVM

INVOICE

16304

DATE

05/15/26



The information and recommendations provided are based on the images presented by the referring veterinarian. No evaluation can be communicated regarding pathology that was not visible in the image/video clips provided.

Thank you for this referral. If the clinical or image interpretation does not parallel your findings or if I can be of any further assistance please contact me.

Dr. Mauro Caldas MV, CBRV
info@sonopath.com