



## PATIENT

Juniper Yannes

## SPECIES

Feline

## BREED

DSH

## SEX

FS

## AGE

9Y

## WEIGHT

8,8 lbs

## INTERPRETED BY

Dr. Mauro Caldas  
MV, CBRV

## IMAGING PERFORMED BY

Dr. Christopher  
LoPresto

## HOSPITAL NAME

Pet Allergy &  
Dermatology Specialists

## REFERRING VET

Dr. Christopher LoPresto

## INVOICE

74950

## DATE

05/12/2026

## PRESENTING CLINICAL SIGNS

Patient presented with ~ 1 month history of right sided jaw pain, right otitis externa, absent right palpebral reflex, decreased appetite and episodes of suspected vestibulitis, P currently on Marbofloxacin 12.5mg daily and Prednisolone 5mg daily to every other Day

## COMPUTED TOMOGRAPHIC STUDY OF THE HEAD

Plain and post-contrast images provided for review.

## COMPUTED TOMOGRAPHIC FINDINGS

The right tympanic cavity presents with fluid content, tympanic bulla lysis, and peripheral temporal bone irregular proliferative reaction extending to the right temporomandibular joint. A fluid attenuating mass on the region of the horizontal portion of the external ear canal is present measuring 2,3 x 1,6 x 1,8 cm size (long x wide x tall). The left side is air filled and no wall lysis is seen.

The brain is unremarkable with no evidence of mass effect, hemorrhage, or abnormal contrast enhancement. There's lysis on the temporal bone but no obvious meningeal enhancement. Pituitary gland is 3,9 mm tall.

The nasal cavity presents without fluid or mass. No turbinate lysis seen. The left frontal sinus contains air content. Fluid content is present on the right side with bone wall thickening on the right side.

The dentition presents with multiple missing teeth. No periodontal lysis seen.

The mandibular lymph nodes are symmetric and with normal size and shape. Left retropharyngeal lymph node enlargement, 6,7 mm wide (left 3,8 mm).

The salivary glands appear normal.

## COMPUTED TOMOGRAPHIC DIAGNOSIS

- Right tympanic bulla with otitis media, lysis, and bone reaction on the temporal bone with fluid containing mass on the right external ear canal.
- Right sided retropharyngeal enlargement
- Right frontal sinus with fluid and bone thickening.

## INTERPRETATION OF FINDINGS & FURTHER RECOMMENDATIONS

Right sided otitis media with osteomyelitis and abscess are most likely with damage on the right temporomandibular joint. An aggressive neoplasm can't be ruled out. Secondary lymph node enlargement is present (reactive most likely). Bulla osteotomy with biopsies and culture is indicated.



## PATIENT

Juniper Yannes

## SPECIES

Feline

## BREED

DSH

## SEX

FS

## AGE

9Y

## WEIGHT

8,8 lbs

## INTERPRETED BY

Dr. Mauro Caldas  
MV, CBRV

## IMAGING PERFORMED BY

Dr. Christopher  
LoPresto

## HOSPITAL NAME

Pet Allergy &  
Dermatology Specialists

## REFERRING VET

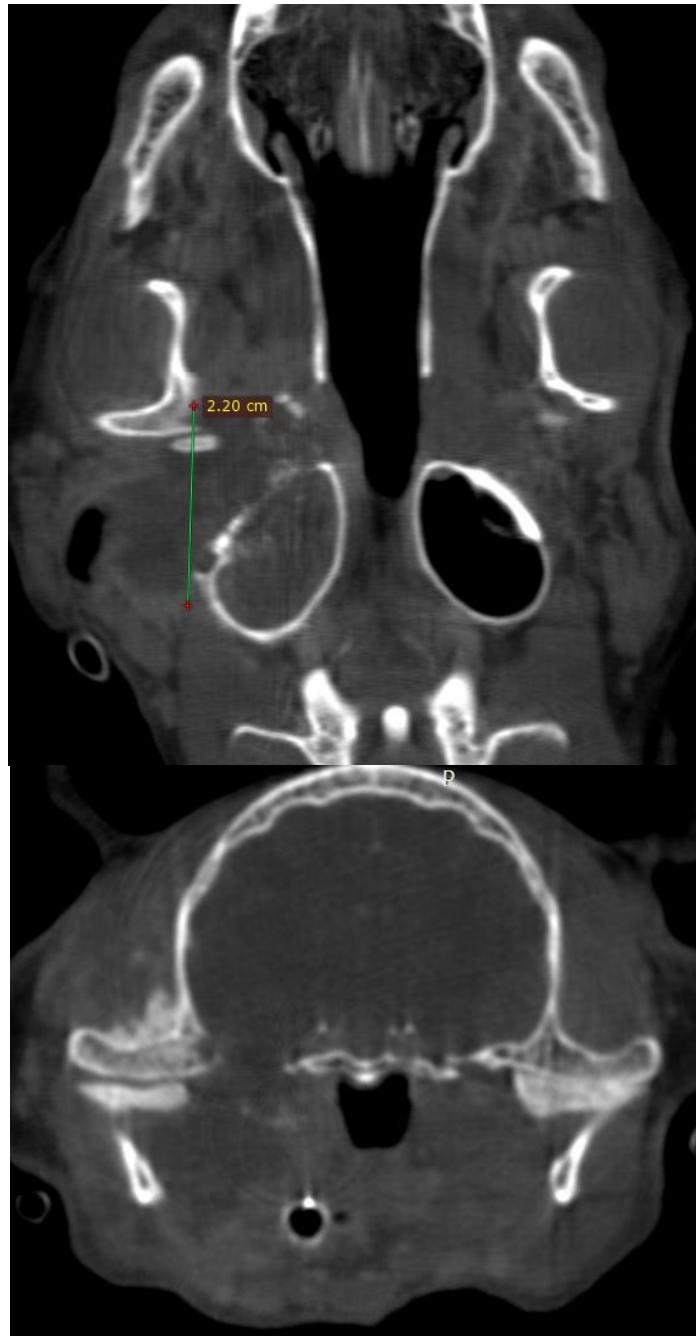Dr. Christopher LoPresto

## INVOICE

74950

## DATE

05/12/2026





## PATIENT

Juniper Yannes

## SPECIES

Feline

## BREED

DSH

## SEX

FS

## AGE

9Y

## WEIGHT

8,8 lbs

## INTERPRETED BY

Dr. Mauro Caldas  
MV, CBRV

## IMAGING PERFORMED BY

Dr. Christopher  
LoPresto

## HOSPITAL NAME

Pet Allergy &  
Dermatology Specialists

## REFERRING VET

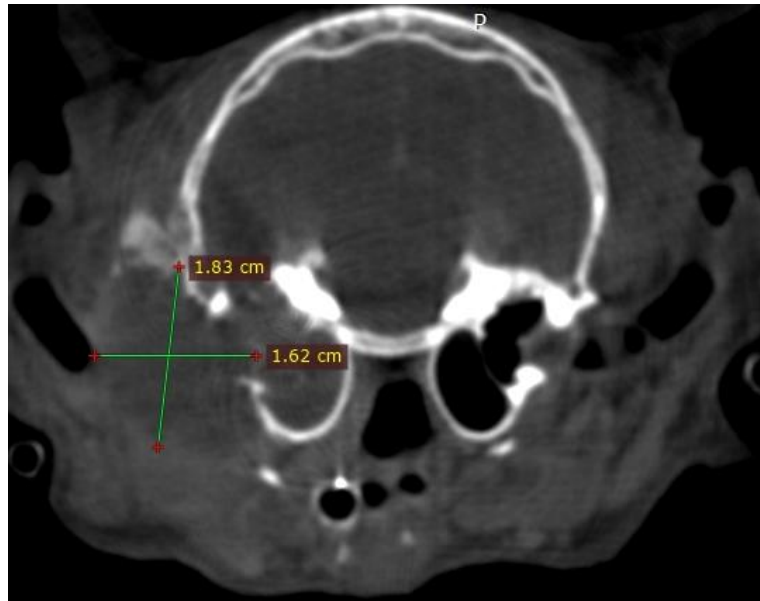
Dr. Christopher LoPresto

## INVOICE

74950

## DATE

05/12/2026



The information and recommendations provided are based on the images presented by the referring veterinarian. No evaluation can be communicated regarding pathology that was not visible in the image/video clips provided.

Thank you for this referral. If the clinical or image interpretation does not parallel your findings or if I can be of any further assistance please contact me.

**Dr. Mauro Caldas MV, CBRV**

[info@sonopath.com](mailto:info@sonopath.com)