



PATIENT

Joaquin Rodriguez

SPECIES

Canine

BREED

Chihuahua

SEX

MN

AGE

15Y

WEIGHT

6lbs

INTERPRETED BY

Dr. Mauro Caldas MV,
CBRV

IMAGING PERFORMED BY

Mobile Pet Imaging

HOSPITAL NAME

Mobile Pet Imaging

REFERRING VET

Armstrong

INVOICE

74952

DATE

5-12-26

PRESENTING CLINICAL SIGNS

The pet was at the vet for congestion. It had a nasal fistula. The pet has been treated with clindamycin and got better for a couple of weeks, but now it's pet has some epistaxis in the left nostril.

COMPUTED TOMOGRAPHIC STUDY OF THE HEAD

Plain and post-contrast images provided for review.

COMPUTED TOMOGRAPHIC FINDINGS

The left nasal cavity presents with an aggressive soft tissue mass invading the right side, nasal choana, rostral nasopharynx with extensive lysis on the hard palate, left maxilla, left pterygoid and left orbit, measuring 4,1 x 2,6 x 2,8 cm size (long x wide x tall). Complete airway obstruction and mild brain invasion on the left ventral portion of the rostral region is also seen. Early left orbital involvement is seen with mild dorsal exophthalmos. Tympanic bullae are normal

The mandibular and retropharyngeal lymph nodes appear normal.

COMPUTED TOMOGRAPHIC DIAGNOSIS

- Large aggressive mass in the left nasal cavity with nasopharynx, left orbital, and brain invasion.

INTERPRETATION OF FINDINGS & FURTHER RECOMMENDATIONS

Primary neoplasm (nasal carcinoma) is most likely. Fungal rhinitis cannot be ruled out but appears unlikely. Biopsies and thoracic image staging are recommended with oncological follow up based on histological finds.



PATIENT

Joaquin Rodriguez

SPECIES

Canine

BREED

Chihuahua

SEX

MN

AGE

15Y

WEIGHT

6lbs

INTERPRETED BY

Dr. Mauro Caldas MV,
CBRV

**IMAGING
PERFORMED BY**

Mobile Pet Imaging

HOSPITAL NAME

Mobile Pet Imaging

REFERRING VET

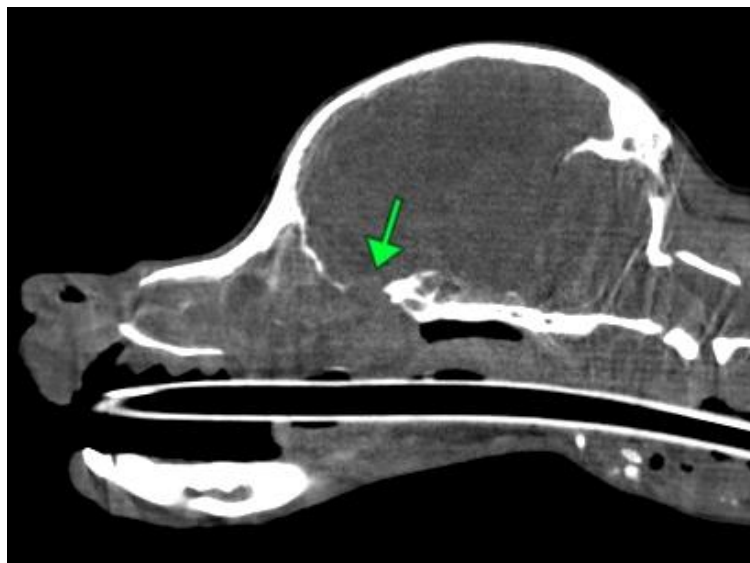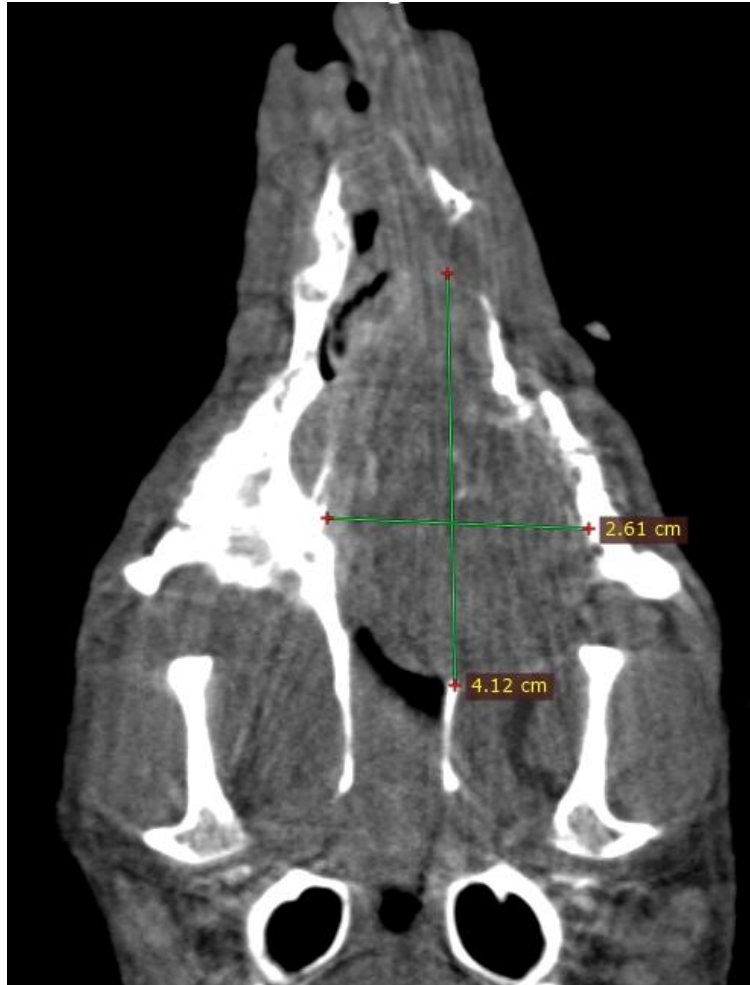Armstrong

INVOICE

74952

DATE

5-12-26





PATIENT

Joaquin Rodriguez

SPECIES

Canine

BREED

Chihuahua

SEX

MN

AGE

15Y

WEIGHT

6lbs

INTERPRETED BY

Dr. Mauro Caldas MV,
CBRV

**IMAGING
PERFORMED BY**

Mobile Pet Imaging

HOSPITAL NAME

Mobile Pet Imaging

REFERRING VET

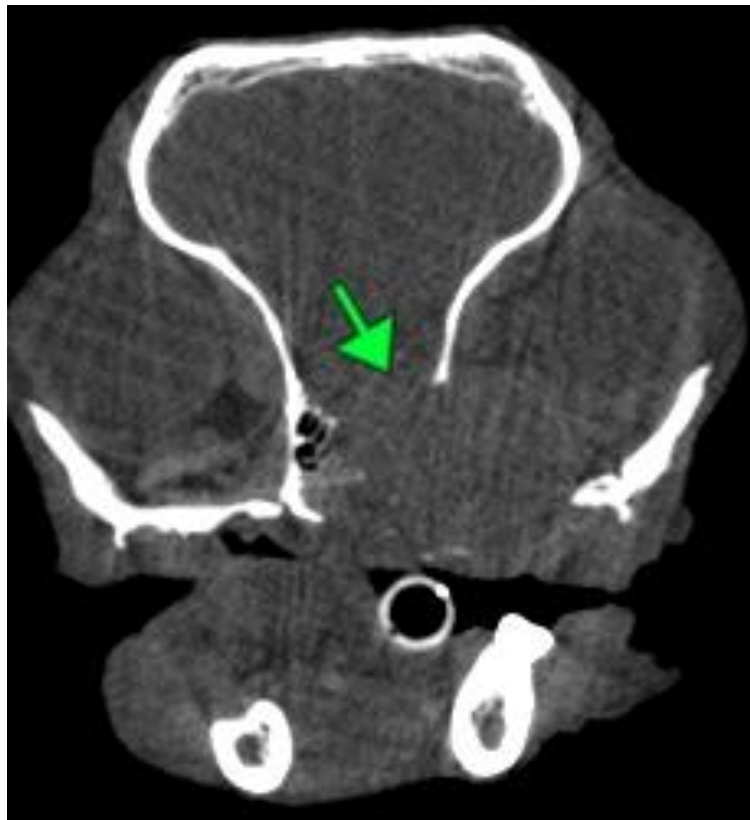
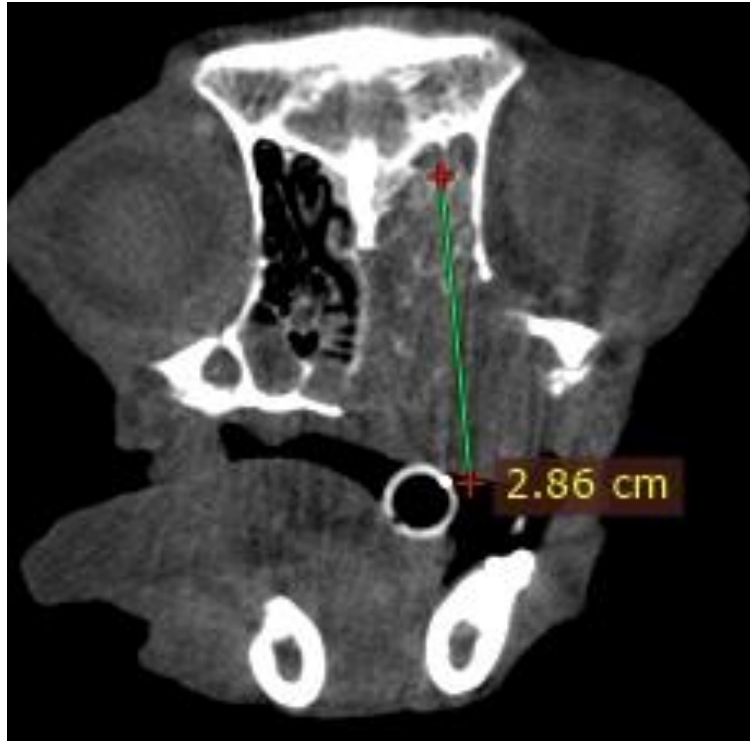
Armstrong

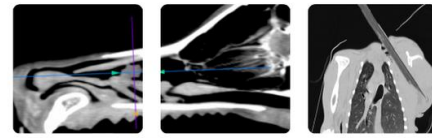
INVOICE

74952

DATE

5-12-26





PATIENT

Joaquin Rodriguez

SPECIES

Canine

BREED

Chihuahua

SEX

MN

AGE

15Y

WEIGHT

6lbs

INTERPRETED BY

Dr. Mauro Caldas MV,
CBRV

**IMAGING
PERFORMED BY**

Mobile Pet Imaging

HOSPITAL NAME

Mobile Pet Imaging

REFERRING VET

Armstrong

INVOICE

74952

DATE

5-12-26

The information and recommendations provided are based on the images presented by the referring veterinarian. No evaluation can be communicated regarding pathology that was not visible in the image/video clips provided.

Thank you for this referral. If the clinical or image interpretation does not parallel your findings or if I can be of any further assistance please contact me.

Dr. Mauro Caldas MV, CBRV

info@sonopath.com