

DATE PRESENTING CLINICAL SIGNS

8/28/21

Elevated GGT, anorexia, pancreatitis.

INTERPRETED BY CYTOLOGY SUBMISSION

U/S Guided FNA: Pancreatic mass

L.D. McGill, DVM,
Ph.D, DACVP

OBSERVATIONS

Pancreatic mass: Submitted are 3 excellent videos of excellent collections of cells from the pancreatic region in Leo. The cellularity includes massive numbers of neutrophils with scattered lymphocytes and macrophages. There is degenerate debris including saponified fat and saponified protein scattered throughout. Bacteria were not identified. The inflammatory process is almost entirely neutrophilic with some of the neutrophils undergoing slight degeneration. Malignant characteristics are not identified.

PATIENT

Leo Larson

SPECIES

Feline

ULTRASONOGRAPHIC DIAGNOSIS

A 3.04 x 4.34 cm mid cranial abdominal, hypoechoic mass was noted. This is most consistent with abscessation. This may be non-neoplastic but appears to be deriving from the left limb of the pancreas. A parenchymal portion of the structure measures 2.0 cm. Regional inflammation was noted.

BREED

DSH

INTERPRETATION OF THE FINDINGS & FURTHER RECOMMENDATIONS

SEX Pancreatic mass - Severe suppurative inflammation consistent with an abscess

Male Neutered

COMMENTS

The cellularity in this collection is characteristic of a rather severe suppurative response which is likely an abscess. There is no suggestion of malignancy in the collection. I did not identify bacteria but they may be involved. Very likely this is due to a release of pancreatic enzymes that are degenerating cells around this region causing the abscess. Continued treatment for inflammation or even draining the abscess may be beneficial. Antibiotics can be suggested but may not be helpful. A guarded prognosis is always warranted in these cases of severe localized inflammatory pancreatitis.

AGE

13 years

WEIGHT

12.7 lbs

HOSPITAL NAME

Rockaway Animal
Hospital

REFERRING VET

Dr. Maniar

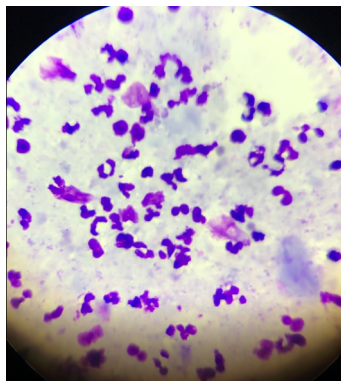
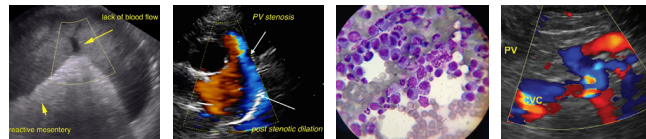


Image shows neutrophils and degenerate cells collected from the pancreatic abscess in Leo. Note the inspissated protein in the lower right.

INVOICE NUMBER

9081



DATE

8/28/21

INTERPRETED BY

L.D. McGill, DVM,
Ph.D, DACVP

The information and recommendations provided are based on the images presented by the referring veterinarian. No evaluation can be communicated regarding pathology that was not visible in the image/video clips provided.

Thank you for this referral. If the clinical or image interpretation does not parallel your findings or if I can be of any further assistance please contact me.

PATIENT

Leo Larson

L.D. McGill, DVM, Ph.D., DACVP

8288 Top of the World Drive
Cottonwood Heights, UT 84121

ldmcgill.vetpath@gmail.com
cell: 801-865-1220

SPECIES

Feline

BREED

DSH

SEX

Male Neutered

AGE

13 years

WEIGHT

12.7 lbs

HOSPITAL NAME

Rockaway Animal
Hospital

REFERRING VET

Dr. Maniar

INVOICE NUMBER

9081