



## PATIENT

Trudy Caton

## SPECIES

Canine

## BREED

American Bully

## SEX

FS

## AGE

9Y

## WEIGHT

45lbs

## INTERPRETED BY

Dr. Leticia Utsch MV

## IMAGING PERFORMED BY

Northshore Vet Techs

## HOSPITAL NAME

Northshore Veterinary  
Hospital

## REFERRING VET

Michaela Edgers, DVM

## INVOICE

75328

## DATE

6-8-26

## PRESENTING CLINICAL SIGNS

Presurgical screening for metastasis.

1 cm nodular mass right forelimb - Aspirate reveals mesenchymal cells.

Concerns for STS.

Surgery with specialist being planned.

No clinical signs of cardiopulmonary disease

Abnormal PE/Chem/CBC/UA Results: 1 cm nodular mass right deltoid region. CBC/Chem WNL

## RADIOGRAPHIC STUDY OF THE THORAX

Radiographs of the thorax in three imaging planes are provided for review.

## RADIOGRAPHIC FINDINGS

The lungs are normally insufflated and transparent.

The heart and pulmonary vasculature appear normal.

The trachea and principal bronchi have a normal diameter.

The mediastinum and pleural space also appear normal.

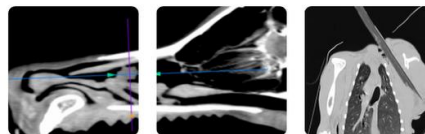
Ventral spondylosis is noted in the thoracic spine (likely incidental).

## RADIOGRAPHIC DIAGNOSIS

- Normal appearing thorax. No evidence of lung metastasis seen.

## INTERPRETATION OF FINDINGS & FURTHER RECOMMENDATIONS

No radiographic evidence of pulmonary metastatic disease is identified. The cardiac silhouette and remaining thoracic structures are within normal limits. Surgical excision and histopathologic evaluation are recommended for definitive diagnosis and grading. Prognosis and the need for additional staging or therapy will depend on the final histopathologic classification and surgical margins.



## PATIENT

Trudy Caton

## SPECIES

Canine

## BREED

American Bully

## SEX

FS

## AGE

9Y

## WEIGHT

45lbs

## INTERPRETED BY

Dr. Leticia Utsch MV

## IMAGING PERFORMED BY

Northshore Vet Techs

## HOSPITAL NAME

Northshore Veterinary  
Hospital

## REFERRING VET

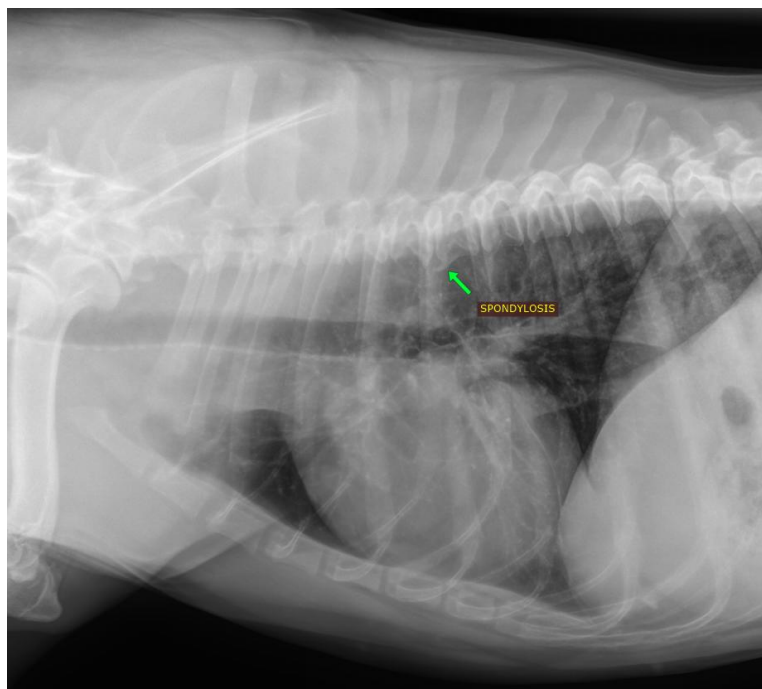
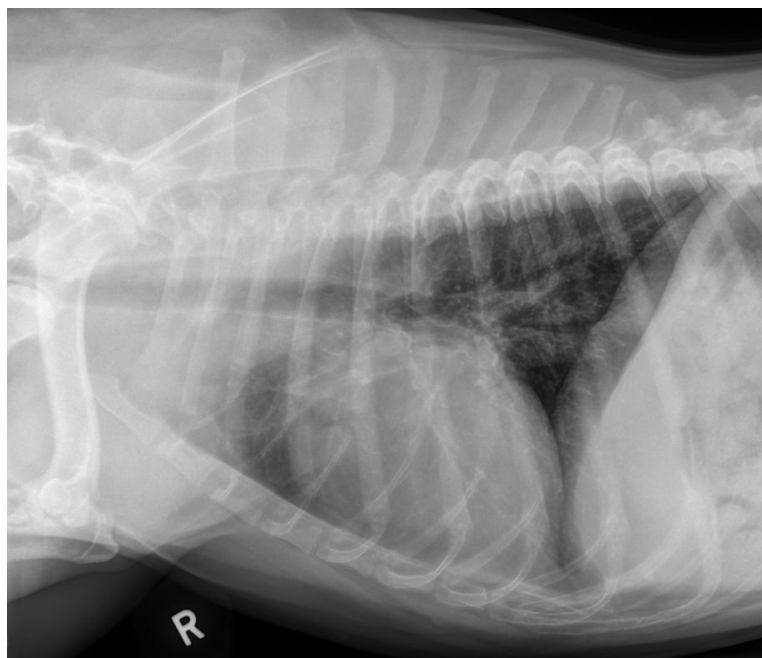
Michaela Edgers, DVM

## INVOICE

75328

## DATE

6-8-26





## PATIENT

Trudy Caton

## SPECIES

Canine

## BREED

American Bully

## SEX

FS

## AGE

9Y

## WEIGHT

45lbs

## INTERPRETED BY

Dr. Leticia Utsch MV

## IMAGING PERFORMED BY

Northshore Vet Techs

## HOSPITAL NAME

Northshore Veterinary  
Hospital

## REFERRING VET

Michaela Edgers, DVM

## INVOICE

75328

## DATE

6-8-26

The information and recommendations provided are based on the images presented by the referring veterinarian. No evaluation can be communicated regarding pathology that was not visible in the image/video clips provided.

Thank you for this referral. If the clinical or image interpretation does not parallel your findings or if I can be of any further assistance please contact me.

**Dr. Leticia Utsch MV**

[info@sonopath.com](mailto:info@sonopath.com)