



PATIENT

Bella Ward-Wallace

SPECIES

K9

BREED

American Pitbull

SEX

Female Spayed

AGE

9

WEIGHT

56.5lbs

INTERPRETED BY

Dr. Leticia Utsch MV

IMAGING PERFORMED BY

DTLAvets

HOSPITAL NAME

DTLAvets

REFERRING VET

Dr. Castaneda

INVOICE

75334

DATE

6-8-26

PRESENTING CLINICAL SIGNS

extremely proactive owner; routine senior screen - bicavital rads are submitted; today P presents for bilateral conjunctivitis

RADIOGRAPHIC STUDY OF THE THORAX AND ABDOMEN

Radiographs of the thorax and abdomen in three imaging planes are provided for review.

RADIOGRAPHIC FINDINGS

Thorax

The lungs are normally insufflated and transparent.

The heart and pulmonary vasculature appear normal.

The trachea and principal bronchi have a normal diameter.

The mediastinum and pleural space also appear normal.

Thoracic spondylosis is seen (likely incidental).

Abdomen

The stomach is moderately filled with alimentary content and gas.

The colon is mildly filled with normal appearing feces and gas.

The small intestines are normally filled with fluid and gas.

Liver, kidney and spleen have a normal size and shape.

The peritoneal and retroperitoneal detail are normal appearing.

The urinary bladder has a normal opacity. No stones seen.

There is intervertebral disc space narrowing, with sclerotic margins and severe bridging spondylosis at L7-S1.

RADIOGRAPHIC DIAGNOSIS

- Normal appearing thorax and abdomen;
- Changes seen in L7-S1 may be related to lumbosacral degenerative stenosis.

INTERPRETATION OF FINDINGS & FURTHER RECOMMENDATIONS

No significant radiographic abnormalities are identified within the thorax or abdomen.

Changes at L7-S1 may be associated with lumbosacral degenerative stenosis. Correlation with neurologic examination findings is recommended to determine the clinical relevance.



PATIENT

Bella Ward-Wallace

SPECIES

K9

BREED

American Pitbull

SEX

Female Spayed

AGE

9

WEIGHT

56.5lbs

INTERPRETED BY

Dr. Leticia Utsch MV

IMAGING PERFORMED BY

DTLAvets

HOSPITAL NAME

DTLAvets

REFERRING VET

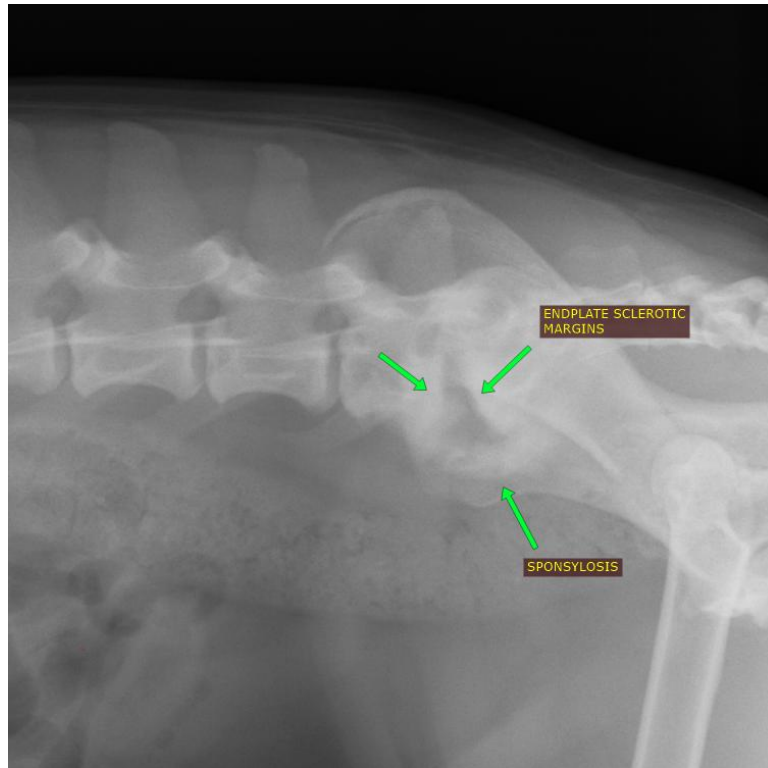
Dr. Castaneda

INVOICE

75334

DATE

6-8-26



The information and recommendations provided are based on the images presented by the referring veterinarian. No evaluation can be communicated regarding pathology that was not visible in the image/video clips provided.

Thank you for this referral. If the clinical or image interpretation does not parallel your findings or if I can be of any further assistance please contact me.

Dr. Leticia Utsch MV
info@sonopath.com