



PATIENT

Willow Diltz

SPECIES

Canine

BREED

Golden Doodle

SEX

Spayed

AGE

4Y, 9M

WEIGHT

58.5lbs

INTERPRETED BY

Dr. Leticia Utsch MV

IMAGING PERFORMED BY

Allison

HOSPITAL NAME

Elizabeth Animal Hospital

REFERRING VET

Leon Anderson, DVM

INVOICE

75563

DATE

6-17-26

PRESENTING CLINICAL SIGNS

Willow plays ball every day and the past couple of days she has been panting differently. It is very noisy and almost sounds like a purr. It has been for a couple of days now; she hasn't had this happen before. She said that she also seems not as active, like she will play ball for a little and then stops. Normally they have to force her to stop playing. She is eating a lot more grass as well. She is going out of town and wants to make sure she is ok. No vomiting, hacking or coughing paired with it. She will settle and be normal after 10 mins.

RADIOGRAPHIC STUDY OF THE NECK AND THORAX

Radiographs of the thorax in three imaging planes and the neck in two imaging planes are provided for review.

RADIOGRAPHIC FINDINGS

Thorax

The lungs are normally insufflated and transparent.

The heart and pulmonary vasculature appear normal.

The trachea and principal bronchi have a normal diameter.

The mediastinum and pleural space also appear normal.

Bone structures do not show any significant changes.

Neck

Hyoid bones and laryngeal cartilages are in normal position and have a normal opacity.

The laryngeal air column is normal.

The cervical trachea has a normal diameter.

The soft palate has a normal size and length.

RADIOGRAPHIC DIAGNOSIS

- Normal appearing thorax and neck radiographs.

INTERPRETATION OF FINDINGS & FURTHER RECOMMENDATIONS

No significant radiographic abnormalities are identified within the neck or thorax. The reported clinical signs may reflect upper airway disease not apparent radiographically, including laryngeal paralysis, pharyngeal and/ or laryngeal inflammation, non-radiopaque laryngeal foreign body. Consider upper airway evaluation, including a sedated laryngoscopic examination.



PATIENT

Willow Diltz

SPECIES

Canine

BREED

Golden Doodle

SEX

Spayed

AGE

4Y, 9M

WEIGHT

58.5lbs

INTERPRETED BY

Dr. Leticia Utsch MV

IMAGING PERFORMED BY

Allison

HOSPITAL NAME

Elizabeth Animal Hospital

REFERRING VET

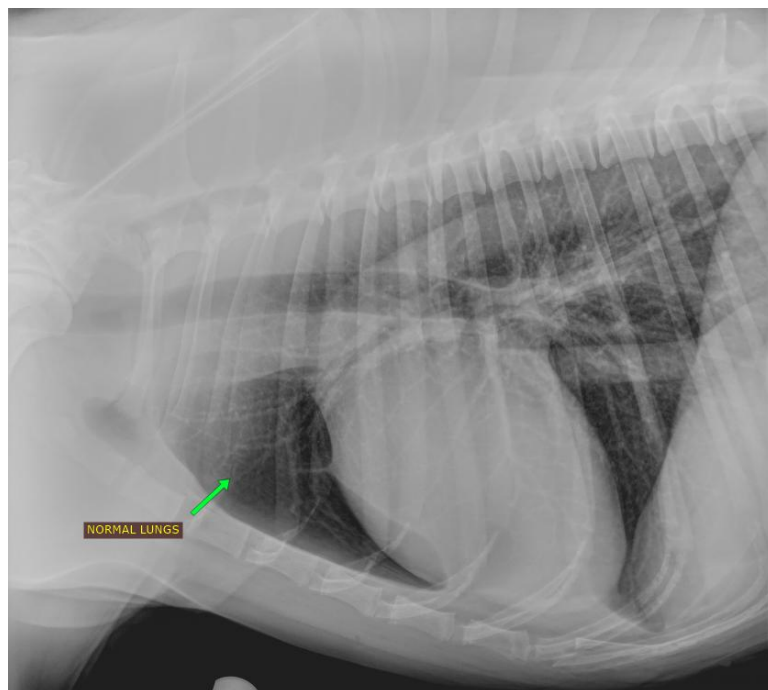
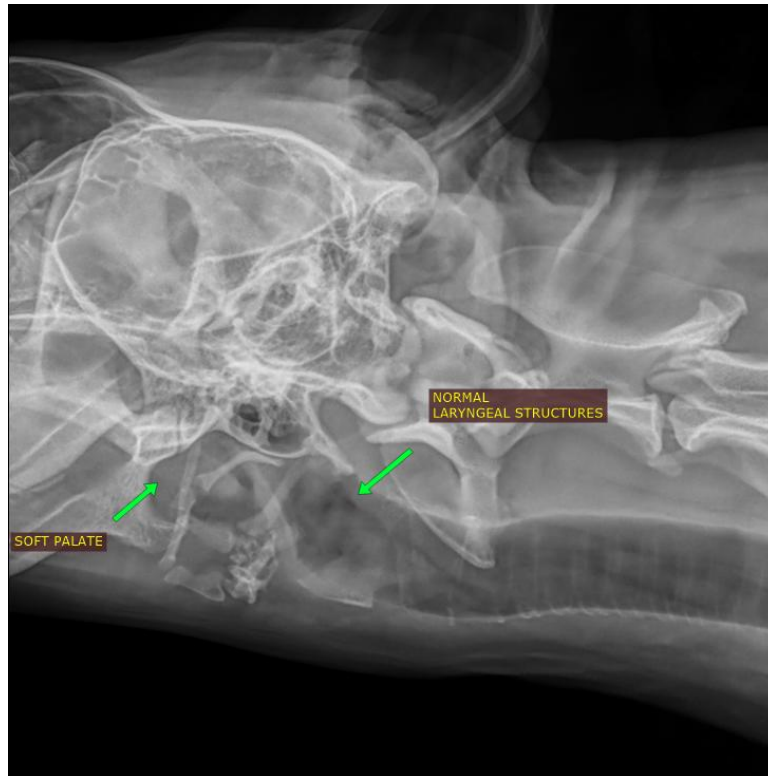
Leon Anderson, DVM

INVOICE

75563

DATE

6-17-26





PATIENT

Willow Diltz

SPECIES

Canine

BREED

Golden Doodle

SEX

Spayed

AGE

4Y, 9M

WEIGHT

58.5lbs

INTERPRETED BY

Dr. Leticia Utsch MV

IMAGING PERFORMED BY

Allison

HOSPITAL NAME

Elizabeth Animal
Hospital

REFERRING VET

Leon Anderson, DVM

INVOICE

75563

DATE

6-17-26

The information and recommendations provided are based on the images presented by the referring veterinarian. No evaluation can be communicated regarding pathology that was not visible in the image/video clips provided.

Thank you for this referral. If the clinical or image interpretation does not parallel your findings or if I can be of any further assistance please contact me.

Dr. Leticia Utsch MV

info@sonopath.com