



PATIENT

Odin Austria

SPECIES

Canine

BREED

Shepherd Mix

SEX

Neutered

AGE

5Y

WEIGHT

76.6lbs

INTERPRETED BY

Dr. Leticia Utsch MV

IMAGING PERFORMED BY

Allison

HOSPITAL NAME

Elizabeth Animal Hospital

REFERRING VET

Kim Allyn, DVM

INVOICE

75561

DATE

6-17-26

PRESENTING CLINICAL SIGNS

Odin has been not wanting to eat the past couple days and is lethargic. Usually eats dry dog food but gave him some canned food and he ate a small amount of it which is strange because he usually eats all of it. Usually he is flying doing laps around the barn but he was walking along slowly. Followed him around this morning and he had a normal stool. He threw up a couple spots of clear liquid, bright yellow. He has a bad habit of eating horse poop and he has been wanting to eat chicken poop and shavings lately. He has had this happen before where he wouldn't eat a meal or two but then eats grass and returns back to normal. He doesn't know of anything that he could have gotten into or eaten other than the horse and chicken poop. He plays with his toys, but he just tears them up, doesn't eat them.

RADIOGRAPHIC STUDY OF THE ABDOMEN

Radiographs of the abdomen in three imaging planes are provided for review.

RADIOGRAPHIC FINDINGS

The stomach is empty.

The colon is normally filled with feces and gas.

The small intestines are normally filled with fluid and gas.

Liver, kidney and spleen have a normal size and shape.

The peritoneal and retroperitoneal detail are normal appearing.

The urinary bladder has a normal opacity. No stones seen.

Bone structures are normal.

RADIOGRAPHIC DIAGNOSIS

- Normal appearing abdominal radiographs.

INTERPRETATION OF FINDINGS & FURTHER RECOMMENDATIONS

The abdominal radiographs are normal. No radiopaque foreign body or evidence of gastrointestinal obstruction seen. Given the clinical history, consider likely dietary indiscretion, inflammatory or infectious gastroenteritis. Correlation with physical examination findings and laboratory results is recommended. Recommend supportive care, including dietary management, hydration support, and symptomatic therapy as clinically indicated. If clinical signs persist or worsen, consider laboratory exams and abdominal ultrasonography for further investigation.



PATIENT

Odin Austria

SPECIES

Canine

BREED

Shepherd Mix

SEX

Neutered

AGE

5Y

WEIGHT

76.6lbs

INTERPRETED BY

Dr. Leticia Utsch MV

IMAGING PERFORMED BY

Allison

HOSPITAL NAME

Elizabeth Animal Hospital

REFERRING VET

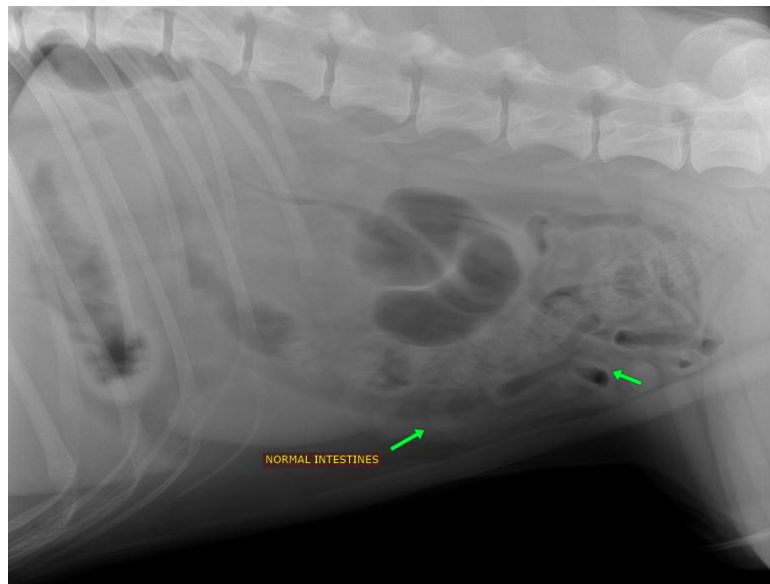
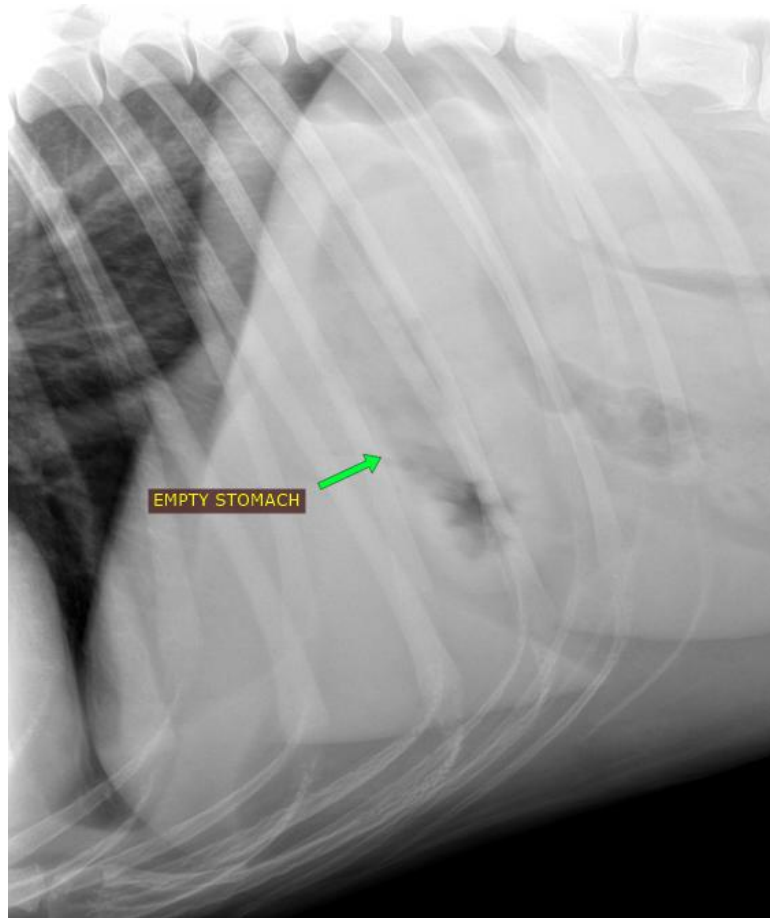
Kim Allyn, DVM

INVOICE

75561

DATE

6-17-26





PATIENT

Odin Austria

SPECIES

Canine

BREED

Shepherd Mix

SEX

Neutered

AGE

5Y

WEIGHT

76.6lbs

INTERPRETED BY

Dr. Leticia Utsch MV

IMAGING PERFORMED BY

Allison

HOSPITAL NAME

Elizabeth Animal
Hospital

REFERRING VET

Kim Allyn, DVM

INVOICE

75561

DATE

6-17-26

The information and recommendations provided are based on the images presented by the referring veterinarian. No evaluation can be communicated regarding pathology that was not visible in the image/video clips provided.

Thank you for this referral. If the clinical or image interpretation does not parallel your findings or if I can be of any further assistance please contact me.

Dr. Leticia Utsch MV

info@sonopath.com