



PATIENT

Saint Robinson

SPECIES

Feline

BREED

DSH

SEX

NM

AGE

6Y

WEIGHT

10lbs

INTERPRETED BY

Dr. Leticia Utsch MV

IMAGING PERFORMED BY

Mallory Frois

HOSPITAL NAME

The Pet Hospital of
Stratford

REFERRING VET

Dr. Claudia Giuliani

INVOICE

75142

DATE

5-26-26

PRESENTING CLINICAL SIGNS

P vomiting white/clear foam for the past couple of days and no appetite. O unsure if got into anything. No recent diet changes. Indoor only. No d/c/s.

Abnormal PE/Chem/CBC/UA Results: P fractious, limited exam. Fleas noted. mild tartar. bw/ua pending

RADIOGRAPHIC STUDY OF THE ABDOMEN

Radiographs of the abdomen in three imaging planes are provided for review.

RADIOGRAPHIC FINDINGS

The stomach is moderately filled with fluid and gas.

The colon is normally filled with gas and fecal material.

The small intestines are normally filled with fluid and gas.

Liver, kidney and spleen have a normal size and shape.

The peritoneal and retroperitoneal detail are normal appearing.

The urinary bladder has a normal opacity. No stones seen.

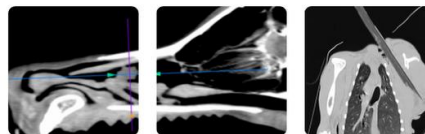
Mild degenerative joint disease seen in both hips.

RADIOGRAPHIC DIAGNOSIS

- Moderately fluid and gas filled stomach, consistent with reported vomiting.

INTERPRETATION OF FINDINGS & FURTHER RECOMMENDATIONS

Mild fluid and gas distension of the stomach likely reflect mild gastritis. No radiopaque foreign body or radiographic evidence of gastrointestinal obstruction is identified; however, non-radiopaque foreign material cannot be completely excluded. Gastrointestinal disease remains a primary consideration, including gastritis, and chronic enteropathy. Correlation with pending laboratory results and symptomatic therapy are recommended. Abdominal ultrasound may be warranted if vomiting, anorexia, or other clinical signs persist or worsen.



PATIENT

Saint Robinson

SPECIES

Feline

BREED

DSH

SEX

NM

AGE

6Y

WEIGHT

10lbs

INTERPRETED BY

Dr. Leticia Utsch MV

IMAGING PERFORMED BY

Mallory Frois

HOSPITAL NAME

The Pet Hospital of
Stratford

REFERRING VET

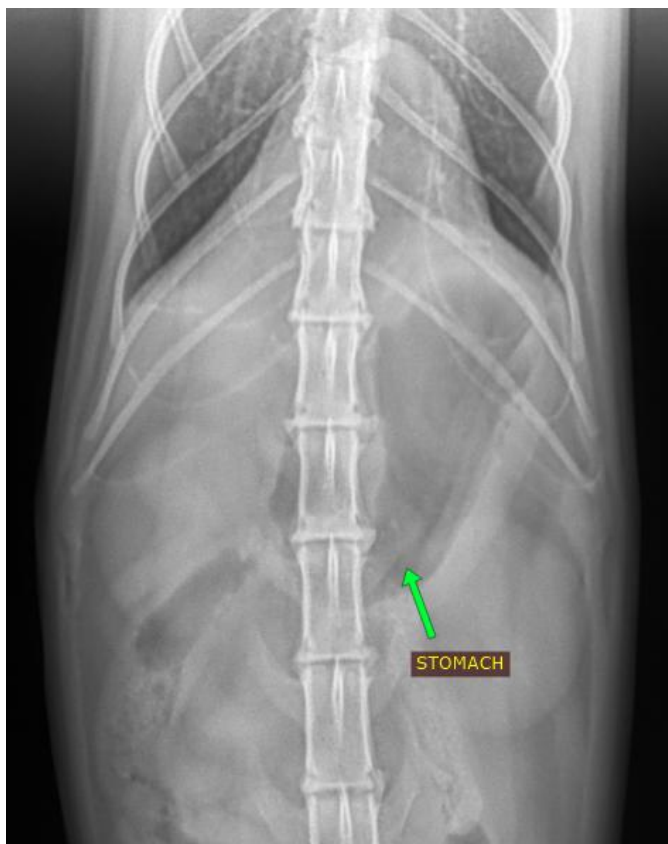
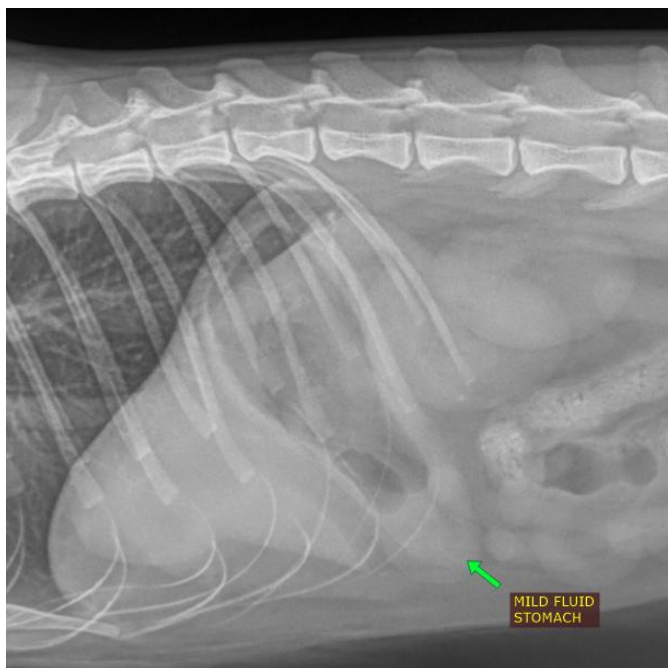
Dr. Claudia Giuliani

INVOICE

75142

DATE

5-26-26





PATIENT

Saint Robinson

SPECIES

Feline

BREED

DSH

SEX

NM

AGE

6Y

WEIGHT

10lbs

INTERPRETED BY

Dr. Leticia Utsch MV

IMAGING PERFORMED BY

Mallory Frois

HOSPITAL NAME

The Pet Hospital of
Stratford

REFERRING VET

Dr. Claudia Giuliani

INVOICE

75142

DATE

5-26-26

The information and recommendations provided are based on the images presented by the referring veterinarian. No evaluation can be communicated regarding pathology that was not visible in the image/video clips provided.

Thank you for this referral. If the clinical or image interpretation does not parallel your findings or if I can be of any further assistance please contact me.

Dr. Leticia Utsch MV

info@sonopath.com