



PATIENT

Monkey Trupoiu

SPECIES

Canine

BREED

Shih Tzu

SEX

Male Neutered

AGE

7Y

WEIGHT

24lbs

INTERPRETED BY

Dr. Leticia Utsch MV

IMAGING PERFORMED BY

Darius

HOSPITAL NAME

Animal Clinic of
Queens

REFERRING VET

Dr. Mandanini

INVOICE

75141

DATE

5-26-26

PRESENTING CLINICAL SIGNS

Pt has had bloody diarrhea since Sunday. Received vaccines on Saturday. Pt is still eating and has good energy.

RADIOGRAPHIC STUDY OF THE THORAX AND ABDOMEN

Radiographs of the thorax and abdomen in three imaging planes are provided for review.

RADIOGRAPHIC FINDINGS

Thorax

The lungs are normally insufflated and transparent.

The heart and pulmonary vasculature appear normal.

The trachea and principal bronchi have a normal diameter.

The mediastinum and pleural space also appear normal.

Bone structures do not show any significant changes.

Abdomen

The stomach is moderately filled with fluid and gas.

The colon is mildly filled with fluid and gas.

The small intestines are normally filled with fluid and gas.

Liver, kidney and spleen have a normal size and shape.

The peritoneal and retroperitoneal detail are normal appearing.

The urinary bladder has a normal opacity. No stones seen.

Bone structures are normal.

RADIOGRAPHIC DIAGNOSIS

- Fluid-filled stomach may indicate gastritis;
- Colonic appearance likely related to diarrhea, colitis;
- The thorax appears normal.

INTERPRETATION OF FINDINGS & FURTHER RECOMMENDATIONS

Radiographic findings are most consistent with colitis/gastroenteritis. Given the clinical history, transient inflammatory gastrointestinal disease is a possibility, although dietary indiscretion or infectious enteritis cannot be excluded. No radiographic evidence of gastrointestinal foreign body or obstruction is identified. Supportive care, including dietary management, hydration support, probiotics, and symptomatic therapy may be beneficial as clinically indicated. Correlation with fecal testing and clinical progression is recommended if hematochezia persists or worsens.



PATIENT

Monkey Trupoiu

SPECIES

Canine

BREED

Shih Tzu

SEX

Male Neutered

AGE

7Y

WEIGHT

24lbs

INTERPRETED BY

Dr. Leticia Utsch MV

IMAGING PERFORMED BY

Darius

HOSPITAL NAME

Animal Clinic of
Queens

REFERRING VET

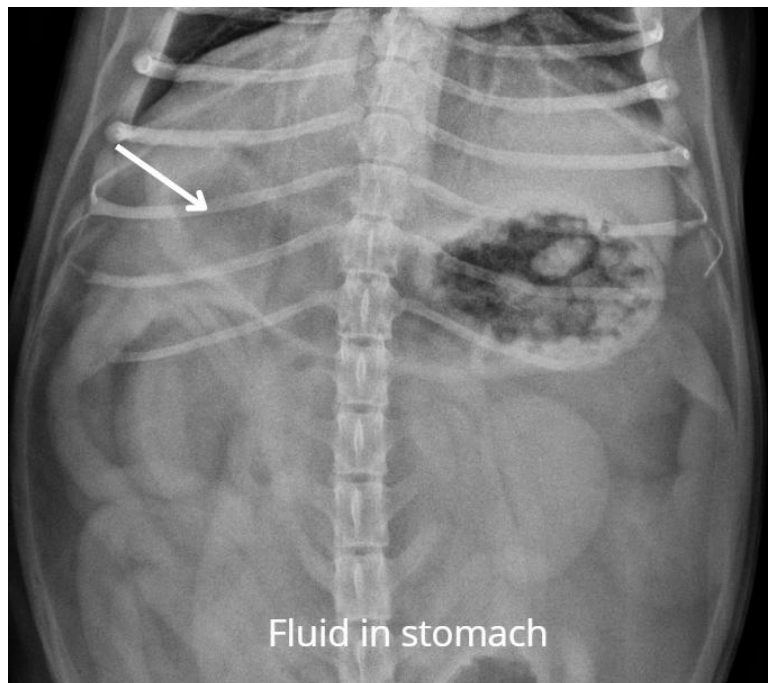
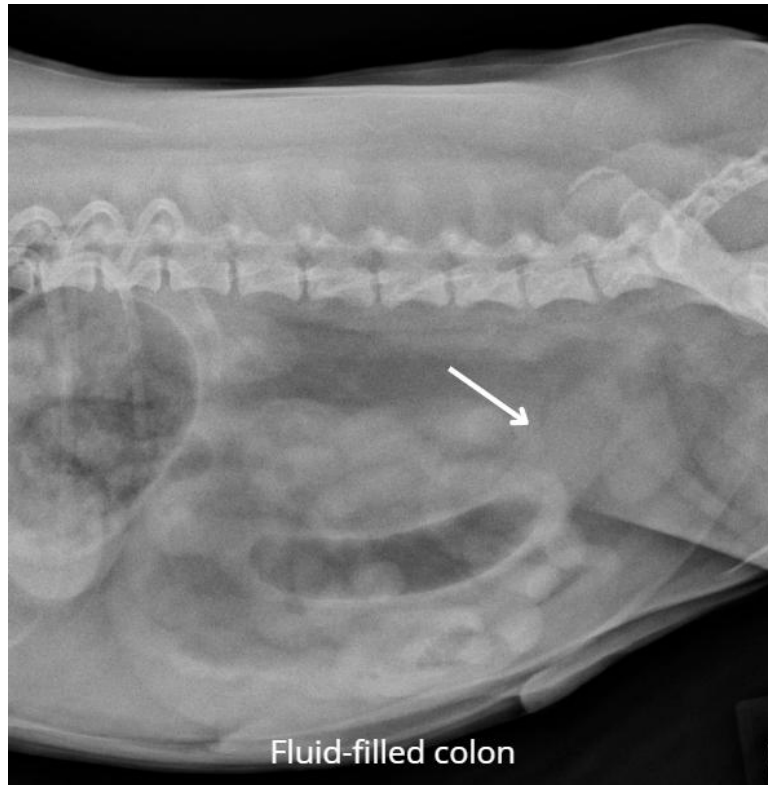
Dr. Mandanini

INVOICE

75141

DATE

5-26-26





PATIENT

Monkey Trupoiu

SPECIES

Canine

BREED

Shih Tzu

SEX

Male Neutered

AGE

7Y

WEIGHT

24lbs

INTERPRETED BY

Dr. Leticia Utsch MV

IMAGING PERFORMED BY

Darius

HOSPITAL NAME

Animal Clinic of
Queens

REFERRING VET

Dr. Mandanini

INVOICE

75141

DATE

5-26-26

The information and recommendations provided are based on the images presented by the referring veterinarian. No evaluation can be communicated regarding pathology that was not visible in the image/video clips provided.

Thank you for this referral. If the clinical or image interpretation does not parallel your findings or if I can be of any further assistance please contact me.

Dr. Leticia Utsch MV

info@sonopath.com